HEAD, NECK & DENTAL ANATOMY

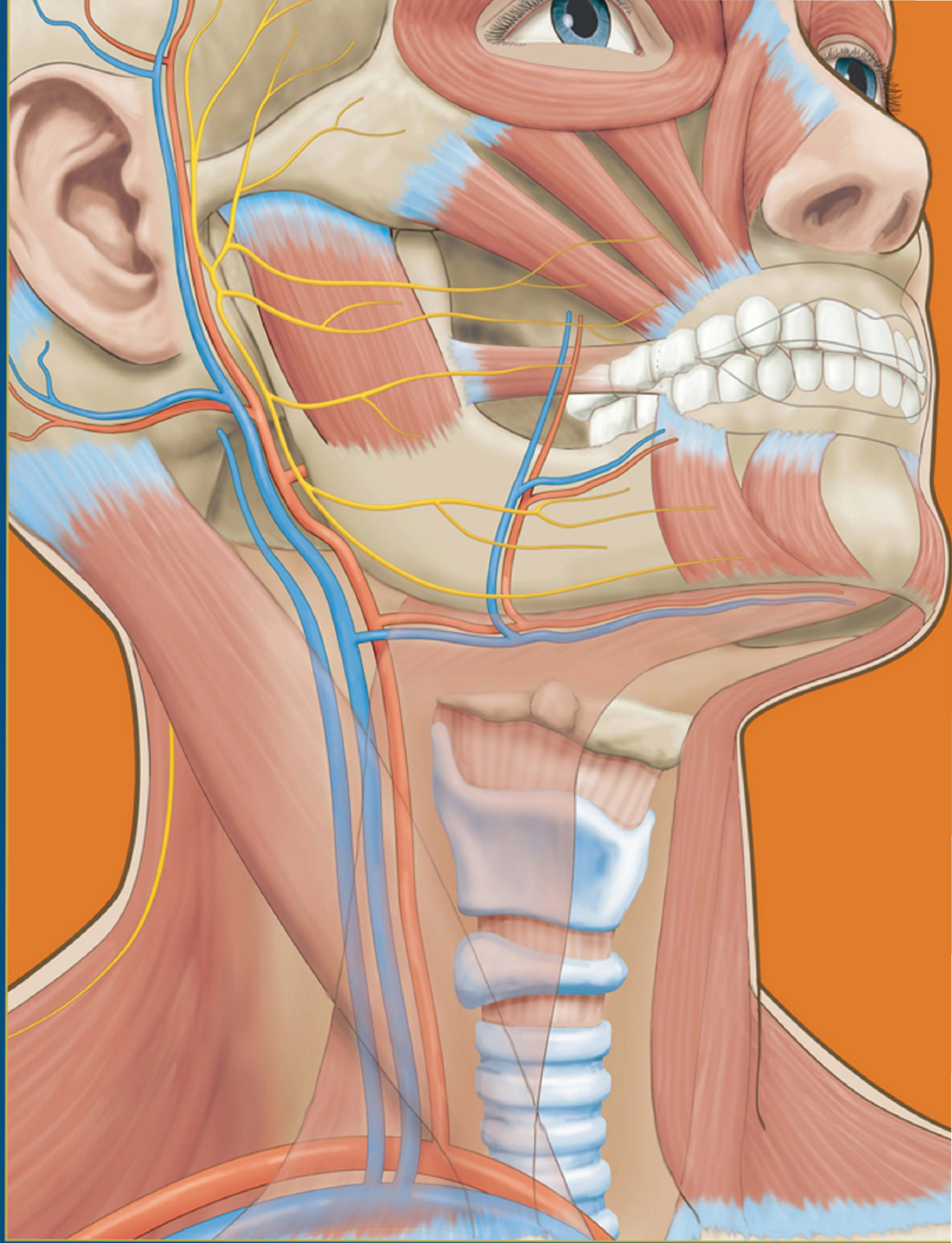

FOURTH EDITION

MARJORIE J. SHORT • DEBORAH LEVIN-GOLDSTEIN

HEAD, NECK & DENTAL ANATOMY

HEAD, NECK & DENTAL ANATOMY

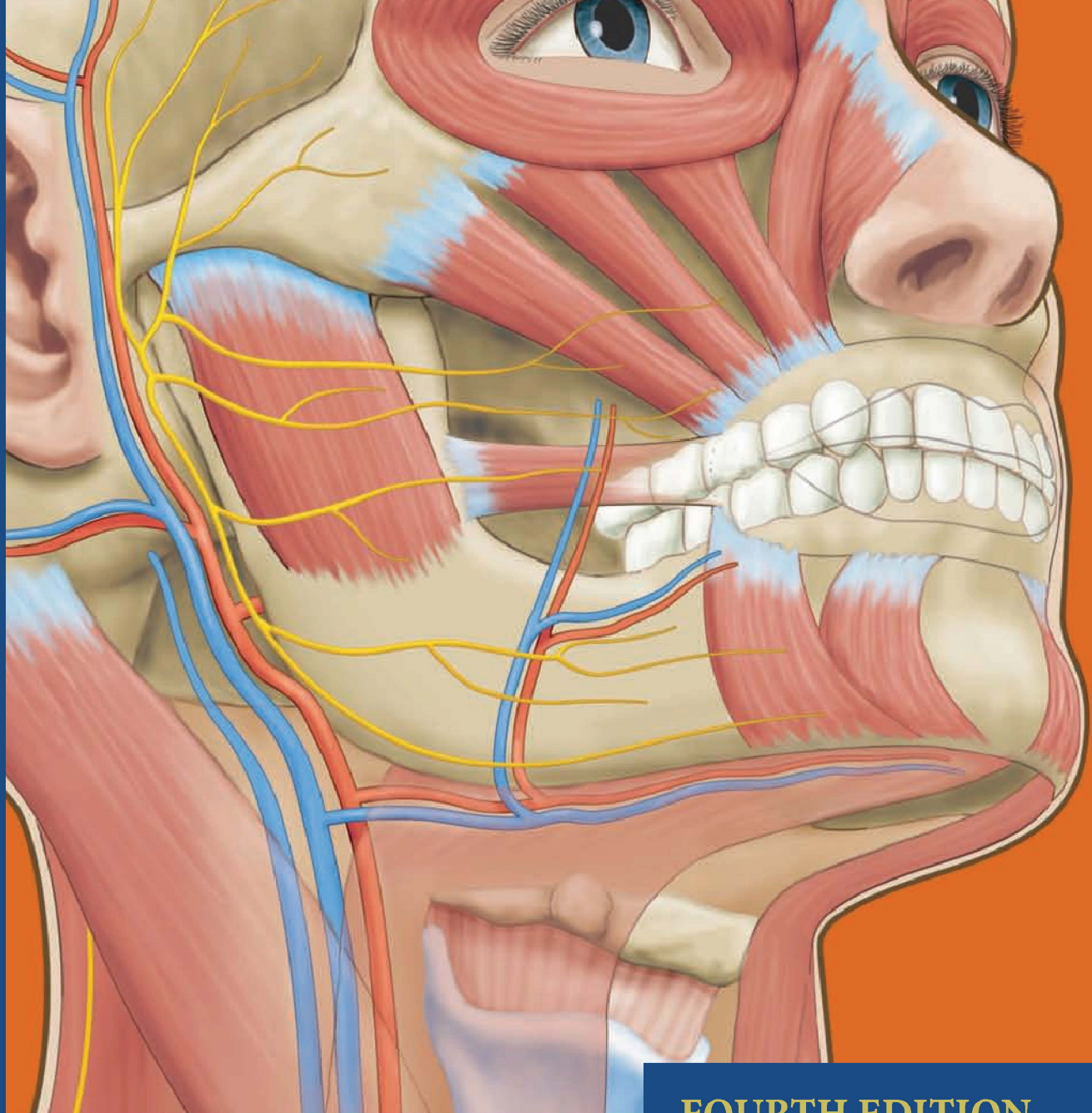

FOURTH EDITION

Marjorie J. Short
Formerly of Middlesex Community College

Deborah Levin-Goldstein
Northampton Community College

DELMAR
CENGAGE Learning

Australia • Brazil • Japan • Korea • Mexico • Singapore • Spain • United Kingdom • United States

This is an electronic version of the print textbook. Due to electronic rights restrictions, some third party content may be suppressed. Editorial review has deemed that any suppressed content does not materially affect the overall learning experience. The publisher reserves the right to remove content from this title at any time if subsequent rights restrictions require it. For valuable information on pricing, previous editions, changes to current editions, and alternate formats, please visit www.cengage.com/highered to search by ISBN#, author, title, or keyword for materials in your areas of interest.

DELMAR
CENGAGE Learning

Head, Neck and Dental Anatomy
Marjorie Short
Deborah Levin-Goldstein

Vice President, Careers & Computing: Dave Garza

Director of Learning Solutions: Matthew Kane

Senior Acquisitions Editor: Tari Broderick

Director, Development - Careers & Computing: Marah Bellegarde

Associate Product Manager: Meghan E. Orvis

Editorial Assistant: Nicole Manikas

Vice President, Marketing: Jennifer Baker

Brand Manager: Wendy Mapstone

Market Development Manager: Jonathan Sheehan

Senior Production Director: Wendy A. Troeger

Production Manager: Andrew Crouth

Content Project Manager: Thomas Heffernan

Senior Art Director: Jack Pendleton

Cover Image: © Cengage Learning

© 2013, 2002, 1994, 1990 Delmar, Cengage Learning

ALL RIGHTS RESERVED. No part of this work covered by the copyright herein may be reproduced, transmitted, stored, or used in any form or by any means graphic, electronic, or mechanical, including but not limited to photocopying, recording, scanning, digitizing, taping, Web distribution, information networks, or information storage and retrieval systems, except as permitted under Section 107 or 108 of the 1976 United States Copyright Act, without the prior written permission of the publisher.

For product information and technology assistance, contact us at
Cengage Learning Customer & Sales Support, 1-800-354-9706

For permission to use material from this text or product, submit all requests online at **www. cengage.com/permissions.** Further permissions questions can be e-mailed to **permissionrequest@cengage.com**

Library of Congress Control Number: 2012944926

ISBN-13: 978-1-1113-0678-6

ISBN-10: 1-1113-0678-8

Delmar
5 Maxwell Drive Clifton Park,
NY 12065-2919
USA

Cengage Learning is a leading provider of customized learning solutions with office locations around the globe, including Singapore, the United Kingdom, Australia, Mexico, Brazil, and Japan. Locate your local office at: **international.cengage.com/region**

Cengage Learning products are represented in Canada by Nelson Education, Ltd.

To learn more about Delmar, visit **www.cengage.com/delmar**

Purchase any of our products at your local college store or at our preferred online store **www.cengagebrain.com**

Notice to the Reader
Publisher does not warrant or guarantee any of the products described herein or perform any independent analysis in connection with any of the product information contained herein. Publisher does not assume, and expressly disclaims, any obligation to obtain and include information other than that provided to it by the manufacturer. The reader is expressly warned to consider and adopt all safety precautions that might be indicated by the activities described herein and to avoid all potential hazards. By following the instructions contained herein, the reader willingly assumes all risks in connection with such instructions. The publisher makes no representations or warranties of any kind, including but not limited to, the warranties of fitness for particular purpose or merchantability, nor are any such representations implied with respect to the material set forth herein, and the publisher takes no responsibility with respect to such material. The publisher shall not be liable for any special, consequential, or exemplary damages resulting, in whole or part, from the readers' use of, or reliance upon, this material.

Printed in the United States of America
1 2 3 4 5 6 7 16 15 14 13 12

Table of Contents

Preface xviii
About the Authors xxii
Acknowledgments xxiii

SECTION I: Introduction to the Oral Cavity 1

Chapter 1: Nomenclature 2

The Dentition 3
Primary or Deciduous Dentition 3
Permanent Dentition 3
Names and Functions of the Teeth 5
Primary or Deciduous Teeth 5
Types of Teeth 5
Permanent Teeth 5
Types of Teeth 5
The Arrangement of the Teeth 6
Tooth Description 6
The Eruption Sequence 6
Summary 9
Worksheet 10

Chapter 2: Structures of the Oral Cavity 12

Related Terminology 13
The Oral Cavity 14
Divisions 15
Functions 15
Structures External to the Oral Cavity 15
Structures of the Oral Vestibule 16
Structures of the Oral Cavity Proper 18
Roof of the Mouth 18
Fauces 18
Tongue 20
Summary 22
Worksheet 23

Copyright 2012 Cengage Learning. All Rights Reserved. May not be copied, scanned, or duplicated, in whole or in part. Due to electronic rights, some third party content may be suppressed from the eBook and/or eChapter(s). Editorial review has deemed that any suppressed content does not materially affect the overall learning experience. Cengage Learning reserves the right to remove additional content at any time if subsequent rights restrictions require it.

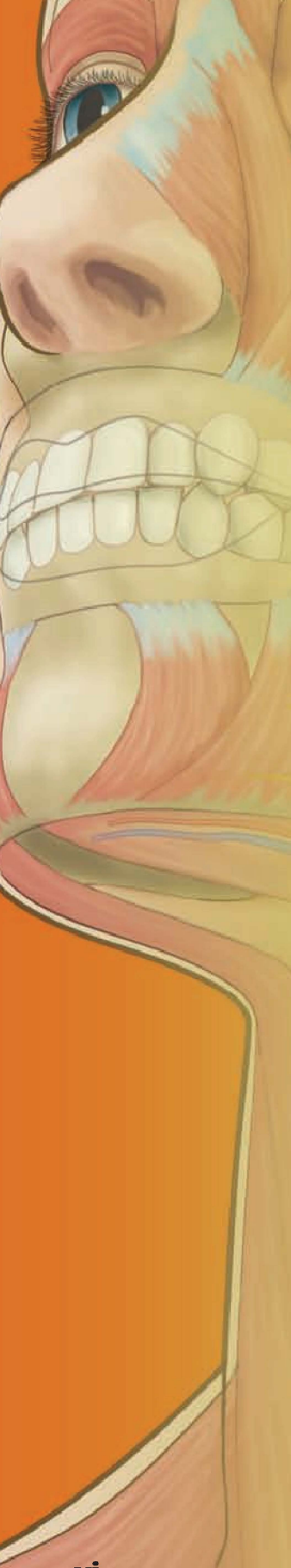

Chapter 3: The Tooth and Its Surrounding Structures 26

Divisions of the Tooth 27
Surfaces of the Tooth 28
Tissues of the Tooth 31
Enamel *31*
Cementum *31*
Dentin *33*
Pulp *33*
The Periodontium 34
Cementum *35*
Periodontal Ligament *35*
Alveolar Process *35*
Gingiva *35*
Free Gingiva 36
Attached Gingiva 37
Gingival Description 38
Summary 38
Worksheet 39

Chapter 4: Tooth Identification Systems 42

The Universal Tooth Identification System 43
Permanent Teeth *43*
Primary Teeth *44*
Palmer's Notation 44
Federation Dentaire Internationale (Fdi)/ International Standards Organization (Iso) 46
Summary 47
Worksheet 48

SECTION II: Permanent Anterior Teeth 51

General Information 51
Apical Foramen 54
Structures Common to All Anterior Teeth 55

Copyright 2012 Cengage Learning. All Rights Reserved. May not be copied, scanned, or duplicated, in whole or in part. Due to electronic rights, some third party content may be suppressed from the eBook and/or eChapter(s). Editorial review has deemed that any suppressed content does not materially affect the overall learning experience. Cengage Learning reserves the right to remove additional content at any time if subsequent rights restrictions require it.

Chapter 5: Maxillary Incisors 56

General Information 57
Maxillary Central Incisor Description 57
Labial Surface *58*
Lingual Surface *58*
Proximal Surfaces *60*
Summary of the Maxillary Central Incisor *60*
Labial Surface 60
Lingual Surface 60
Proximal Surfaces 61
Maxillary Lateral Incisor Description 61
Labial Surface *63*
Lingual Surface *63*
Proximal Surfaces *63*
Summary of the Maxillary Lateral Incisor *64*
Labial Surface 64
Lingual Surface 64
Proximal Surfaces 64
Summary 64
Worksheet 65

Chapter 6: Mandibular Incisors 67

General Information 68
Mandibular Central Incisor Description 68
Labial Surface *69*
Lingual Surface *69*
Proximal Surfaces *71*
Incisal View *71*
Summary of the Mandibular Central Incisor *72*
Labial Surface 72
Lingual Surface 72
Proximal Surfaces 72
Incisal View 72
Mandibular Lateral Incisor Description 72
Labial Surface *73*
Lingual and Proximal Surfaces *73*
Incisal View *75*

Copyright 2012 Cengage Learning. All Rights Reserved. May not be copied, scanned, or duplicated, in whole or in part. Due to electronic rights, some third party content may be suppressed from the eBook and/or eChapter(s). Editorial review has deemed that any suppressed content does not materially affect the overall learning experience. Cengage Learning reserves the right to remove additional content at any time if subsequent rights restrictions require it.



Summary of the Mandibular Lateral Incisor 75
Labial Surface 75
Lingual Surface 75
Proximal Surfaces 76
Incisal View 76
Summary 76
Worksheet 77

Chapter 7: Canines 79

General Information 80
Maxillary Canine Description 81
Labial Surface 83
Lingual Surface 83
Proximal Surfaces 83
Summary of the Maxillary Canine 84
Labial Surface 84
Lingual Surface 84
Proximal Surfaces 84
Mandibular Canine Description 85
Labial Surface 87
Lingual Surface 87
Proximal Surfaces 87
Summary of the Mandibular Canine 87
Labial Surface 87
Lingual Surface 88
Proximal Surfaces 88
Summary 88
Worksheet 89

SECTION III: Permanent Posterior Teeth 91

General Information 91
Occlusal Surface 92
Lobes 92
Pulp Canals 92
Pulp Horn 93
Root Trunk 93
Contact Area 93
Succedaneous Tooth 93

Structures Common to All Posterior Teeth 94
Ridge 94
Fossa 94
Groove 95
Pit 95
Facts to Help Avoid Confusion 95
Premolars 95
Nomenclature 95
Size and Shape of Surfaces 96
Occlusal Surface 96

Chapter 8: Maxillary Premolars 97

General Information 98
Maxillary First Premolar Description 98
Buccal Surface 99
Lingual Surface 101
Proximal Surfaces 101
Mesial Surface 101
Distal Surface 101
Occlusal Surface 102
Summary of the Maxillary First Premolar 102
Buccal Surface 102
Lingual Surface 103
Proximal Surfaces 103
Occlusal Surface 103
Maxillary Second Premolar Description 104
Summary 106
Worksheet 107

Chapter 9: Mandibular Premolars 109

General Information 110
Mandibular First Premolar Description 110
Buccal Surface 112
Lingual Surface 112
Mesial Surface 112
Distal Surface 112
Occlusal View 112
Summary of the Mandibular First Premolar 113
Buccal Surface 113

Lingual Surface 114
Mesial and Distal Surfaces 114
Occlusal Surface 114
Mandibular Second Premolar
Description 115
Buccal Surface *117*
Lingual Surface *117*
Mesial Surface *117*
Distal Surface *117*
Occlusal Surface *117*
Summary of the Mandibular Second Premolar *118*
Buccal Surface 118
Lingual Surface 118
Mesial and Distal Surfaces 119
Occlusal Surface 119
Summary 119
Worksheet 120

Chapter 10: Maxillary First and Second Molars 122

General Information 123
Maxillary First Molar Description 123
Buccal Surface *124*
Lingual Surface *126*
Mesial Surface *126*
Distal Surface *126*
Occlusal Surface *127*
Summary of the Maxillary First Molar *128*
Buccal Surface 128
Lingual Surface 129
Mesial Surface 129
Distal Surface 130
Occlusal Surface 130
Maxillary Second Molar Description 130
Occlusal Surface *133*
Summary 134
Worksheet 135

Chapter 11: Mandibular First and Second Molars 138

General Information 139
Mandibular First Molar Description 139
Buccal Surface *140*
Lingual Surface *142*
Mesial Surface *142*
Distal Surface *142*
Occlusal Surface 142
Summary of the Mandibular First Molar *144*
Buccal Surface 144
Lingual Surface 144
Mesial Surface 144
Distal Surface 145
Occlusal Surface 145
Mandibular Second Molar Description 145
Summary 149
Worksheet 150

Chapter 12: Third Molars 152

General Information 153
Maxillary Third Molar Description 153
Mandibular Third Molar Description 154
Summary 158
Worksheet 159

SECTION IV: Related Topics 161

Chapter 13: Primary Dentition 162

The Names and Number of the Primary Teeth 163
Eruption/Exfoliation 164
Comparison with Permanent Teeth 164
Description of Primary Teeth 165
Maxillary Incisors *165*
Maxillary Canine *166*
Maxillary First Molar *166*

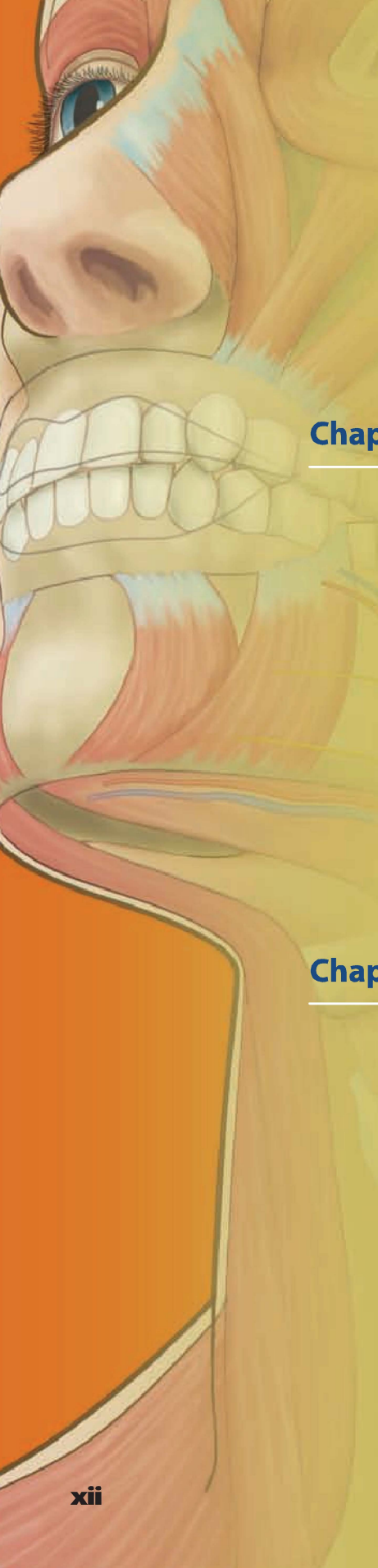

Maxillary Second Molar 166
Mandibular Incisors 166
Mandibular Canines 167
Mandibular First Molar 167
Mandibular Second Molar 167
Importance of Primary Teeth 169
Summary 169
Worksheet 170

Chapter 14: Tooth Development 172

General Information 173
Growth and Development 173
Initiation—Bud Stage 174
Proliferation—Cap Stage 174
Morphodifferentiation/Histodifferentiation—Bell Stage 174
Apposition—Maturation State 175
Eruption 176
Active Eruption 176
Passive Eruption 177
Developmental Anomalies 177
Summary 177
Worksheet 178

Chapter 15: Occlusion 180

General Information 181
Ideal Occlusion 182
Normal Occlusion 183
Malocclusion 183
Occlusal Deviations 184
Angle's Classification of Occlusion 187
Class I—Neutrocclusion (Normal) 187
Class II—Distocclusion 188
Division I 188
Division II 188
Class III—Mesiocclusion 188
Related Terms 189
Primary Teeth Occlusion 190

Summary 191
Worksheet 192

Chapter 16: Form and Function 194

General Information 195
Proximal Contact Areas 195
Function of Contact Areas 196
Interproximal Spaces 196
Function of the Interproximal Space 197
Embrasures 197
Function of the Embrasures 198
Compensating Curvatures 198
Summary 199
Worksheet 200

SECTION V: Head and Neck Anatomy 203

Chapter 17: Osteology of the Skull 204

Neurocranium 206
Occipital Bone 206
Frontal Bone 206
Bones of the Orbit 209
Parietal Bones 210
Temporal Bones 210
Ethmoid Bone 211
Sphenoid Bone 212
Viscerocranium 213
Zygomatic Bones (Cheek Bones) 213
Vomer 213
Nasal Bones 214
Lacrimal Bones 214
Inferior Nasal Concha 214
Palatine Bones 214
Maxilla 214
Mandible 216
Hyoid Bone 217
Summary 218
Worksheet 219

Chapter 18: Muscles of the Head and Neck 223

General Information 224
Muscles of Mastication 225
Temporalis 225
Masseter 226
Medial Pterygoid 227
Lateral Pterygoid 227
Suprahyoid Muscles 228
Digastric 228
Mylohyoid 228
Geniohyoid 230
Stylohyoid 230
Infrahyoid Muscles 230
Omohyoid 231
Sternohyoid 231
Sternothyroid 231
Thyrohyoid 232
Muscles of the Tongue 232
Intrinsic Muscles 232
Superior Longitudinal 232
Inferior Longitudinal 232
Transverse 232
Vertical 232
Extrinsic Muscles 232
Genioglossus 232
Hyoglossus 233
Styloglossus 233
Muscles of Facial Expression 233
Muscles of the Scalp 233
Muscles of the Ears 234
Orbicularis Oculi 234
Procerus 234
Corrugator 234
Muscles of the Nose 235
Muscles of the Mouth 235
Orbicularis Oris 235
Levator Labii Superioris Alaeque Nasi 235
Levator Labii Superioris or Quadratus Labii Superioris 236

Zygomatic 237
Levator Anguli Oris or Caninus 237
Buccinator 237
Risorius 238
Depressor Anguli Oris or Triangularis 238
Depressor Labii Inferioris or Quadratus Labii Inferioris 238
Mentalis 238
Muscles of the Neck 238
Platysma 238
Trapezius 238
Sternocleidomastoid 240
Muscles of the Soft Palate 240
Palatoglossal or Palatoglossus 240
Palatopharyngeal or Palatopharyngeus 240
Uvula 240
Levator Veli Palatini 240
Tensor Veli Palatini 241
Muscles of the Pharynx 242
Superior Constrictor 242
Middle Constrictor 242
Inferior Constrictor 242
Palatopharyngeal 242
Elevators and Dilators of the Pharynx 242
Salpingopharyngeal 242
Stylopharyngeal 242
Deglutition 243
Oral Stage 243
Pharyngeal Stage 243
Esophageal Stage 243
Summary 243
Worksheet 245

Chapter 19: Nerves of the Head and Neck 248

General Information 249
The Cranial Nerves 251
The Trigeminal Nerve (V) (Mixed) 251
The Ophthalmic Nerve (V_1) 253

The Maxillary Nerve (V_2) 253
The Zygomatic Nerve 254
The Infraorbital Nerve 254
Posterior Superior Alveolar (PSA) Nerve 255
Pterygopalatine Nerves 255
The Mandibular Nerve (V_3) 257
The Anterior Division 257
The Posterior Division 258
Inferior Alveolar Nerve 259
The Facial Nerve (VII) 261
The Glossopharyngeal Nerve (IX) 263
The Hypoglossal Nerve (XII) 263
Summary 264
Worksheet 265

Chapter 20: Arteries of the Head and Neck 267

General Information 268
Internal Carotid Artery 269
External Carotid Artery 269
Mandibular Section 272
Pterygoid Section 274
Pterygopalatine Section 274
Veins of the Face 275
Superficial Veins 276
Deep Veins 277
Summary 278
Worksheet 279

Chapter 21: Salivary Glands 281

General Information 282
Major Salivary Glands 282
Parotid Gland 282
Submandibular Gland 282
Sublingual Gland 283
Minor Salivary Glands 284

Labial Glands *284*
Buccal Glands *284*
Palatine Glands *284*
Lingual Glands *285*
Summary 285
Worksheet 286

Chapter 22: Temporomandibular Joint 288

Anatomy 289
Nerve and Blood Supply 291
Movement 291
Summary 293
Worksheet 294

Appendix A 297
Appendix B 300
Appendix C 302
Bibliography 303
Glossary 305
Index 315

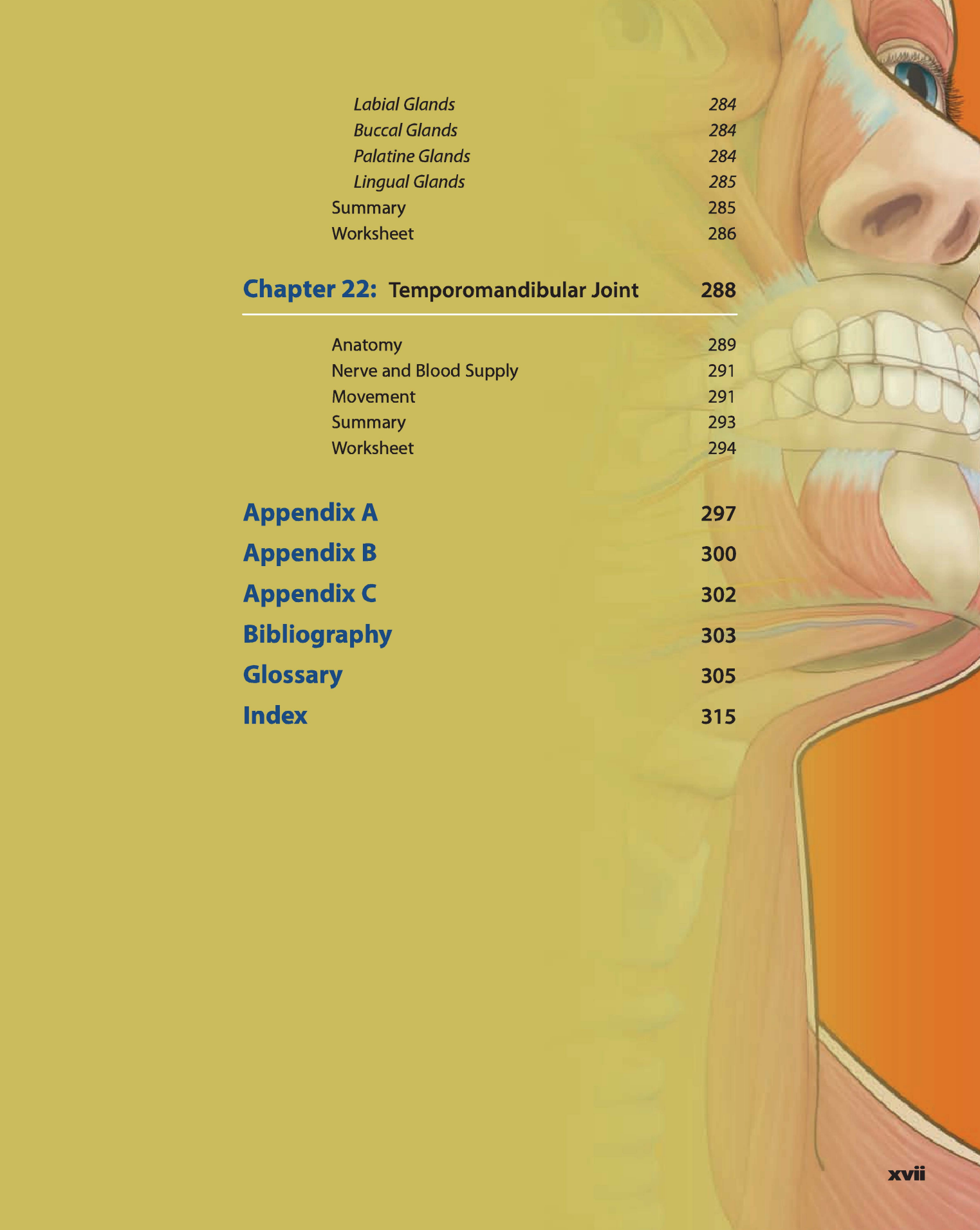

Preface

INTRODUCTION

Head, Neck, and Dental Anatomy, fourth edition is written for dental assisting students as an introduction to the study of anatomy of the teeth, head, and neck. A required course in the study of dental science, knowledge of and familiarity with the head, neck, and dental anatomy is of utmost importance to a successful and fulfilling career as a dental assistants and dental hygiene or hygienist. This textbook is an excellent teaching tool and reference manual for students and professionals.

With superb coverage of specific terminology, appropriate anatomical illustrations with anatomical descriptions of tooth, head and neck structures, and so much more, the fourth edition will be an invaluable textbook for classroom and professional study!

WHY WE WROTE THIS TEXT

This textbook was written and continually revised because of the commitment to students and their instructors; it is the most comprehensive and easy-to-understand textbook about the intricate details of head, neck, and dental anatomy. Success and future career fulfillment of dental professionals is the objective in revising this textbook including finding new and better ways to improve the content and its layout.

ORGANIZATION OF THE TEXT

Head, Neck, and Dental Anatomy is organized in the most advantageous progression for learning all aspects of anatomy for dental assistants and hygienists. The text is divided into five distinct sections.

Section I: Introduction to the Oral Cavity consists of four introductory chapters to teach students the foundations of anatomical terminology and the basics of dental structures. *Chapter 1: Nomenclature* covers the primary and permanent dentitions, their differences, arrangements, and functions. *Chapter 2: Structures of the Oral Cavity* discusses surrounding anatomy of the oral cavity beyond dentition, including the tongue and oral vestibule, among others, and their functions. *Chapter 3: The Tooth and Its Surrounding Structures* is a detailed introduction to the surfaces, tissues, and other structures in the oral cavity. Last in Section I is *Chapter 4: Tooth Identification Systems*, describes various numbering systems used to chart teeth in offices and dental practice, today.

Section II: Permanent Anterior Teeth provides a brief description of the anatomy and vocabulary used in the following chapters, including pulp canal, fossa, and root depressions or furrows. *Chapter 5: Maxillary Incisors, Chapter 6: Mandibular Incisors,* and *Chapter 7: Canines* are all organized in the same layout for ease of understanding the topics. Each chapter begins with a description of the tooth, including all its surfaces - labial, lingual, proximal surfaces, and incisal view, as well as additional details where necessary, and worksheets for students to review the material.

Section III: Permanent Posterior Teeth begins with an introduction to the specific structures, anatomical vocabulary, and detailed descriptions followed by specific chapters about the teeth. *Chapter 8: Maxillary Premolars, Chapter 9: Mandibular Premolars, Chapter 10: Maxillary First and Second Molars,* and *Chapter 11: Mandibular First and Second Molars* are organized similarly and in the same order for easy understanding. Each chapter begins with the description of the specific tooth and includes details about the buccal, lingual, mesial, distal, and occlusal surfaces, and additional details where applicable. *Chapter 12: Third Molars* is the last chapter in Section III. All chapters include worksheets and multiple choice questions to assure student understanding.

Section IV: Related Topics includes important chapters to assist in understanding development and occlusion of the permanent and primary dentitions,

essential areas of knowledge for any dental professional. *Chapter 13: Primary Dentition* is an in-depth coverage of the primary dentition and its differences from permanent teeth including descriptions of primary incisors, molars, and canines. *Chapter 14: Tooth Development* covers the growth and development of teeth including the stages from beginning of formation to eruption. *Chapter 15: Occlusion* discussess the different types of occlusion, including its classes and divisions. *Chapter 16: Form and Function* provides information about contact areas, embrasures, and interdental spaces.

Section V: Head and Neck Anatomy delves into the specific content areas that emphasize the importance of recognizing and applying knowledge of head and neck anatomy and how it impacts dental anatomy. The chapters in the section are: *Chapter 17: Osteology of the Skull; Chapter 18: Muscles of the Head and Neck; Chapter 19: Nerves of the Head and Neck; Chapter 20: Arteries of the Head and Neck; Chapter 21: Salivary Glands;* and *Chapter 22: Temporomandibular Joint.*

NEW TO THE FOURTH EDITION

The fourth edition design and art program has been tremendously revised and improved to enhance the learning experience. Anatomic illustrations and diagrams have been updated to full color and have been drawn to be as close as possible to actual human structures. A brand new text design presents the content and accompanying illustrations in a very effective and user friendly layout. Multiple-choice questions have been added to each chapter and all of the end-of-chapter worksheets have been updated, as well.

ANCILLARY PACKAGE

Instructor Companion Website to Accompany *Head, Neck, and Dental Anatomy, fourth edition*

ISBN 13: 978-1-1115-4-0319

Spend less time planning and more time teaching with Delmar Cengage Learning's Instructor Resources to Accompany *Head, Neck, and Dental Anatomy, fourth edition*. The Instructor Companion Website can be accessed

by going to www.cengage.com/login to create a unique user log-in. The password-protected Instructor Resources include the following:

INSTRUCTOR'S MANUAL

An electronic Instructor's Manual provides instructors with invaluable tools for preparing for class lectures and examinations. Following chapter by chapter, the instructor's manual reiterates objectives, provides a synthesized recap of each chapter's main points and goals, and houses the answers to each chapter's review questions.

COMPUTERIZED TEST BANK IN EXAMVIEW™

An electronic test bank makes and generates tests and **quizzes** in an instant. With a variety of question types, including short answer, multiple-choice, true or false, and matching exercises, creating challenging exams will be no barrier in your classroom. This test bank includes a rich bank of more than 300 questions that test students on retention and application of what they've learned in the course. Answers are provided for all questions so instructors can focus on teaching, not grading.

INSTRUCTOR POWERPOINT SLIDES

A comprehensive offering of more than 300 instructor support slides created in Microsoft® PowerPoint outlines concepts and objectives to assist instructors with lectures.

About the Authors

Marjorie Short is a retired professor and department chairwoman of the Dental Hygiene Program, Middlesex Community College, Lowell, Massachusetts. She was previously a professor of dental anatomy at SUNY Farmingdale, New York.

Deborah Levin-Goldstein is a professor of dental hygiene at Northampton Community College in Bethlehem, Pennsylvania. She has been a dental hygiene educator for 30 years.

Acknowledgements

We would like to thank the technical reviewers of the fourth edition who vastly improved the new edition with their precise knowledge and valuable feedback.

Ethel Campbell, RDH, MS
Clinical Associate Professor
Program Director of Dental Assisting
School of Dentistry
University of North Carolina
Chapel Hill, North Carolina

Karen Kulikowski, DMD
Allied Dental Education Professor
School of Health Related Professions
University of Medicine & Dentistry of New Jersey
Scotch Plains, New Jersey

Joanne M. Pacheco, RDH, MAOB
Academic Chair
Department of Dental Hygiene
Fresno City College
Fresno, California

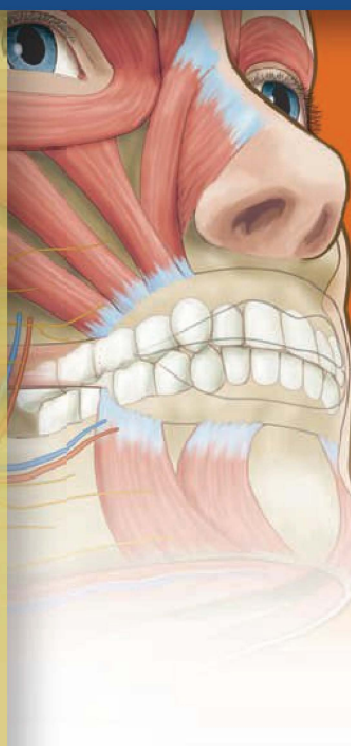

SECTION I

Introduction to the Oral Cavity

Chapter 1 Nomenclature

Chapter 2 Structures of the Oral Cavity

Chapter 3 The Tooth and Its Surrounding Structures

Chapter 4 Tooth Identification Systems

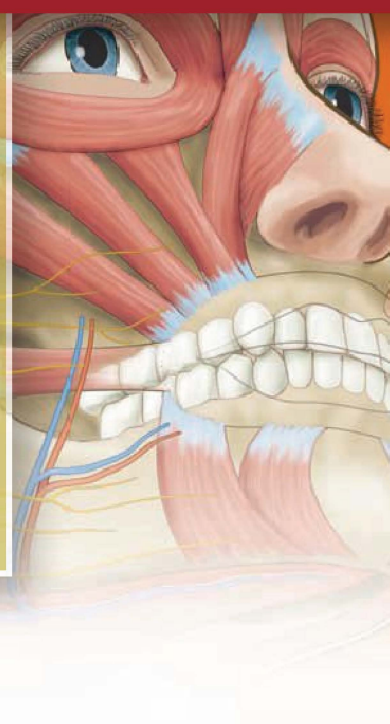

CHAPTER 1

Nomenclature

The Dentition

The Names and Functions of the Teeth

The Arrangement of the Teeth

The Eruption Sequence

Objectives

At the completion of this chapter, you will be able to:

- Identify, by name, the two dental arches, the permanent teeth, the deciduous teeth, and anterior and posterior teeth.
- Name the teeth in the order in which they are positioned in the dental arch, the function of each type of tooth, and the eruption sequence of deciduous and permanent teeth.
- Define the terms noted in boldface.
- Complete the worksheet at the end of the chapter.

Key Terms

Abrasion
Active eruption
Anterior
Attrition
Deciduous
Dentition
Diphyodont
Eruption
Exfoliate
Heterodont
Mastication
Mixed dentition

Continues

Key Terms *continued*

Passive eruption
Permanent
Polyphyodont
Posterior
Succedaneous

THE DENTITION

Teeth are arranged in the jaws to form two dental arches. Each arch is named to correspond with the bone from which it is composed. The maxilla forms the maxillary or upper arch; the mandible forms the mandibular or lower arch. Together, the two arches comprise one **dentition**, or set of teeth. During the life span, each person normally will have two dentitions, the **primary (deciduous)** and the **permanent**. (See **Figure 1–1**.)

Primary or Deciduous Dentition

The first or primary set of teeth, the deciduous dentition, begins to emerge into the mouth between 6 and 8 months of age. Teeth continue to erupt periodically, following a developmental schedule, until 20 teeth, 10 maxillary and 10 mandibular, have erupted by the age of 2½–3 years. These 20 deciduous teeth are small, but they fulfill the needs of a child. As the child grows, the deciduous teeth eventually **exfoliate**, or shed, and are replaced by permanent teeth. When all the permanent teeth have erupted, by the ages of 17 through 21, the permanent dentition is complete (**Figure 1–1A**).

Permanent Dentition

There are 32 permanent teeth, 16 maxillary and 16 mandibular. Until the child is 5 years old, only deciduous teeth are present in the mouth. Between 5 and 6 years of age, the first permanent tooth, the mandibular first molar, erupts posterior to the last deciduous molar. No deciduous tooth has exfoliated to provide space for the first permanent molar; however, the mandible has increased in length so that there is now space for an additional tooth. Permanent molars do not replace or succeed deciduous teeth (**Figure 1–1B**).

Shortly after the permanent first molars erupt, deciduous incisors, the front teeth, begin to exfoliate. This occurs as a result of a physiologic process that causes their roots to resorb as the permanent teeth form in the bone directly beneath them. Eventually, every deciduous tooth should exfoliate and be succeeded by a permanent tooth.

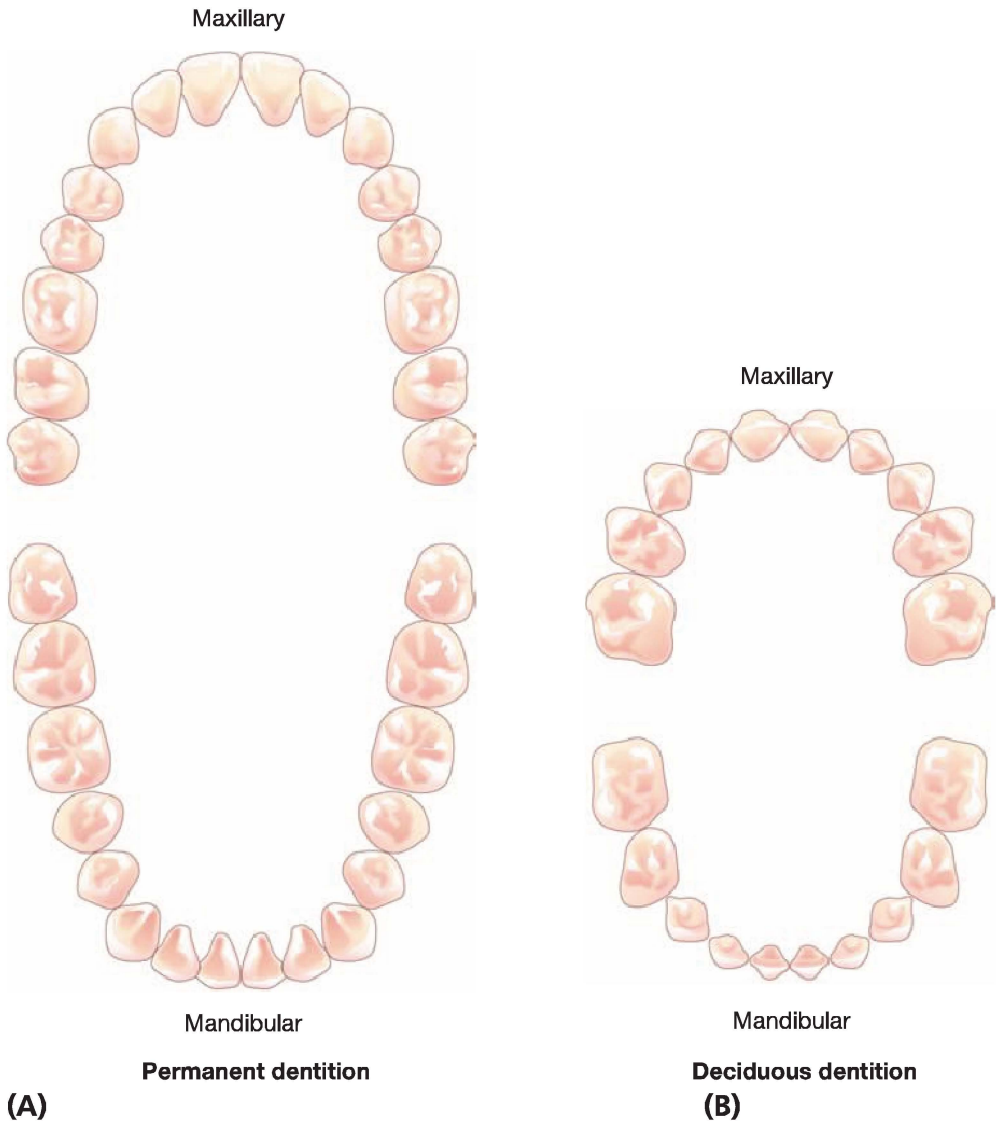

Figure 1–1. (A) Maxillary and mandibular dentition of an adult (permanent dentition). (B) Maxillary and mandibular dentition of a child (primary dentition).

Between the ages of 5 and 12, some deciduous and some permanent teeth are present in the mouth at the same time; this is referred to as a **mixed dentition**. Permanent teeth that replace or succeed deciduous teeth are called **succedaneous** teeth and include incisors, canines, and premolars. Permanent molars are not succedaneous teeth because they do not replace deciduous teeth.

Because human beings have two successive sets of teeth during their lives (a deciduous and a permanent dentition), they are considered **diphyodonts**. Having several sets of teeth throughout life, as certain reptiles do, would make the species **polyphyodonts**.

NAMES AND FUNCTIONS OF THE TEETH

Each dentition includes several types of teeth shaped to perform specific functions. People are **heterodonts** because they have different types of teeth called incisors, canines, premolars, and molars. The types of teeth in the maxillary arch are the same as those in the mandibular arch. When an imaginary midline is drawn to divide the arches into a right and left quadrant, the teeth in the right quadrant are the same as those in the left quadrant.

Primary or Deciduous Teeth

The deciduous dentition has 20 teeth—10 maxillary and 10 mandibular. They are smaller but similar in shape and function to the permanent teeth. They are described in the following section.

TYPES OF TEETH

	Number on each arch
Incisors—two central and two lateral	4 incisors
Canines—one in each corner of the arch	2 canines
Molars—two first molars, two second molars	4 molars
	10 total per arch

Each deciduous tooth is eventually replaced by a permanent tooth. Note, however, that there are no primary premolars. Primary molars are succeeded by permanent premolars. Permanent molars erupt posterior to the primary molars without replacing any primary molars. As mentioned, permanent molars are not succedaneous teeth (see **Figure 1–1**).

Permanent Teeth

The permanent dentition has 32 teeth—16 maxillary and 16 mandibular. See **Figure 1–1**.

TYPES OF TEETH

- *Incisors* are the four front teeth and have sharp biting edges for incising, or cutting, food. The two in the middle of the arch are central incisors; those on each side are lateral incisors.
- *Canines*, also called cuspids, are the corner teeth and have one pointed cusp used to hold and tear food.
- *Premolars*, also called bicuspids, are posterior teeth having two major cusps adapted to crush and tear food. Premolars are named by the sequence in the arch from front to back as "first premolar" and "second premolar."

Number on each arch
4 incisors
2 canines
4 premolars
6 molars
16 total per arch

- *Molars* are broad back teeth having several cusps adapted to chew, crush, and grind food. They, too, are named by their sequence from the front to the back of the arch as "first molar," "second molar," and "third molar." Each tooth performs its individual function in the process of **mastication**, or chewing. By working together, the teeth prepare food for swallowing and digestion.

THE ARRANGEMENT OF THE TEETH

Figure 1–1 shows the arrangement of the permanent teeth in the dental arches. The **anterior** teeth are those in the front of the mouth and include incisors and canines. **Posterior** teeth, those in the back of the mouth, include premolars and molars.

Tooth Description

To identify a tooth correctly, note that it is designated not only by its name and arch but also by the quadrant in which it is located. Each quadrant is specified according to the patient's right or left side. To completely identify a tooth, information is provided in the following sequence:

	DENTITION	ARCH	QUADRANT	TOOTH
Example	Permanent	Mandibular	Right	Central Incisor

THE ERUPTION SEQUENCE

Although teeth begin to form in utero, eruptions occur at approximately 6–8 months of age. **Eruption** dates vary from person to person by a few months, just as the individual growth rate varies. **Table 1–1** lists the eruption sequence for **primary teeth**. Note that mandibular teeth generally precede maxillary teeth in eruption.

By the age of 2½–3 years, all deciduous teeth have erupted; at about 6 years, the permanent teeth start to erupt. Refer to **Figure 1–2** for the growth pattern of the teeth. A chronology of this growth pattern is given in Appendix A.

The first molars are the first permanent teeth to emerge into the mouth. They erupt posterior to the deciduous second molar without replacing any deciduous teeth. The eruption sequence of the permanent dentition is shown in Table 1–2.

TABLE 1–1. Eruption and Exfoliation Dates for Primary Teeth

TOOTH	ERUPTION DATE	EXFOLIATION DATE	MAXILLARY ORDER
Central incisor	6–10 months	6–7 years	#1
Lateral incisor	9–12 months	7–8 years	#2
First molar	12–18 months	9–11 years	#3
Canine	16–22 months	10–12 years	#4
Second molar	24–32 months	10–12 years	#5

TOOTH	ERUPTION DATE	EXFOLIATION DATE	MANDIBULAR ORDER
Central incisor	6–10 months	6–7 years	#1
Lateral incisor	7–10 months	7–8 years	#2
Canine	16–22 months	9–12 years	#4
First molar	12–18 months	9–11 years	#3
Second molar	20–32 months	10–12 years	#5

© Cengage Learning 2013

TABLE 1–2. Eruption Dates for Permanent Teeth

TOOTH	ERUPTION DATE	ORDER OF ERUPTION (MAXILLARY)
Central incisor	7–8 years	#2
Lateral incisor	8–9 years	#3
Canine	11–12 years	#6
First premolar	10–11 years	#4
Second premolar	11–12 years	#5
First molar	6–7 years	#1
Second molar	12–13 years	#7
Third molar	17–21 years	#8

TOOTH	ERUPTION DATE	ORDER OF ERUPTION (MANDIBULAR)
Central incisor	6–7 years	#2
Lateral incisor	7–8 years	#3
Cuspid	9–10 years	#4
First premolar	10–11 years	#5
Second premolar	11–12 years	#6
First molar	6–7 years	#1
Second molar	11–13 years	#7
Third molar	17–21 years	#8

© Cengage Learning 2013

The initial eruption period, called **active eruption,** continues until the crown is almost completely exposed and the tooth is in its proper alignment. In later life, the "gums," or gingival line, may recede, exposing more of the tooth. This process is referred to as **passive eruption**.

Continual use of the teeth throughout life can cause a slight wearing away of the biting and/or chewing surfaces and, hence, a decrease in the height of the tooth. This wearing away is called **attrition**. Grinding of the teeth (bruxism) also causes attrition. **Abrasion** of the tooth surfaces can be caused by mechanical wear such as continual biting on an object or brushing too vigorously.

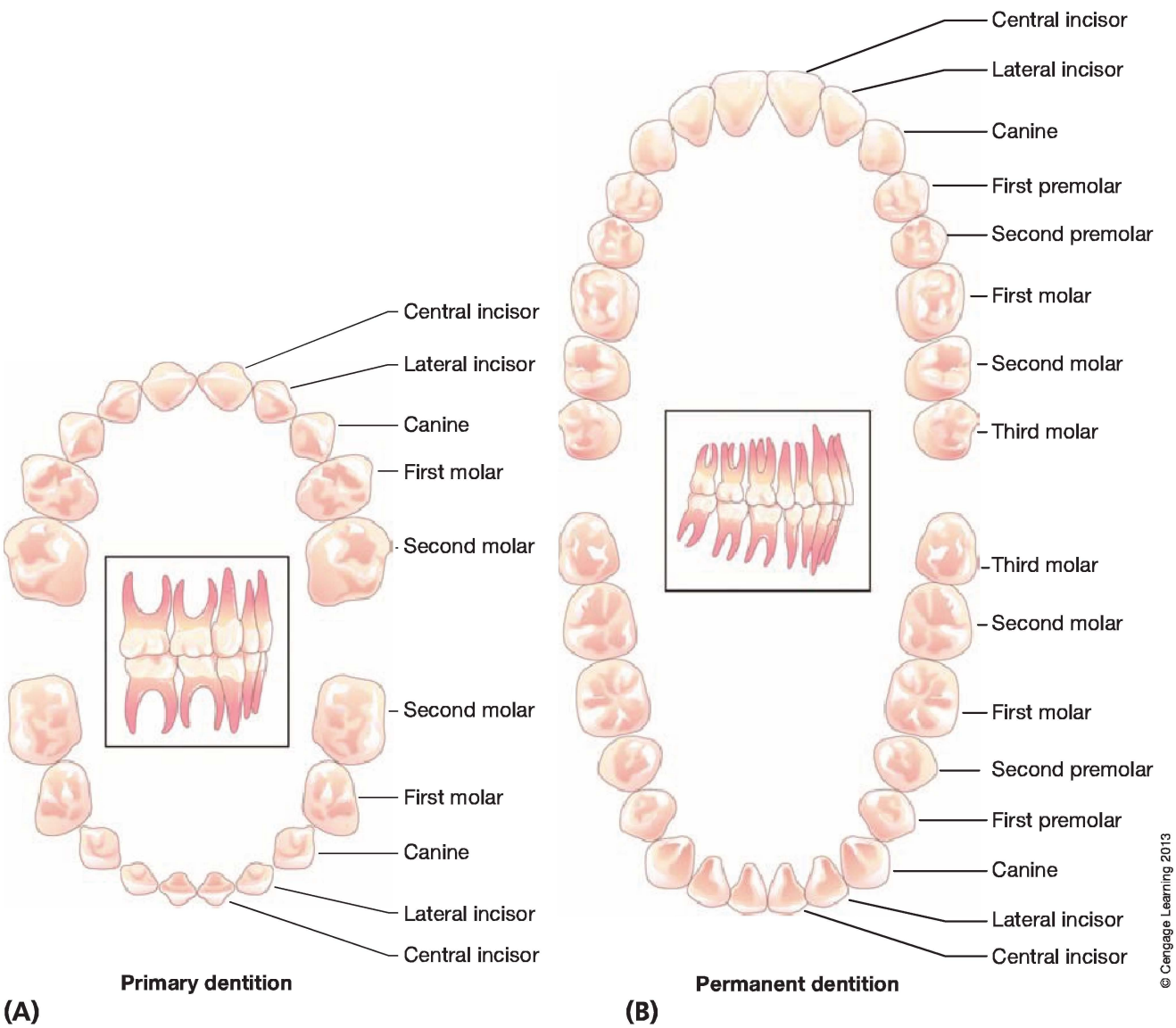

Figure 1–2. Development of the Human Dentition.

SUMMARY

During a person's life span there will be two sets of teeth. The first set, the primary or deciduous dentition, consists of 20 teeth. It eventually exfoliates and is replaced by the permanent dentition, which has 32 teeth.

Each dentition has several types of teeth shaped to perform specific functions; they work in conjunction with one another to prepare the food for digestion.

Deciduous teeth begin to emerge during the sixth month of infancy, but they are not completely erupted as a full dentition until the third year of life. Permanent teeth begin to emerge between 5 and 6 years of age, and all but the third molars have usually erupted by the twelfth year. Permanent teeth are expected to last a lifetime.

WORKSHEET

Define the following words.

Active eruption _____

Anterior _____

Attrition _____

Deciduous _____

Dentition _____

Diphyodont _____

Exfoliate _____

Heterodont _____

Mastication _____

Passive eruption _____

Polyphyodont _____

Posterior _____

Succedaneous _____

Name the deciduous/primary teeth in the order of eruption:

Answer the following multiple-choice questions

1. The total number of deciduous teeth is:

- **a.** 32
- **b.** 20
- **c.** 28
- **d.** 22

2. All deciduous teeth have erupted by age:

- **a.** 6 months–1 year
- **b.** 1–2 years
- **c.** 2 ½–3 years

3. The number of permanent anterior teeth in a quadrant is:

- **a.** 2
- **b.** 3
- **c.** 4
- **d.** 5

4. The fifth tooth from the midline in the permanent dentition is the:

a. first premolar

b. second premolar

c. first molar

d. second molar

5. The number of premolars in a deciduous dentition is:

a. 1

b. 2

c. 3

d. 0

CHAPTER 2

Structures of the Oral Cavity

Related Terminology

The Oral Cavity

Structures External to the Oral Cavity

Structures of the Oral Vestibule

Structures of the Oral Cavity Proper

Objectives

At the completion of this chapter, you will be able to:

- Identify two areas of the oral cavity—the boundaries of the oral vestibule and the boundaries of the oral cavity proper.
- Describe each structure of the oral cavity as to location, color, size, and/or shape.
- Define the terms noted in boldface.
- Complete the worksheet at the end of the chapter.

Key Terms

Anterior tonsillar pillar
Buccal
Circumvallate
Filiform
Foliate
Foramen caecum
Fordyce granules
Fovea palatinus

Continues

Key Terms *continued*

Frenum
Fungiform
Gingiva
Hard palate
Incisive papilla
Labial
Labial commissure
Labial tubercle
Labiomental groove
Linea alba
Lingual frenum
Mandibular tori
Maxillary tuberosity
Median sulcus
Nasolabial groove
Oral cavity
Oral mucosa
Oral vestibule
Palatine raphe
Palatine rugae
Palatine torus
Philtrum
Posterior tonsillar pillar
Retromolar area
Soft palate
Stensen's papilla
Sublingual fold
Sublingual caruncle
Taste buds
Tonsils
Uvula
Vermilion zone

RELATED TERMINOLOGY

The names of many oral cavity structures, as well as associated and descriptive terms, are derived from Latin words. As these words appear over and over again throughout the readings, it is helpful to become familiar with them. See Table 2–1.

TABLE 2–1. Oral Cavity Terminology

TERM	MEANING
Alba	White
Bucca	Cheek
Buccal	Relating to the cheek

Continues

TABLE 2–1. Oral Cavity Terminology *continued*

TERM	MEANING
Fornix	Arch
Frenum	Folds of tissue
Labia	Lip
Labial	Relating to the lip
Linea	Line
Lingual	Relating to the tongue
Mental	Relating to the chin
Nasal	Relating to the nose
Naso	Nose
Oral	Relating to the mouth
Plica	Fold (of tissue)
Raphe	A seam (of tissue)
Sub	Under

© Cengage Learning 2013

THE ORAL CAVITY

The term **oral cavity** is used when referring to the inner portion of the mouth. The oral cavity extends from the anterior opening at the lips to the oropharynx, or throat posteriorly. The palate, or roof of the mouth, is the superior, or upper, border; and the tongue, along with the musculature beneath it, defines the inferior or lower boundary.

The soft, moist tissue called the *mucous membrane* lines the oral cavity. In the mouth, the mucous membrane is referred to as the **oral mucosa**. The oral mucosa is pink and occurs in various degrees of thickness. Although the oral mucosa is not as strong or as thick as skin, it acts as a protective covering for the oral cavity. In some areas, the oral mucosa is firmly attached, as on the gingiva and hard palate. In other areas, such as the cheek, it is much looser. There are three types of oral mucosa, each classified according to function and location:

1. *Masticatory mucosa* covers areas subject to stress, such as gingival tissue and the hard palate.
2. *Specialized mucosa* covers the area that has the specific function of taste on the dorsum of the tongue.

3. *Lining mucosa* covers all other areas of the oral cavity, such as the inner surfaces of the lips and cheeks and the floor and roof of the mouth.

Divisions

The oral cavity is divided into two sections, the oral vestibule and the oral cavity proper. The **oral vestibule** is the area between the inner lips, or **labial** mucosa, and cheeks (**buccal** mucosa) and the front (facial) surfaces of the teeth. The *oral cavity proper* extends from the inner (lingual) surfaces of the teeth to the oropharynx.

Functions

Chewing of food, or mastication, is the most obvious function of the oral cavity. As chewing occurs, food is moistened with saliva, preparing it for swallowing (deglutition) and digestion. The tongue is the taste organ for food and assists the cheek and lip muscles with movement of food within the oral cavity. In addition to these functions, the oral cavity provides an air passage and assists the tongue with speech.

STRUCTURES EXTERNAL TO THE ORAL CAVITY

The structures of the lips, cheeks, and related areas of the face are closely associated with the oral cavity because they assist with its effective functioning (**Figure 2–1**). These outer structures are comprised of muscles that aid in opening and closing the lips, and compressing food against as well as moving it away from the teeth. They include:

Labial commissure: the closure line of the lips where upper lip meets lower lip

Philtrum: shallow depression extending from the area below the middle of the nose to the center of the upper lip

Vermilion zone: the pink border of the lips (thinly keratinized epithelium)

Nasolabial groove: a shallow depression extending from the corner of the nose (ala) to the corner of the lips

Labiomental groove: a shallow linear depression between the center of the lower lip and the chin

Labial tubercle: a small projection in the middle of the upper lip that may enlarge or thicken

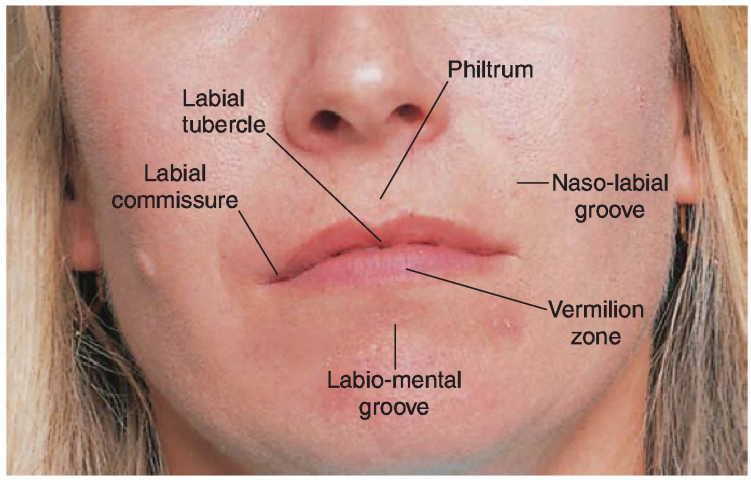

Figure 2–1. External Structures of the oral cavity.

STRUCTURES OF THE ORAL VESTIBULE

Although the oral vestibule is a small antechamber, it contains several structures that should be recognized.

Labial frenum: an elevated fold of soft mucous tissue extending from the alveolar mucosa of the two central incisors to the labial mucosa (A superior frenum exists in the maxillary area; an inferior frenum is located in the mandibular area.) (See **Figure 2–2A**.)

Buccal frenum: an elevated fold of soft tissue extending from the alveolar mucosa above the canine or premolar to the buccal mucosa (See **Figure 2–2A**.)

Maxillary tuberosity: a small, rounded extension of bone, covered with soft tissue, posterior to the last maxillary tooth

Retromolar area: a triangular area of bone, covered with soft tissue, posterior to the last mandibular tooth

Stensen's papilla (parotid papilla): a small, raised flap of soft tissue on the buccal mucosa opposite the maxillary molar (It is often marked with a tiny red dot, which is the opening to the parotid or Stensen's salivary gland.)

Linea alba: a raised, white horizontal extension of soft tissue along the buccal mucosa at the occlusal line (The literal translation of these words is "white line." The linea alba is not present in all mouths.)

Gingiva: pink, stippled mucosa surrounding the necks of the teeth and covering the bone in which the teeth are anchored (See **Figure 2–2B**.)

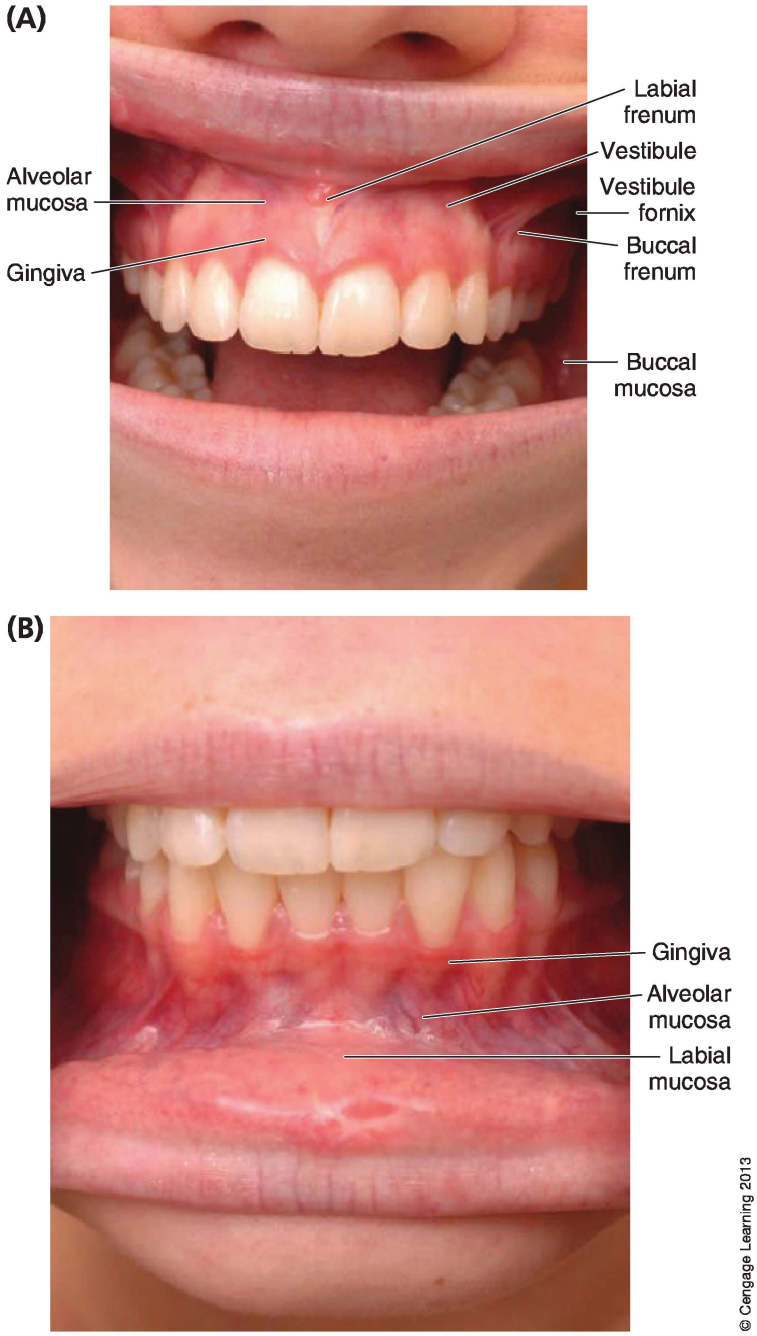

Figure 2–2. Structures of the oral vestibule.

Fordyce granules: small, yellow spots on the buccal mucosa and inner lip, which are sebaceous glands and have no clinical significance

Anterior tonsillar pillar: folds of tissue that extend horizontally from the uvula to the base of the tongue (See **Figure 2–3A**.)

Posterior tonsillar pillar: a set of arches of tissue set farther back in the throat than the anterior tonsillar pillar (See **Figure 2–3A**.)

STRUCTURES OF THE ORAL CAVITY PROPER

Roof of the Mouth

When the mouth is wide open, it is possible to observe all the structures of the oral cavity proper. The following structures are located on the roof of the mouth (see **Figure 2–3B**):

Palate: the concave surface that is known as the roof of the mouth and is divided into the hard and soft palate

Hard palate: the bony anterior two-thirds of the palate that is covered with mucosa (See **Figure 2–3B**.)

Soft palate: the posterior third of the palate, comprised of muscular fibers covered with mucosa (It is a deeper color pink than the hard palate because of its highly vascular composition.)

Palatine torus: a bony prominence of varied size located at the midline of the hard palate (It is a nonpathologic excess of bone covered with mucosa and only is present in about 20 percent of the population.)

Incisive papilla: a small, raised, rounded structure of soft tissue at the anterior midline of the hard palate (It is directly behind the two maxillary central incisors and covers and protects the incisive foramen, an opening in the bone directly beneath it through which nerves and blood vessels travel.) (See **Figure 2–3B**.)

Palatine raphe: a junction of soft tissue extending vertically along the entire midline of the hard palate; also known as the median palatine raphe (See **Figure 2–3B**.)

Palatine rugae: paired raised, transverse palatine folds of soft tissue on the anterior portion of the hard palate, which extend horizontally from the raphe and prevent food from adhering to the palate (See **Figure 2–3B**.)

Fovea palatinus: two small indentations, one on either side of the raphe, located at the junction of the hard and soft palate (These are remnants of minor salivary glands. Their only value is as the terminal demarcation in the fabrication of the maxillary denture.)

Uvula: a downward projection of the soft palate comprised of connective tissue, muscles, and glands (See **Figure 2–3A**.)

Fauces

The following structures are located at the posterior portion of the oral cavity and form the pillars of fauces, the arch or entryway that joins the oral cavity with the pharynx, shown in **Figure 2–3A**.

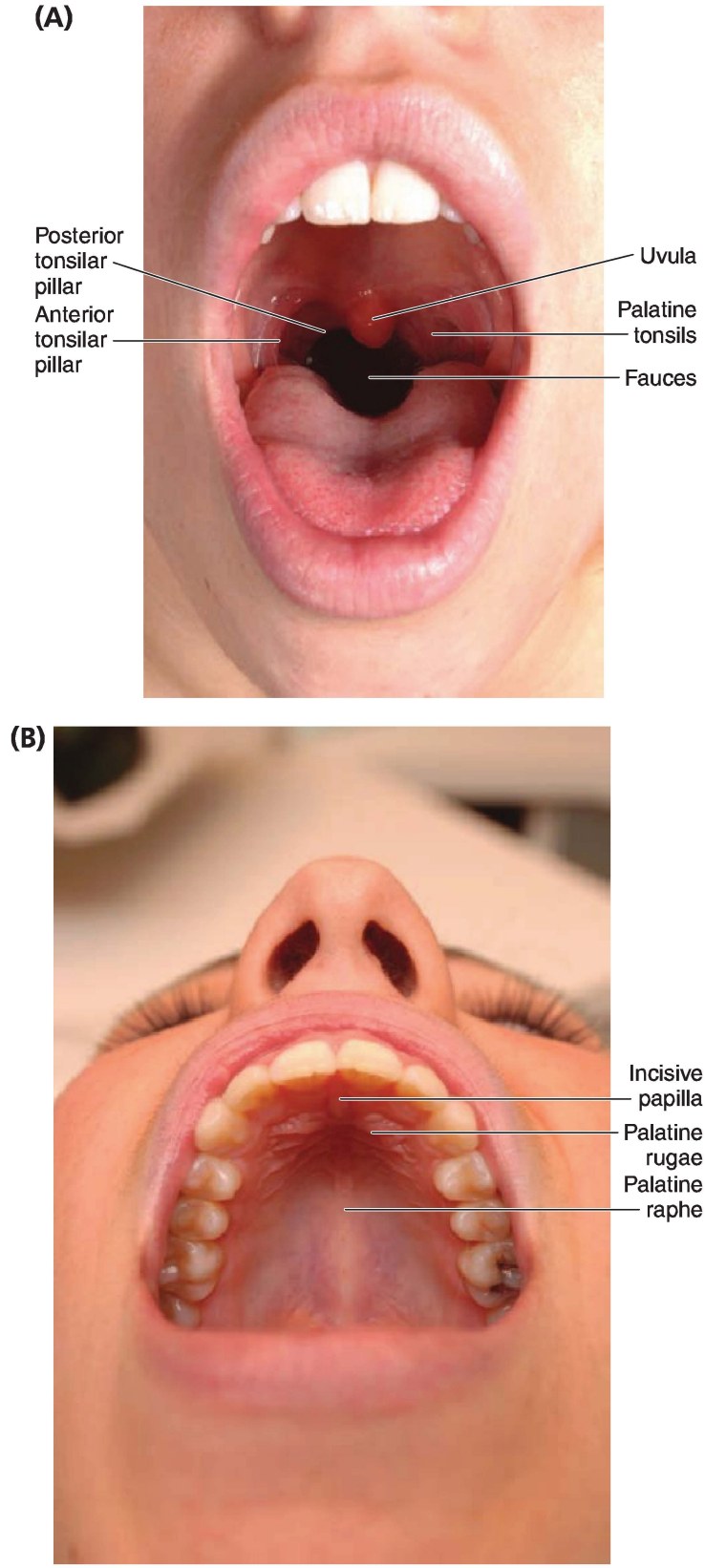

Figure 2–3. Structures of the oral cavity proper.

Oropharynx: the area of the oral cavity that joins it with the throat or pharynx (On either side are the arches of muscular tissue called the pillars of fauces.)

Glossopharyngeal muscle: the anterior pillar of fauces extending from the outer surface of the palate to the tongue

Palatopharyngeal muscle: the posterior pillar of fauces extending from the pharynx to the palate

Palatine tonsils: masses of lymphoid tissue located between the anterior and posterior pillars of fauces (See **Figure 2–3A**.)

Tongue

The tongue is a muscular structure covered with oral mucosa. The anterior two-thirds of the tongue is referred to as the *body*; the posterior third is the *base* of the tongue. The following structures are located on the *dorsum* of the tongue, as shown in **Figure 2–4A**.

Median sulcus: a shallow groove extending along the midline of the tongue, ending in a slight depression called the *foramen caecum*

Foramen caecum: a "V"-shaped terminal sulcus at the posterior area of the median sulcus, considered the junction of the oral and pharyngeal sections of the tongue

There are numerous *papillae* on the dorsum of the tongue:

Circumvallate: form a "V" shape and are anterior to the foramen caecum. They vary from eight to ten in number and are the largest of the papillae.

Fungiform: are located on the sides and apex of the tongue, although they can appear on other portions as well. These are broad, round, red toadstool-shaped papillae.

Filiform: are abundantly located on the anterior two-thirds of the tongue. These long, thin, more flexible papillae are greyish in color.

Foliate: are located on the lateral surfaces of the posterior third of the tongue. There are three to five (or more) of these large raised papillae on each side.

The tongue functions as the main organ of taste and is an important adjunct of speech. It also assists in mastication by rolling and kneading the food against the teeth and hard palate, and in deglutition by pushing the food backward into the oropharynx.

Taste buds: are located in the papillae of the tongue and are stimulated when food is dissolved. The four primary taste sensations are bitter, sweet, salty, and sour (acid), as shown in Table 2–2.

The base of the tongue is attached. It is continuous with the oral portion, extending downward toward the epiglottis. The lingual tonsils (or lingual follicles), located on the sides of the posterior median line, are nodular masses of lymphoid follicles.

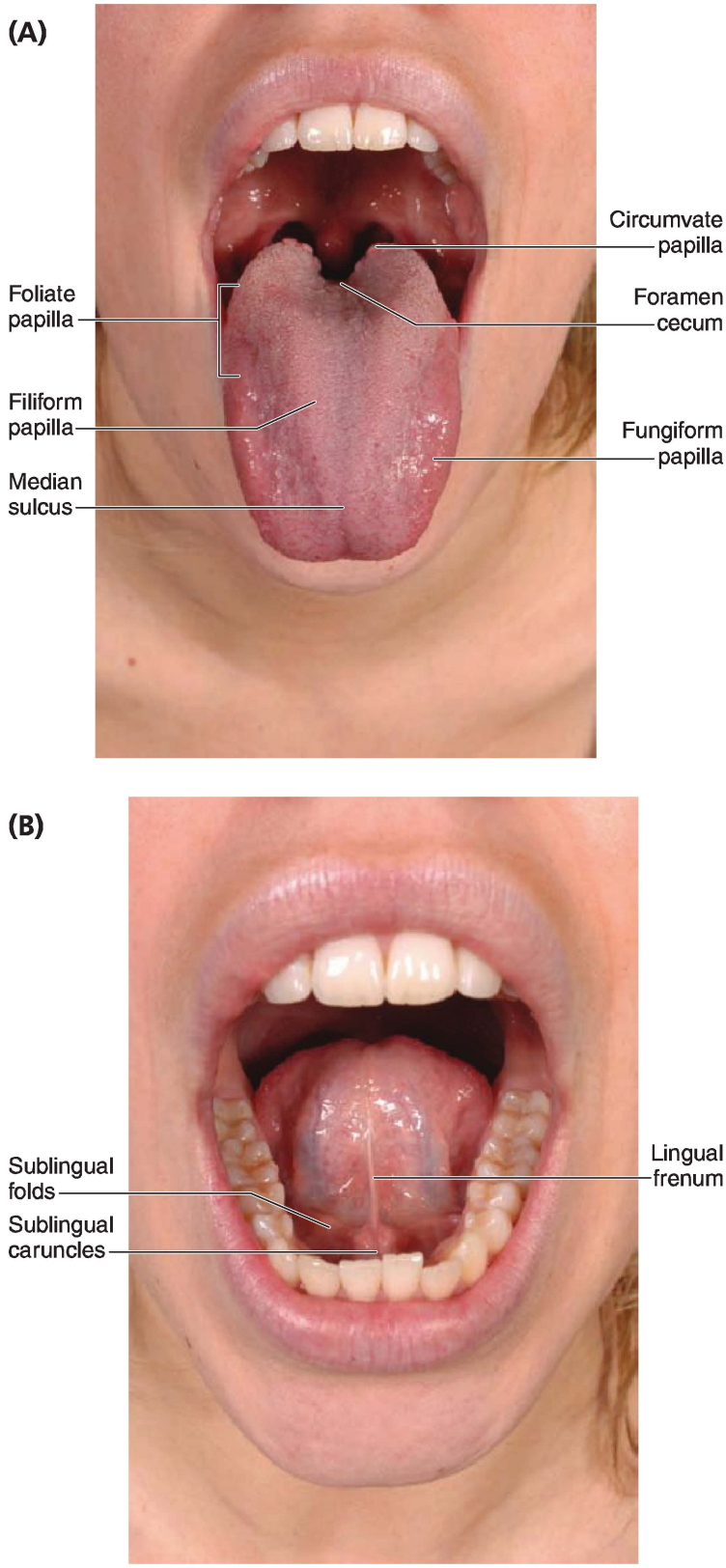

Figure 2–4. (A) Dorsum of the tongue (B) Structures located on the floor of the oral cavity.

TABLE 2–2. Papillae and Associated Tastes

PAPILLAE	TASTE
Circumvallate	Bitter
Fungiform	Sweet, sour, salty
Foliate	Sour
Filiform	Rarely have taste buds

© Cengage Learning 2013

The following structures are located on the floor of the oral cavity. In order for these structures to be observed, the tongue must be raised, as shown in **Figure 2–4B**.

Lingual frenum: an elevated fold of soft tissue located on the floor of the mouth at the midline, which extends from the tissue below the central incisors to the undersurface of the tongue

Sublingual caruncles: round, elevated sections of soft tissue on either side of the lingual frenum, directly behind the central incisors on the floor of the mouth. Within the caruncles are duct openings to the sublingual (Bartholin's) and submandibular (Wharton's) salivary glands.

Sublingual plica or fold: an elevated fold of soft tissue extending, medially, along the floor of the mouth toward the tongue and contains the opening to salivary glands called the *ducts of Rivinus*

Mandibular tori: an overgrowth of bone occurring bilaterally on the internal borders of the mandible, which, as with the maxillary torus, is nonpathologic and occurs in only 8 percent of the population

SUMMARY

The structures external to the oral cavity include the lips, cheeks, and related areas of the face that assist the oral cavity in functioning effectively.

The entire oral cavity, or mouth, is lined with a soft, moist covering called the *oral mucosa*. This lining has different degrees of consistency that enhance and protect oral structures such as the tongue and hard palate.

The oral cavity is divided into two sections: the oral vestibule and the oral cavity proper, each with its associated structures. It is important to be familiar with the complete anatomy of the oral structures as well as with the terminology necessary for differentiating normal from abnormal.

Define the following words

Buccal _____

Sub _____

Frenum _____

Labial _____

Lingual _____

Mental _____

Nasal _____

Plica _____

Raphe _____

Clinical Applications

For the following observations of the oral cavity, a mouth mirror and a piece of gauze are needed.

Review all the structures of the oral cavity so that you will be able to recognize the normal and any deviation from it.

For each structure listed, provide the following information:

- Its precise location in the oral cavity
- Its clinical appearance (size, shape, color, texture)
- Its comparison to the normal

Using this information as a guide, complete your observations.

1. Vermillion area: Is there cracking? Note any sores. What is the variation in coloring?
2. Philtrum: Note the depth of concavity. How does this affect one's appearance?
3. Maxillary tuberosity: Is this a large projection? What is the condition of the tissue?
4. Retromolar area: Is this mucosa about the same consistency as the buccal mucosa? How large an area is this?
5. Labial frenum: About how many millimeters is this small extension of tissue? Does it extend onto the attached gingiva?
6. Lingual frenum: What is the extent of its length? Is it raised or flat?
7. Buccal frenum: In what position must the jaws be before this can be observed? Which posterior teeth lie adjacent to this?
8. Incisive papilla: Is it raised, flat, inflamed?
9. Palatine rugae: Are they raised or flat? How many pairs are observed?

10. Palatine raphe: How far does this extend along the palate? Is it clearly observed?
11. Fovea palatinus: Are they on the hard or soft palate?
12. Pillars of fauces: Provide another name for the anterior and posterior pillar.
13. Palatine tonsils: Are they present? Describe their position and condition.
14. Uvula: Is it inflamed? What is the length?
15. Tongue: Observe the size, and note whether it is coated. Also locate the papillae: filiform, fungiform, circumvallate, and foliate.
16. Sublingual caruncles: Can you see the duct openings? Describe what the duct openings are like. How high are the caruncles?
17. Buccal mucosa: Is it consistently pink and soft?
18. Stenson's papilla: Which posterior tooth is adjacent to this? Can the opening to the duct be seen?

Answer the following multiple-choice questions

1. Which of the following is the superior boundary of the oral cavity proper?
   - **a.** rugae
   - **b.** buccal mucosa
   - **c.** palate
   - **d.** uvula
2. An elevated fold of soft mucosal tissue extending from the alveolar mucosa of the maxillary central incisors to the labial mucosa is referred to as:
   - **a.** rugae
   - **b.** raphe
   - **c.** labial frenum
   - **d.** fovea
3. A raised, white horizontal extension of soft tissue extending along the buccal mucosa at the occlusal line is referred to as:
   - **a.** palatine rugae
   - **b.** linea alba
   - **c.** raphe
   - **d.** buccal fovea

4. A bony prominence located at the midline of the hard palate is referred to as:

a. uvula
b. frenum
c. papilla
d. torus

5. The area of the oral cavity that joins with the throat is referred to as:

a. oropharynx
b. oral septum
c. oronasum
d. oral tonsil

6. The most numerous papilla on the dorsum of the tongue are:

a. fungiform
b. fusiform
c. filiform
d. foliate

CHAPTER 3

The Tooth and Its Surrounding Structures

Divisions of the Tooth

Surfaces of the Tooth

Tissues of the Tooth

The Periodontium

Objectives

At the completion of this chapter, you will be able to:

- Identify the divisions of the tooth, surfaces of the tooth, tissues of the tooth, and tissues of the periodontium.
- Describe each tooth tissue and those of the surrounding structures as to location, composition, and function.
- Define the terms noted in boldface.
- Complete the worksheet at the end of the chapter.
- Perform the clinical applications at the end of the chapter.

Key Terms

Alveolar mucosa
Alveolar process
Alveolus
Anatomic crown
Anatomic root
Apex
Apical foramen
Attached gingiva
Buccal
Cementum
Cervix
Clinical crown

Continues

Key Terms *continued*

Contact area
Crown
Dentin
Distal
Enamel
Facial
Free (marginal) gingiva
Free gingival junction
Incisal edge
Interproximal
Labial
Lamina dura
Line angle
Lingual
Melanin
Mesial
Mucogingival junction
Occlusal
Periodontal ligament
Point angle
Proximal
Pulp
Pulp canal
Pulp cavity
Pulp chamber
Pulp horns
Root
Sulcus

DIVISIONS OF THE TOOTH

When examining the tooth, note that it is divided into three sections (**Figure 3–1**):

1. The crown
2. The neck or cervix
3. The root

The **crown** is that portion of the tooth normally visible in the mouth and covered with enamel. The teeth have differently shaped crowns, each adapted to perform a specific function in reducing food for digestion.

The **root**, located in the bone and not normally visible, is covered with cementum. Roots stabilize, or support, the teeth when the pressure from mastication is exerted upon them. The crown joins the root at the neck, **cervix**, or cemento-enamel junction (CEJ), a junction between the **anatomic crown** and the **anatomic root**. The anatomic crown is covered

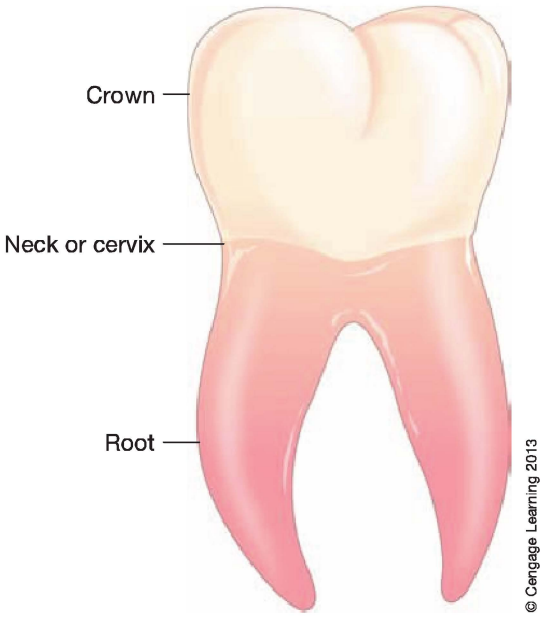

Figure 3–1. The three divisions of a tooth: crown, neck or cervix, and the root.

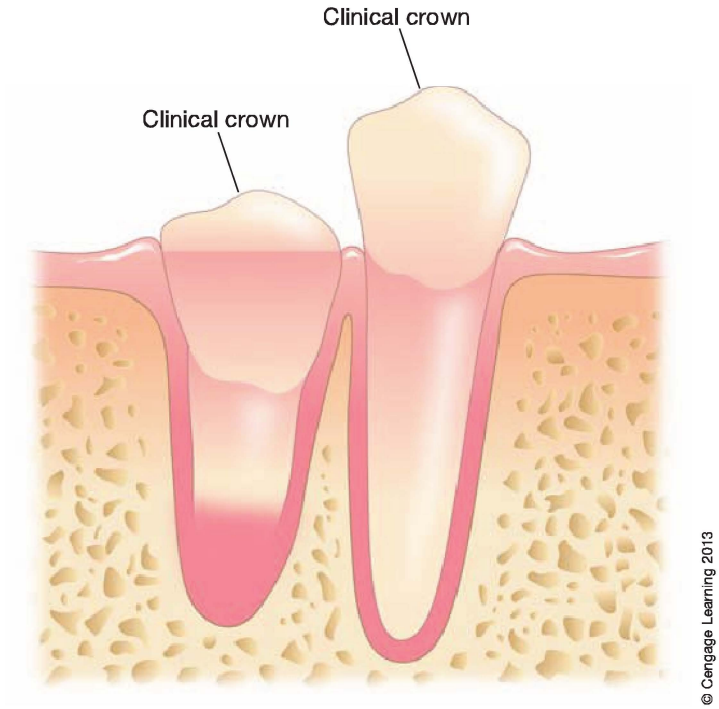

Figure 3–2. Clinical crown.

with enamel; the anatomic root is covered with cementum. After eruption is complete, only the anatomic crown is seen in the mouth. In later life, as part of the aging process, the gingiva and bone may recede, exposing a portion of the root. All of the tooth that is visible in the mouth, the crown *and* the exposed root together, is referred to as the **clinical crown** (**Figure 3–2**). The clinical crown extends from the biting surface of the tooth to the gingival margin.

SURFACES OF THE TOOTH

Every tooth has five surfaces, each surface named according to its position in the arch (**Figure 3–3**).

Mesial: the surface closest to the midline

Distal: the surface farthest, or most distant, from the midline

Facial: the surfaces closest to the face or outer surfaces of the teeth, including:

Labial: facial surfaces of anterior teeth or surfaces closest to the lip

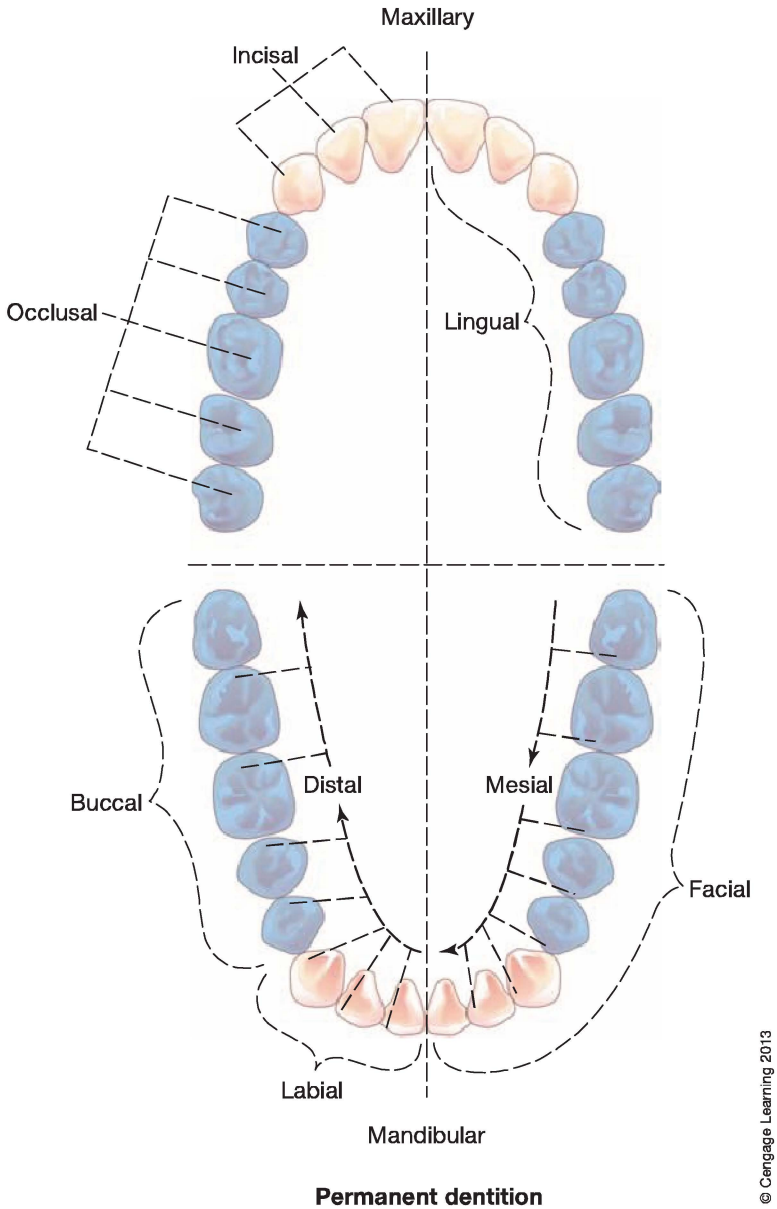

Figure 3–3. The surfaces of the teeth identified on the dental arches.

Buccal: facial surfaces of posterior teeth or surfaces closest to the cheek
Lingual: surfaces closest to the tongue or palate; all the inner surfaces
Occlusal: chewing surfaces of the posterior teeth
Incisal edge: biting surface of the anterior teeth

Other terms that relate to the surfaces of the teeth are as follows:

Proximal: the surface of the tooth that is next to, or beside, the adjacent tooth (Mesial and distal surfaces are both proximal surfaces.)

Interproximal: a triangular space between adjacent teeth that is normally filled with the portion of the gingiva called interdental papilla

Contact area: an area on both the mesial and distal surfaces that touches, or contacts, the adjacent tooth

Apex: the tip of the root

Line angle: the area of the tooth where two surfaces meet, such as the line that joins the buccal and mesial surfaces would be called the mesiobuccal line angle (**Figure 3–4**)

Point angle: the area of the tooth where three surfaces meet (for example, the joining point of the occlusal, lingual, and mesial surfaces shown in **Figure 3–4**)

To describe the precise location of an anatomic tooth structure, it is useful to divide the crown and root into thirds. Imaginary horizontal lines divide the crown into incisal or occlusal, middle, and cervical thirds and the root into cervical, middle, and apical thirds. Vertical thirds can be used to divide the tooth into mesial, middle, and distal thirds also shown in **Figure 3–4**, **Figure 3–5**, and **Figure 3–6**. When explaining details of the tooth, note that a groove can be described as extending to the junction of the occlusal and middle third. This same groove can be located in the distal third of the tooth.

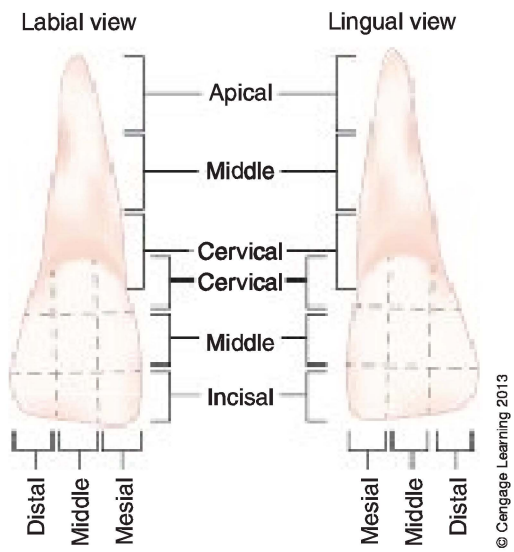

Figure 3–4. Labial and lingual views of a maxillary right central incisor, which shows the division of the tooth surfaces in thirds.

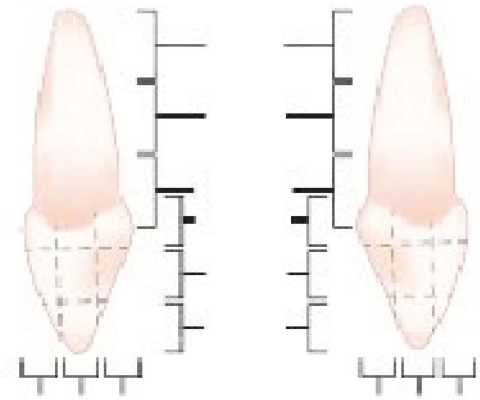

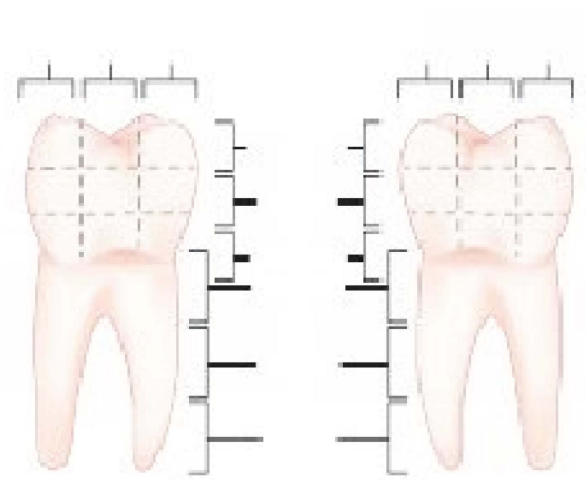

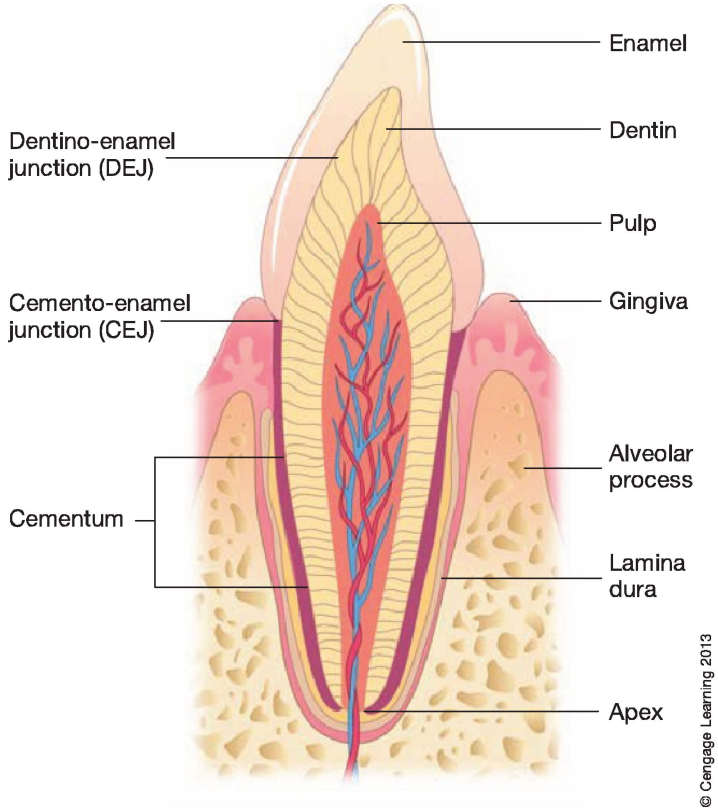

Figure 3–7. Tooth and surrounding tissues.

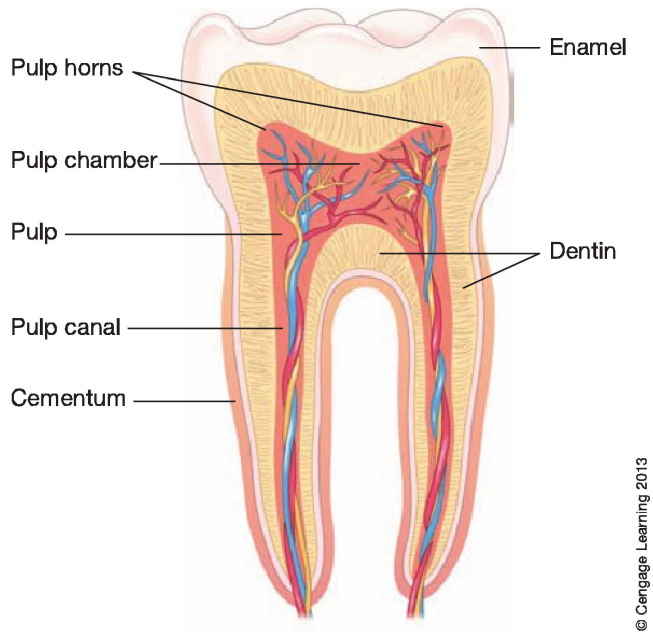

Figure 3–8. Tissues of the tooth. Pulp is the only soft tissue of the tooth.

paint on a wall, resulting in its being easily removed during scaling or root planing, or by abrasion when the root is exposed. However, additional cementum can be produced after the eruption of the tooth on areas not exposed in the oral cavity.

Theoretically, the cementum joins the enamel at the cemento-enamel junction (CEJ). Histologically, however, one of three variations can occur at the cervix:

1. The cementum slightly overlaps the enamel, the most commonly occurring condition.
2. The cementum joins smoothly with enamel.
3. A tiny gap exists between the cementum and the enamel.

Cementum attaches the tooth to the bone by tiny fibers called *Sharpey's fibers*. These extend from the surrounding periodontal ligament into the cementum.

Dentin

Dentin comprises the major portion of both the crown and the root of the tooth. It is located directly beneath the enamel of the crown and the cementum of the root. Dentin, harder than bone, is 70 percent inorganic and 30 percent organic matter and water. It is composed of an organic matrix, which contains dentinal tubules. The tubules are filled with dentinal fibrils that extend from the pulp to the enamel and carry sensation (temperature, pain) to the pulp.

Pulp

The **pulp** is located at the innermost portion of the tooth and is the only soft tissue of the tooth. It is comprised of blood vessels, cellular substances, and nerves.

That pulp structure located in the crown is the **pulp chamber**. It conforms to the shape of the crown, forming small peaks, or **pulp horns**, on the posterior teeth where the crown rises to form cusps (**Figure 3–8**). The pulp canal is the structure of the pulp located in the root of the tooth. Together, the pulp chamber and the **pulp canal** make up the **pulp cavity**, a space within the center of the tooth. Vessels of the pulp enter and exit the tooth through a small **apical foramen**, or hole, in the apex of the root, where they merge with other similar vessels of the jaw.

The function of the pulp is to assist in the production of dentin, provide sensitivity to the tooth, and act as a defense mechanism by reacting to injury. The pulp also provides nourishment to the tooth.

THE PERIODONTIUM

The periodontium includes those structures that surround and support the teeth (Figure 3–9):

- Cementum
- Periodontal ligament
- Alveolar process
- Gingiva

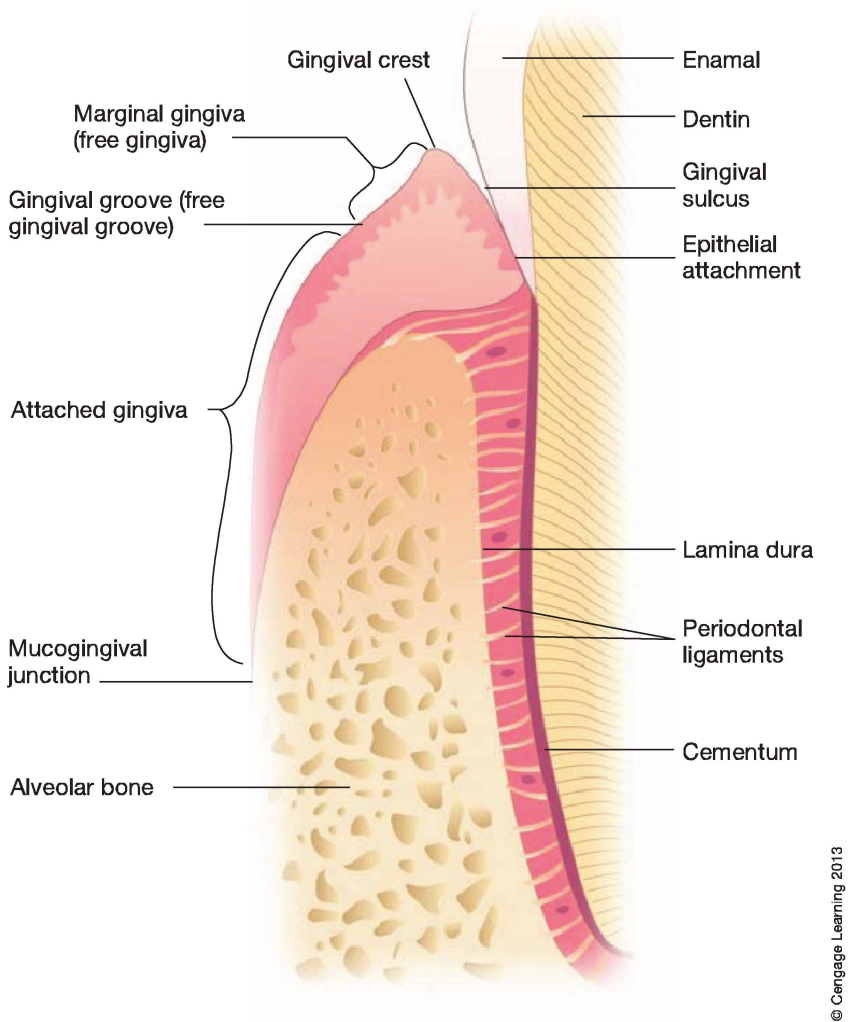

Figure 3–9. Periodontium includes vital structures to support the teeth.

Cementum

Cementum, previously described as a tissue of the tooth, is also considered a supporting structure because it contains fibers extending to the periodontal ligament that hold the tooth in its socket.

Periodontal Ligament

The **periodontal ligament** surrounds the root of the tooth. It is comprised of fibers, or ligaments, that support and suspend the tooth in the **alveolus**, or socket. Like a tiny trampoline, the fibers, arranged in bundles, act as a shock absorber to keep the tooth from pushing against the bone during the extreme pressure resulting from mastication. Other fibers extend from the periodontal ligament into the cementum on one side and into the alveolar process on the other side to attach the tooth to the bone. These are Sharpey's fibers.

Besides the fibers, the periodontal ligament contains nerves, blood, and lymph vessels. Its function is to produce cementum, stimulate bone resorption, provide sensation upon pressure to the tooth, and provide nutrients through the blood vessels.

Alveolar Process

The **alveolar process** is that portion of the maxilla and mandible that surrounds the roots of the teeth. It is separated from the roots by the periodontal ligament and is comprised of bone tissue composed of two layers:

1. Cancellous or trabecular bone
2. Compact or cortical bone

The inner layer, lightweight and porous, is the trabecular bone. It is surrounded by a denser layer of compact bone structured to endure stress. Compact bone is located adjacent to the periodontal ligament and at the alveolar crest. The layer that surrounds the periodontal ligament forms the socket or alveolus of each tooth and is called the **lamina dura**, meaning "hard layer."

Cancellous bone, the innermost layer, is less dense because of the tiny spaces called *trabeculae*. Without these trabeculae to provide porousness, the bone would be too heavy to move.

The alveolar process supports the tooth and stabilizes the root.

Gingiva

Gingiva, the only portion of the periodontium visible in the oral cavity, is comprised of epithelial tissue covered with mucosa (**Figure 3–10** and **Figure 3–11**). It attaches to the underlying bone, surrounds the cervix of the tooth, and fills the interproximal space. It is divided into two sections, free or

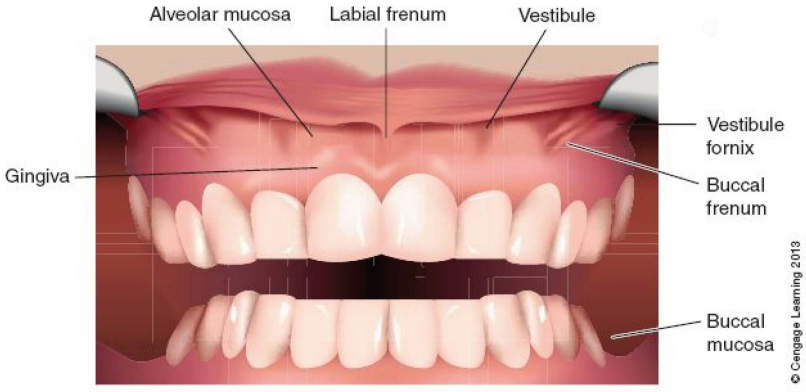

Figure 3–10. The periodontium identified on an individual.

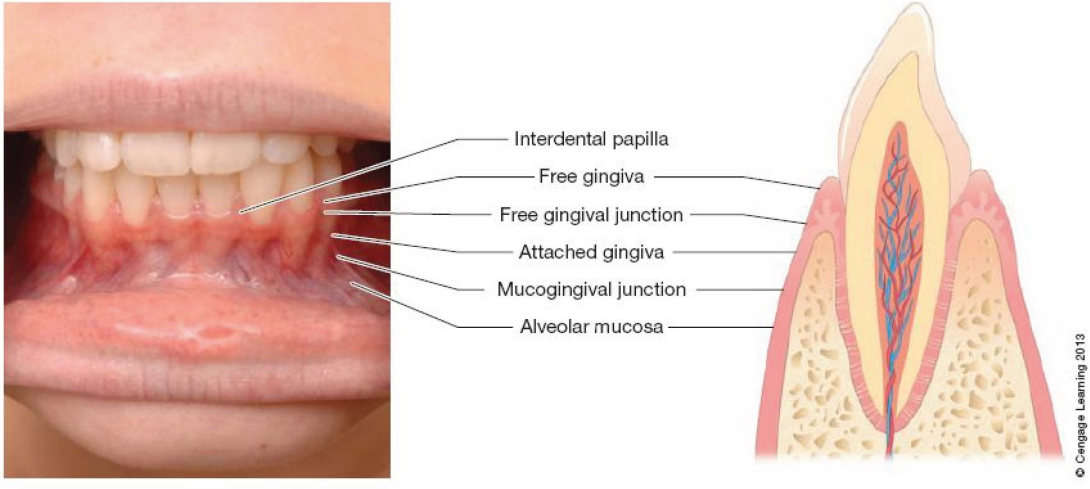

Figure 3–11. Divisions of the gingiva.

marginal gingiva and attached gingiva. Figure 3–10 shows gingival divisions in an individual's mouth.

FREE GINGIVA

The gingiva that surrounds the cervix (neck) of the tooth is like a collar and fills the interproximal spaces where it forms the interdental papilla.

Free (marginal) gingiva is unattached on the inner surface, creating a space or tiny gingival **sulcus** between it and the tooth, as shown in Figure 3–12. The depth of the healthy gingival sulcus is about 1.2 to 1.8 mm before it reaches the epithelial attachment, a layer of cells that merge it with

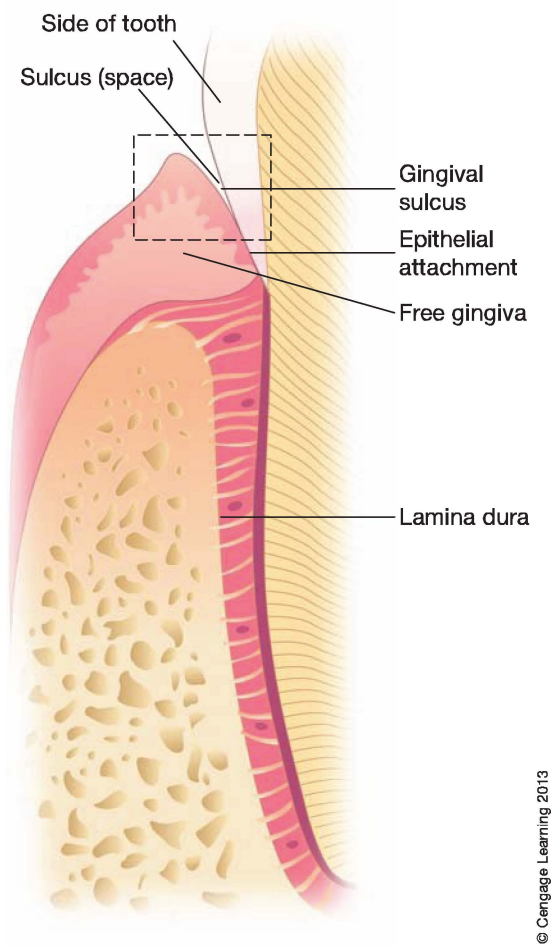

Figure 3–12. The gingival sulcus.

the tooth and the attached gingiva. The gingival sulcus forms a tiny triangle between the free gingiva and the surface of the tooth as its sides and the epithelial attachment as the apex.

ATTACHED GINGIVA

The **attached gingiva** is the portion of the gingiva that can be observed on the external surface. It merges with the free gingiva at the **free gingival junction**, a slight demarcation about 1.2 to 1.8 mm from the gingival crest. The attached gingiva extends apically from the free gingival junction, adhering tightly to the bone beneath it. As compared to other sections of the gingiva, it is pale pink because it is taut to the bone and contains fewer blood vessels.

Attached gingiva extends apically 3.5 to 9.0 mm, where it merges with the **alveolar mucosa** at the **mucogingival junction**, a scalloped line that follows the contour of the bone.

GINGIVAL DESCRIPTION

Healthy gingiva is pink and stippled (like the skin of an orange) on the attached portion. The color varies with the skin pigmentation so that the darker the skin, the deeper the pink of the gingiva. Occasionally, dark patches of pigmentation, **melanin**, appear on the gingiva of a darker skinned person; these spots of color are normal.

Normal gingiva is firm and resilient; it follows the contour of the bone and fills the interproximal spaces, forming a sharp, knifelike triangular point at the contact area. Attached gingiva adheres tightly to the bone and is pale, compared to the smooth shiny alveolar mucosa, which contains many blood vessels and thus appears as a darker red in color.

SUMMARY

The integrity of the tooth depends on the good health and stability of all the periodontal tissues. Together, they provide and maintain the longevity of the dentition and protect it from injury.

Using the following drawing, label the structures listed below

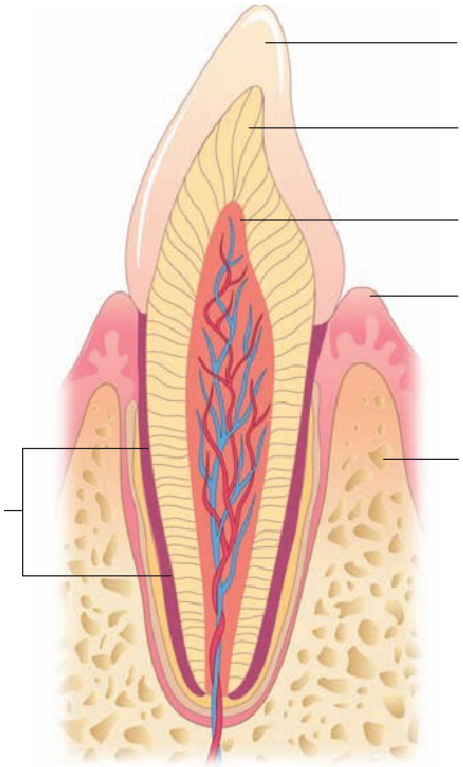

© Cengage Learning 2013

a. Enamel
b. Dentin
c. Pulp canal
d. Gingivia
e. Periodontal ligament
f. Alveolar bone

Clinical Applications

1. Observe the crowns of the teeth. Record those teeth where the clinical crown is greater than the anatomic crown.
2. Using the following illustrations, draw the height of the free gingiva of the maxillary molars. Draw this on both the buccal and lingual surfaces.

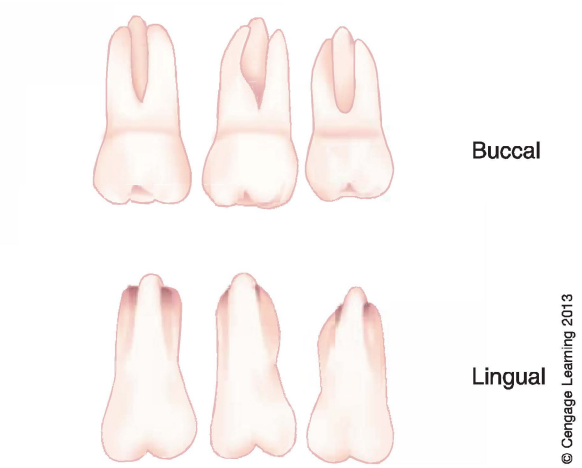

3. With an explorer, locate the cervical line (CEJ) of the right molars.
   a. Is the cervical line clinically visible on all teeth?
   b. Is the clinical crown larger or smaller than the anatomic crown?
4. Observe the gingiva. Locate and describe the following sections as they appear in the oral cavity:
   a. Marginal (free) gingiva
   b. Interdental papilla
   c. Attached gingiva
   d. Mucogingival line
   e. Alveolar mucosa

Answer the following multiple-choice questions

1. The surface closest to the midline is referred to as:
   a. mesial
   b. distal
   c. buccal
   d. lingual

2. The surface of the tooth that is beside, or adjacent, to the next tooth is referred to as:

a. buccal
b. lingual
c. palatal
d. proximal

3. The structure of the tooth that covers the root is referred to as:

a. enamel
b. alveolar
c. cementum
d. pulp

4. The portion of the pulp that is located in the root is referred to as:

a. pulp major
b. pulp horn
c. pulp chamber
d. pulp canal

5. The portion of free gingivae that fills the interproximal space is called:

a. attached gingiva
b. free gingival margin
c. mucogingival line
d. interdental papilla

CHAPTER 4

Tooth Identification Systems

The Universal Tooth Identification System

Palmer's Notation

Federation Dentaire Internationale (FDI)/ International Standards Organization (ISO)

Objectives

At the completion of this chapter, you will be able to:

- Identify three different tooth identification systems.
- Describe each identification system as to its designation of dentition, arch, quadrant, and tooth.
- Complete the worksheet at the end of the chapter.
- Perform the clinical applications at the end of the chapter.

THE UNIVERSAL TOOTH IDENTIFICATION SYSTEM

Permanent Teeth

In the United States, the Universal Tooth Identification System is the most widely accepted method used to record teeth. It is uncomplicated and efficient. Each tooth is numbered from 1 to 32 in consecutive order beginning with the patient's maxillary right third molar as tooth #1 and continuing to the maxillary left third molar as tooth #16 (**Figure 4–1**). The numbers continue on the mandibular left side with the mandibular left third molar, tooth #17, and follow consecutively to the mandibular right third molar, tooth #32.

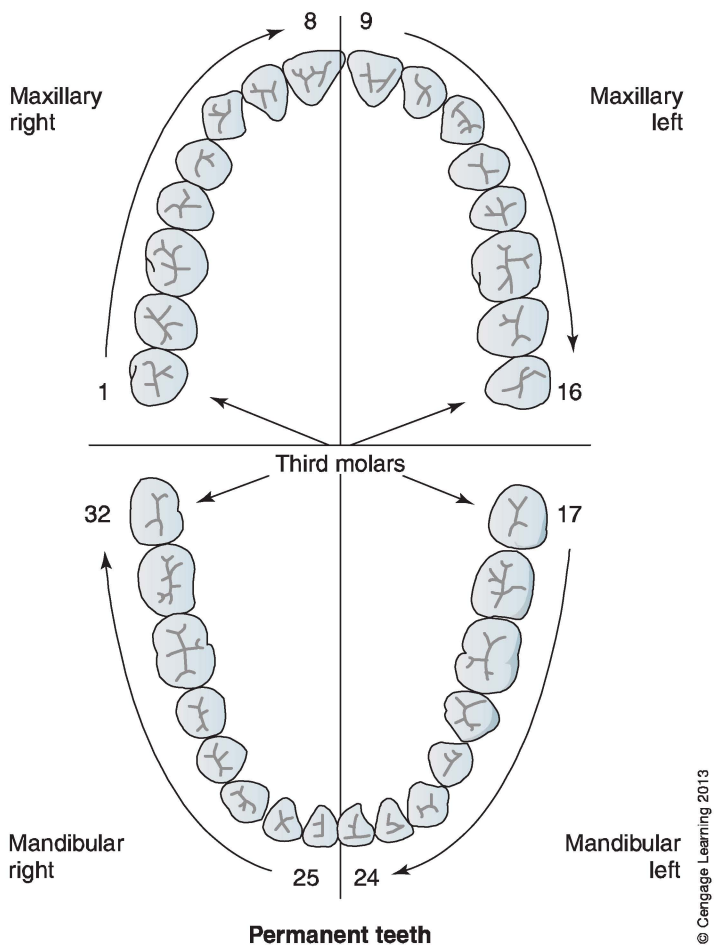

Figure 4–1. Universal Numbering System—permanent dentition.

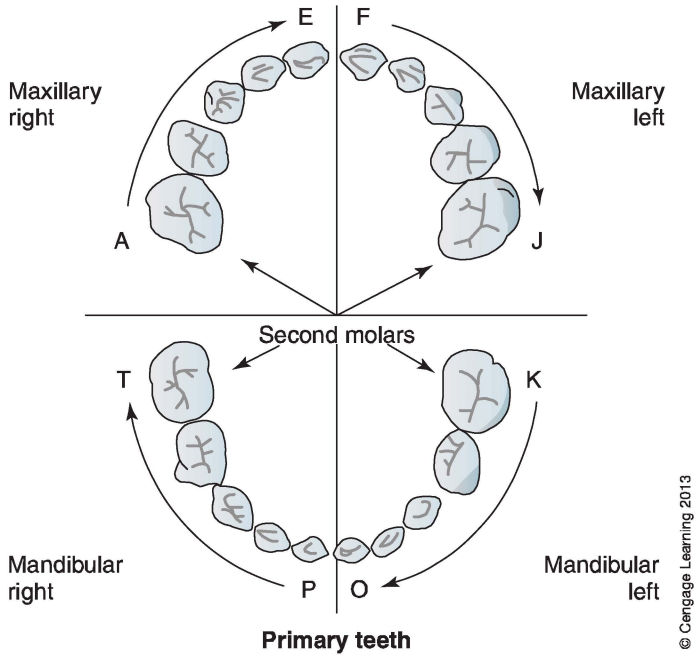

Figure 4–2. Universal Numbering System—primary dentition.

Primary Teeth

The primary teeth are numbered consecutively in the same manner as the permanent teeth from the maxillary right second molar to the maxillary left second molar using the letter "A" for the primary maxillary right second molar and "J" for the primary maxillary left second molar and continue on the mandibular left second molar with letter K and follow to the mandibular right second molar with letter T. See **Figure 4–2**.

PALMER'S NOTATION

Palmer's Notation designates each tooth according to its location in a quadrant. A horizontal line separates the maxilla from the mandible and a vertical midline separates the patient's right and left sides of the mouth, as shown in **Figure 4–3A and B**.

Permanent teeth are numbered 1 through 8 in each quadrant, beginning at the central incisor to the third molar. Primary teeth are designated with the letters A through E.

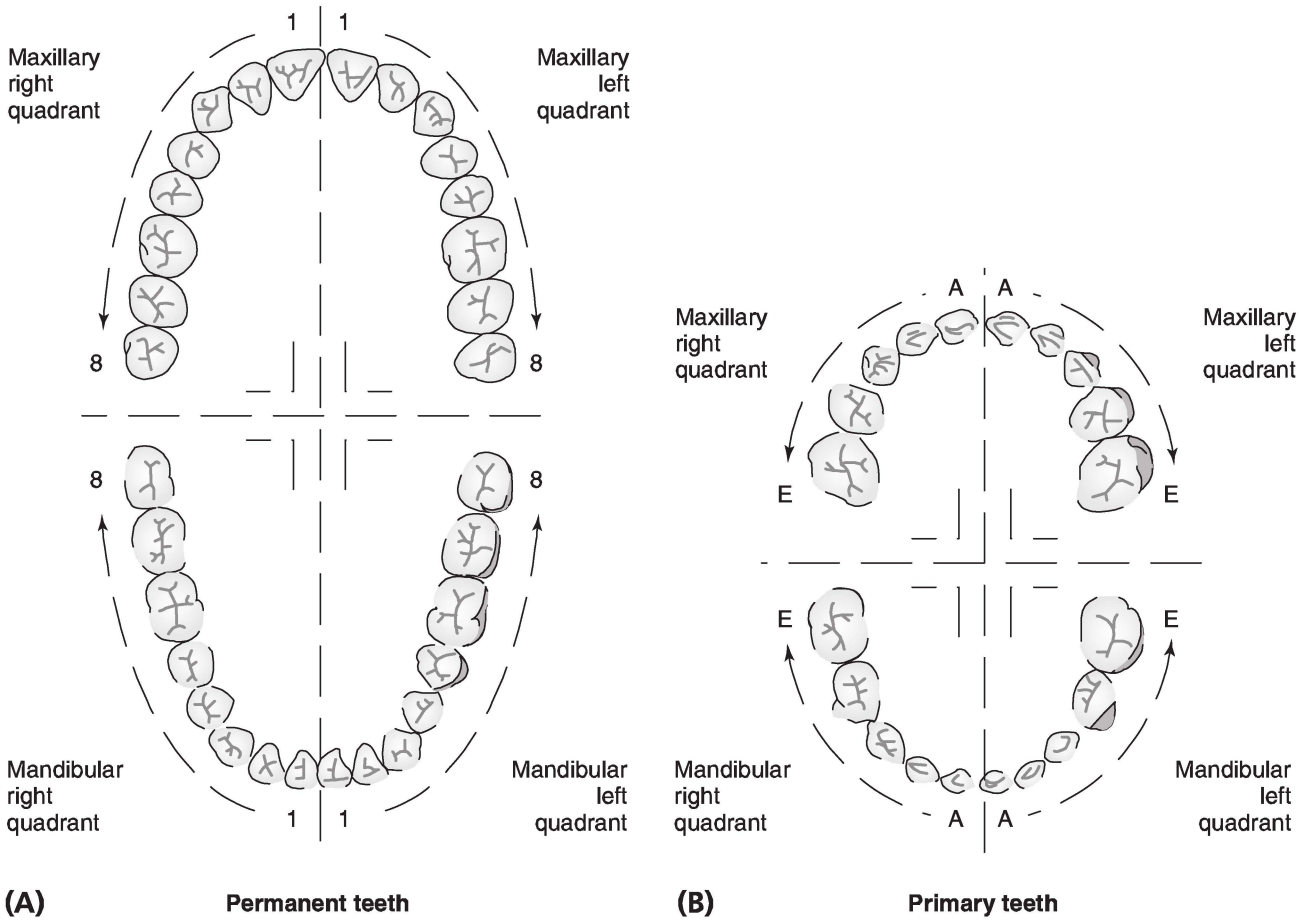

Figure 4–3. Palmer's Notation. (A) Permanent dentition (B) Primary dentition.

When identifying an individual tooth, use a right angle to specify the quadrant and arch, as follows:

maxillary right	maxillary left
mandibular right	mandibular left

The tooth number is written within the angle:

Permanent maxillary right central incisor	1
Permanent mandibular left first premolar	4
Primary maxillary left second molar	E
Primary mandibular right canine	C

FEDERATION DENTAIRE INTERNATIONALE (FDI)/INTERNATIONAL STANDARDS ORGANIZATION (ISO)

The FDI/ISO numbering system was introduced to provide a standard international system of coding teeth (**Figure 4–4A and B**). Each quadrant is assigned a number as in **Table 4-1**.

TABLE 4–1. FDI/ISO Quadrant Numbers

PERMANENT TEETH	
Maxillary right	1
Maxillary left	2
Mandibular left	3
Mandibular right	4
PRIMARY TEETH	
Maxillary right	5
Maxillary left	6
Mandibular left	7
Mandibular right	8

© Cengage Learning 2013

The teeth within each quadrant are then numbered l through 8, from the central incisor to the third molar, as with Palmer's notation. The primary teeth are numbered 1 through 5.

To use this system, identify each tooth with a two-digit figure: the first digit designates the dentition, arch, and quadrant; the second digit codes the individual tooth. For example:

Permanent maxillary right	→	1	3	←	canine	13
Permanent mandibular left	→	3	1	←	central incisor	31
Primary maxillary left	→	6	4	←	first molar	64
Primary mandibular right	→	8	2	←	lateral incisor	82

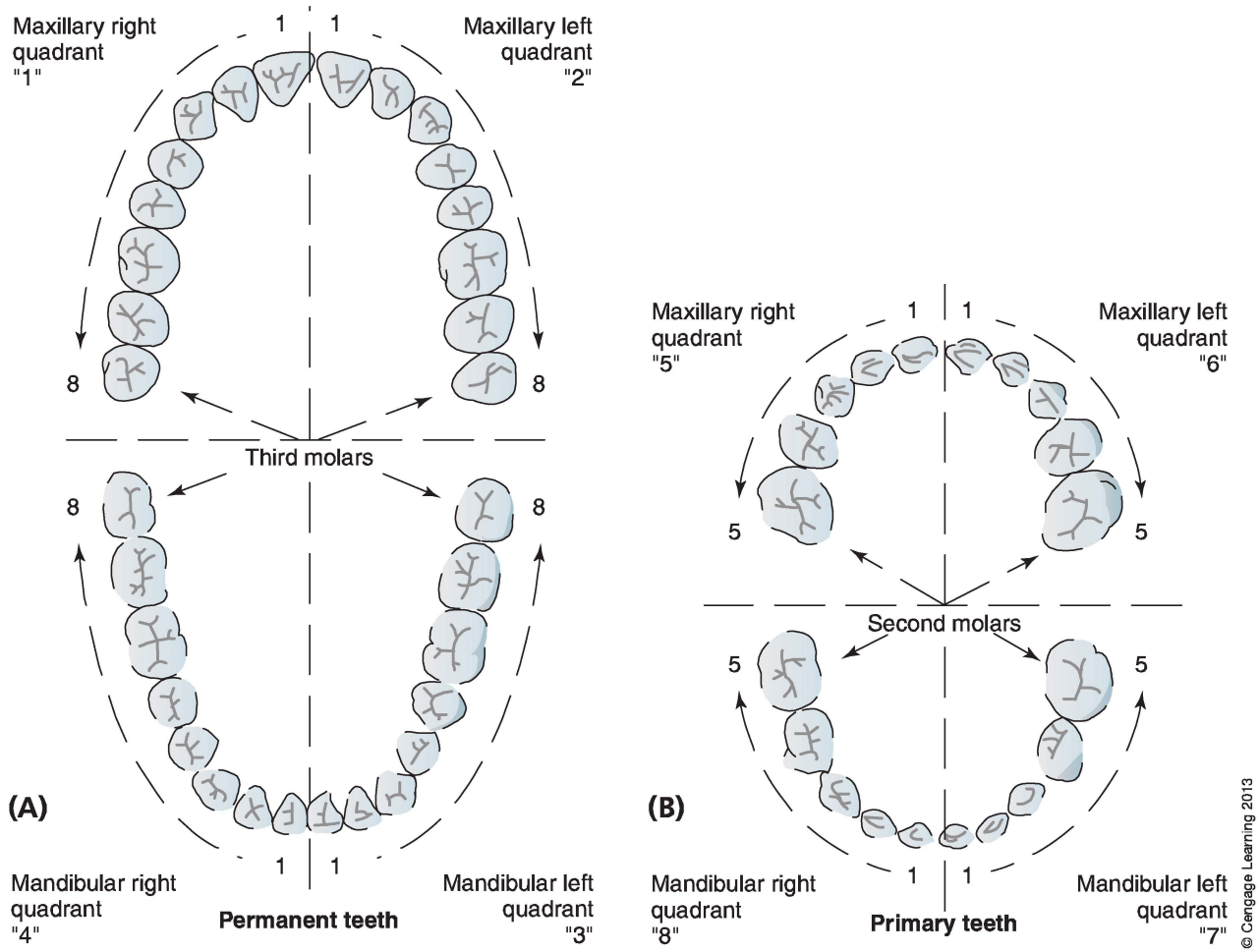

Figure 4–4. Federation Dentaire International (FDI)/International Standards Organization (ISO). (A) Permanent dentition (B) Primary dentition.

SUMMARY

The three tooth identification systems described—Palmer's Notation, the Universal Tooth Identification System, and the Federation Dentaire Internationale (FDI)/International Standards Organization (ISO)—are the most commonly used standards for identifying and charting teeth. Tooth identification systems provide a basis for coding the conditions of the teeth in a manner that is efficient and convenient for dental personnel.

WORKSHEET

Identify the appropriate code for each tooth listed.

	Universal	Palmer's	Number	Notation	FDI/ISO
Permanent Teeth					
Maxillary right second molar					
Maxillary left canine					
Maxillary left central incisor					
Mandibular left first premolar					
Mandibular right canine					
Maxillary right lateral incisor					
Mandibular right second molar					
Mandibular left first molar					
Deciduous Teeth					
Mandibular right canine					
Maxillary left second molar					
Mandibular left central incisor					
Maxillary right lateral incisor					
Mandibular left first molar					

Clinical Applications

1. Observe the teeth in each quadrant and record those that are missing by using the following numbering systems.
   a. Universal Tooth Identification System
   b. Palmer's notation
   c. FDI/ISO
2. Observe the maxillary first molar. Record its antagonist(s) by using the Universal Tooth Identification System.
3. Record the left premolars using Palmer's notation. Using the same recording method, note the deciduous teeth that precede the premolars.
4. Using the Universal Tooth Identification System, record the third tooth from the midline and the fourth tooth from the midline, both maxillary and mandibular. Are these the same teeth in the permanent and deciduous dentition?

5. Record the first permanent tooth to erupt using the universal number.
6. Which tooth replaces R?
7. Compare the crowns of #9 and #10.

Answer the following multiple-choice questions

1. The numbering system that designates the permanent teeth consecutively from 1 to 32 is referred to as:
   - **a.** the FDA system
   - **b.** Palmer's notation
   - **c.** the FDI system
   - **d.** the universal numbering system
2. Palmer's notation designates permanent teeth according to:
   - **a.** arches only
   - **b.** quadrants
   - **c.** numbers only
   - **d.** letters only
3. The correct identification for universal #8 is:
   - **a.** maxillary right central incisor
   - **b.** maxillary right lateral incisor
   - **c.** maxillary left central incisor
   - **d.** mandibular right central incisor
4. The correct identification for FDI 54 is:
   - **a.** deciduous maxillary right first molar
   - **b.** deciduous maxillary right first premolar
   - **c.** permanent maxillary right first premolar
   - **d.** deciduous mandibular right first molar
5. Using the universal numbering system, the mandibular left second premolar would have the designation of:
   - **a.** #28
   - **b.** #29
   - **c.** #20
   - **d.** #21

SECTION II

Permanent Anterior Teeth

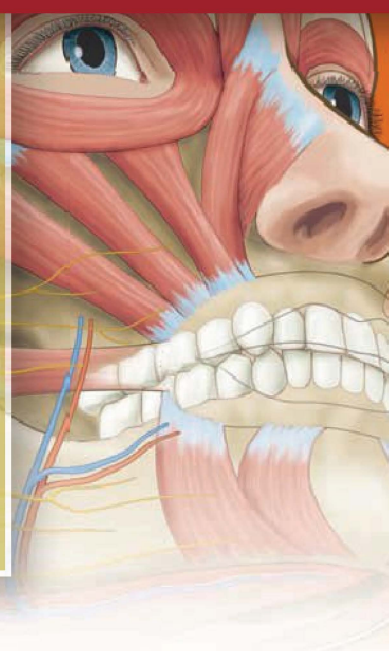

General Information

Chapter 5 Maxillary Incisors

Chapter 6 Mandibular Incisors

Chapter 7 Canines

GENERAL INFORMATION

At the completion of this section, you will be able to identify the location in the dental arch of each anterior tooth (**Figure II–1**), as well as its universal number, expected eruption date, usual crown and root completion dates, function, lengths of crown and root, antagonists, location of contact areas, number of lobes, and pulp canals. You will be able to state the age when there is first evidence of calcification during the formation of each tooth.

You will be able to describe the location and/or contour of the incisal edge or cusp slopes, the mesial and distal outlines, contact areas, surface characteristics, the developmental depressions, root shape, cervical lines, and lingual structures. Use Appendix C to compare the depth of the cervical lines of the teeth and to identify the location of the root depressions.

You will also be able to define terms such as **anomaly**, **cingulum**, **developmental depression**, **fossa**, **groove**, **lobe**, **pit**, and **root depression**.

Certain characteristics and structures are common to all anterior teeth. To assist in understanding the tooth morphology, and to avoid repetition throughout the chapters, the following related information provides a general background applicable to all anterior teeth.

Lobes. A lobe is a center of development and calcification from which a tooth is formed. All anterior teeth develop from four lobes that eventually coalesce to shape the crown. Three lobes form a labial surface of the crown and the

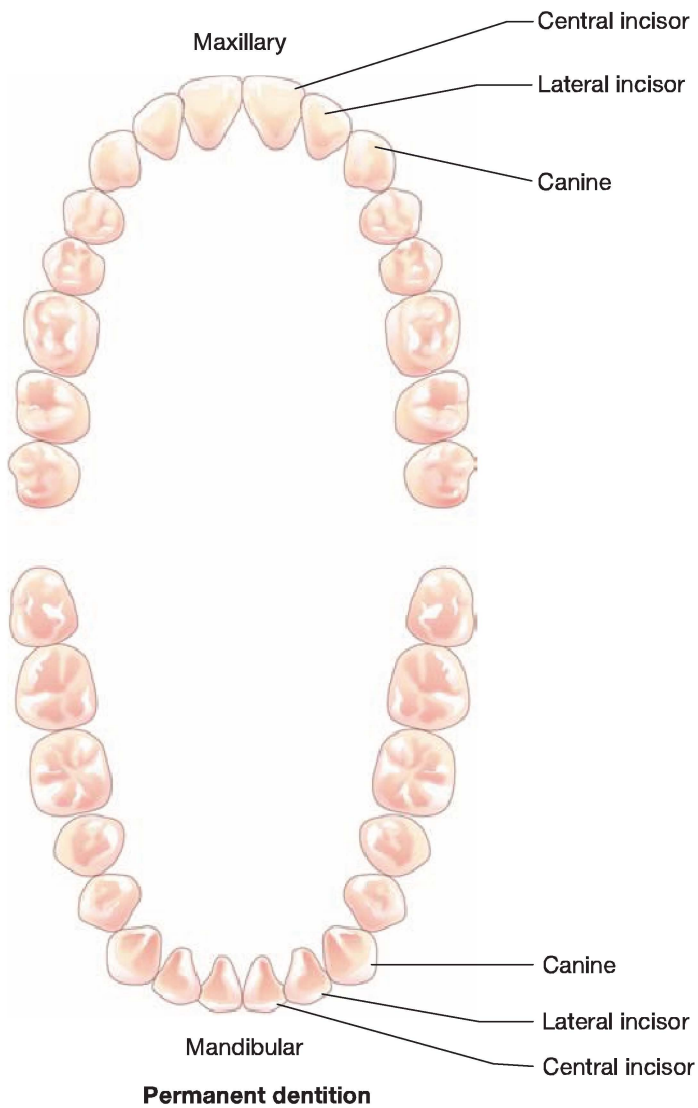

Figure II–1. Permanent anterior teeth.

fourth lobe shapes a cingulum on the lingual surface. Lines of demarcation from lobe coalescence are evident as linear depressions on the labial surface.

Mamelons. Mamelons are structures that comprise a scalloped border along the incisal edge of the incisors and are present at the eruption of the teeth. Mamelons are remnants of lobe formation that are worn away by attrition shortly after eruption (**Figure II–2**).

Cervical Line. The cervical line is also known as the cemento-enamel junction, or CEJ. It is a demarcation separating the anatomic crown and root. When the tooth is viewed from the labial or lingual surface, the cervical line appears as a semicircle curving toward the root. From the proximal surfaces, the cervical line curves incisally. Its depth varies from 1 to 3 mm; this is significant when the teeth are being scaled.

Col Area. The col area is a depression of the interdental papilla on the proximal surfaces of the teeth. The papillae form a "U" shape cervical to the contact area of each tooth.

Root Apex. The root apex is the tip of the root. In most instances, the root tip of an anterior tooth has a distal inclination. The exception is the mandibular canine, which frequently has a mesially inclined root tip.

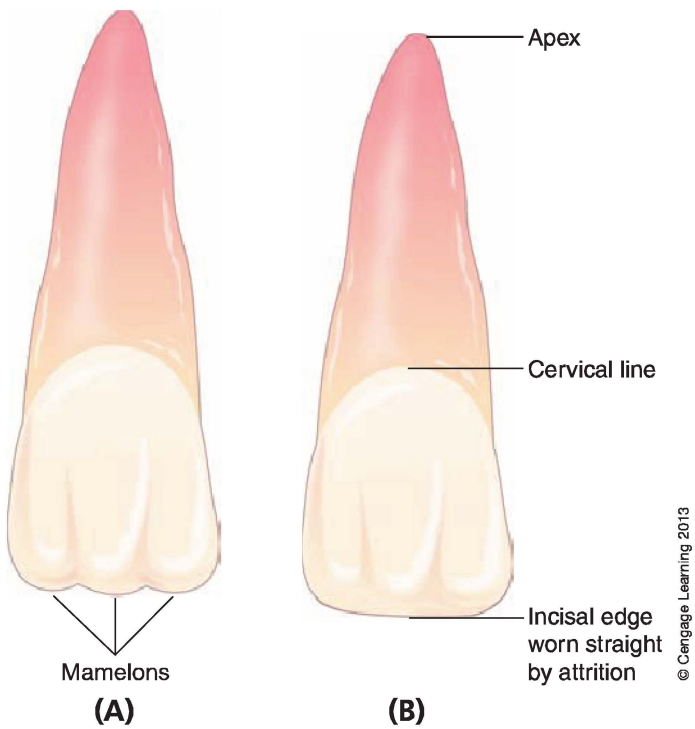

Figure II–2. Maxillary right central incisor—labial surface.

APICAL FORAMEN

The apical forament is a tiny opening in the apex of the root of the tooth through which blood vessels and nerves exit and enter.

Pulp Canal. The pulp canal is a structure containing the pulp . It is located in the root of the tooth. All anterior teeth have one root and one pulp canal.

Antagonist. An antagonist is a tooth that contacts another tooth in the opposite arch. Mandibular teeth contact maxillary teeth; they are the antagonists of each other. All anterior teeth have two antagonists *except* the mandibular central incisors, which have only one (**Figure II–3**).

Succedaneous Tooth. A succedaneous tooth is a permanent tooth that replaces, or succeeds, a primary tooth in the same position. Each permanent anterior tooth succeeds a primary anterior tooth; for example, the permanent maxillary central incisor succeeds the primary maxillary central incisor (**Figure II–4**). The permanent incisor is the succedaneous tooth.

© Cengage Learning 2013

Figure II–3. All anterior teeth have two antagonists except the manidbular central incisor.

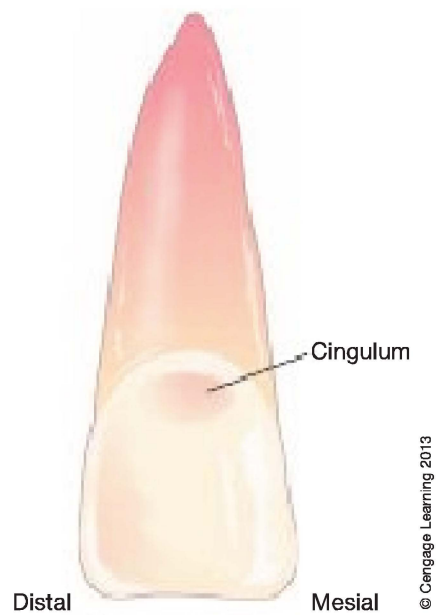

© Cengage Learning 2013

Figure II–4. Maxillary central incisor—lingual view.

STRUCTURES COMMON TO ALL ANTERIOR TEETH

Fossa. A fossa is a shallow, rounded depression.

Ridge. A ridge is a linear elevation. Ridges are named by their location—for example, the mesial marginal ridge or lingual ridge.

Cingulum. A cingulum is a convex, or rounded, elevation or tubercle on the cervical third of the lingual surface. This is a remnant of the fourth, or lingual, lobe.

Root Depression or Furrow. A root depression or furrow is a shallow, linear concavity located on either the crown or root.

Pit. A pit is a pinpoint depression.

CHAPTER 5

Maxillary Incisors

General Information
Maxillary Central Incisor Description
Maxillary Lateral Incisor Description

Objectives

At the completion of this chapter, you will be able to:

- Identify the maxillary incisors and provide information including universal number, function, antagonist, and other features.
- Describe the location and contour of each maxillary incisor.
- Define the new terms in the chapter.
- Complete the worksheet at the end of the chapter.

Key Terms

Anomaly
Cervical line
Cingulum
Developmental depressions
Lingual fossa
Mamelons
Marginal ridges
Pit

GENERAL INFORMATION

There are four maxillary incisors: two central and two lateral incisors. Each quadrant has one central incisor and one lateral incisor. Both the central and lateral incisors are similar in shape; however, the lateral incisor is smaller and slightly more convex. See **Figure 5–1** and **Figure 5–5** for a comparison of the maxillary incisors.

At eruption, mamelons are more prominent on the central incisor, but they are normally worn away by attrition after a short period of use. Incisors are wedge shaped from the proximal view (see **Figure 5–1**) with a straight, sharp cutting, or incisal, edge that makes them adaptable for incising food.

This text describes the "ideal" morphology of each tooth. Actual teeth will show variations, which are normal. Occasionally there is an extreme deviation from the norm. This is called an **anomaly**.

A frequent deviation of the maxillary central incisor is a variation in root length, the most common of which is a short or blunted root.

The maxillary lateral incisor is the tooth, other than third molars, that most commonly forms as an anomaly. Its most frequent variation of crown shape is the "peg-shaped" lateral.

MAXILLARY CENTRAL INCISOR DESCRIPTION

Characteristics	
Location in the arch	One on either side of midline
Universal number	R-#8 L-#9
Eruption date	7–8 years
First evidence of calcification	3–4 months
Crown completion	4–5 years
Root completion	10 years

Continues

Characteristics *continued*

Function	Biting, incising
Length of crown	10.5 mm
Length of root	13 mm
Antagonists	Mandibular central and lateral incisors
Location of Contact Area	
Mesial	Mesioincisal angle
Distal	Slightly cervical to distoincisal angle

Identifying Features

- Widest anterior tooth mesiodistally
- Straight mesial side with sharp mesioincisal angle and convex distal side
- Straight incisal edge
- Wedge shape of tooth from proximal view
- Refer to **Figure 5–1**.

Labial Surface

After the **mamelons** are worn away, the incisal edge is straight, slightly inclining toward the distal side of the tooth. The mesioincisal angle is sharp, contacting the mesial of the adjacent central incisor at the incisal edge. Tapering gradually, the mesial side continues straight until it merges with the cervical line. The distoincisal angle, slightly rounded, forms the distal contact area in the incisal third. The distal side of the tooth is slightly convex, tapering until it joins the cervical line, a semicircle. Two slight vertical **developmental depressions**, the result of lobe formation, are present on the labial surface; otherwise it is smooth. A cone-shaped root tapers gradually to a blunt apex (**Figure 5–2**).

Lingual Surface

The outline of the lingual surface is the reverse of the labial view. A well-defined **lingual fossa** is outlined by mesial and distal **marginal ridges** and the **cingulum** (**Figure 5–3**). Frequently, shallow grooves are found in the fossa. A pronounced cingulum dominates the cervical third of the crown.

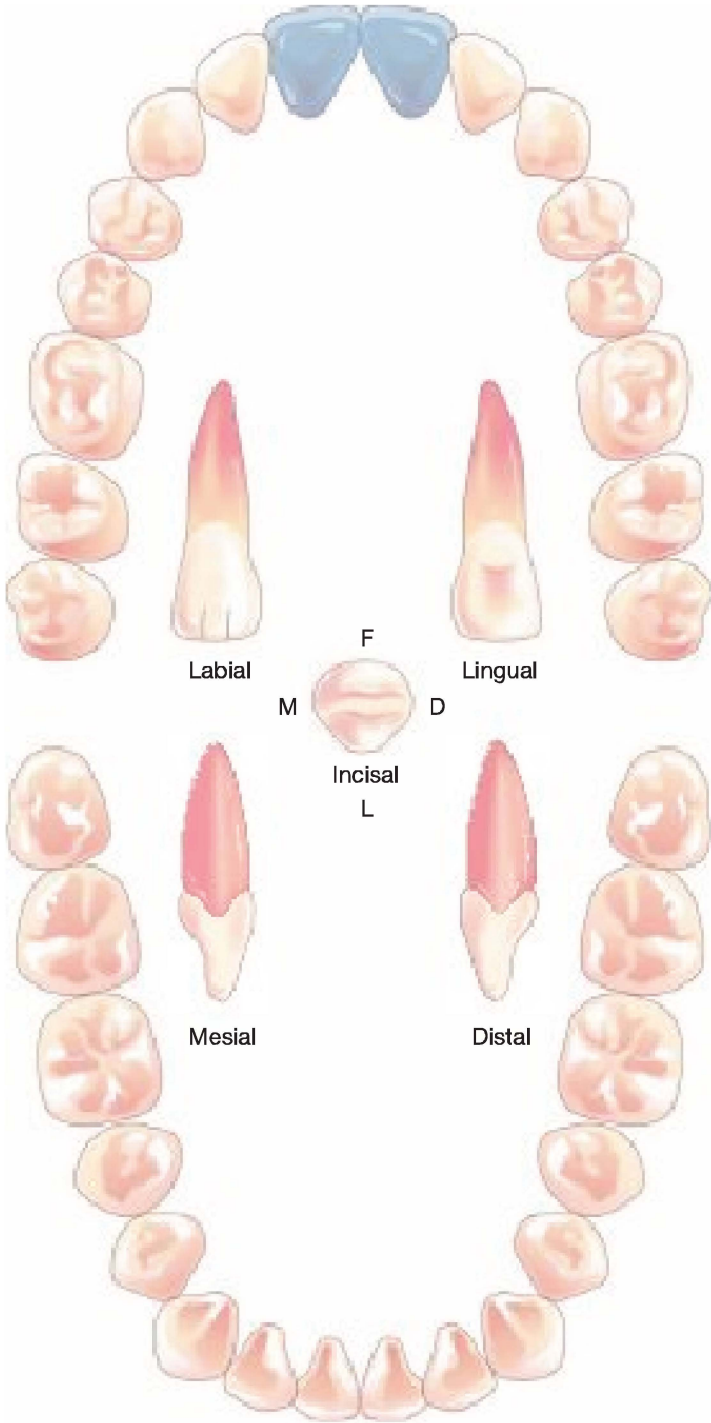

© Cengage Learning 2013

Figure 5–1. Maxillary central incisors.

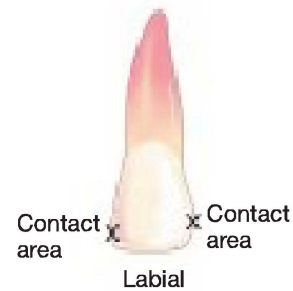

© Cengage Learning 2013

Figure 5–2. Maxillary central incisor—labial surface.

© Cengage Learning 2013

Figure 5–3. Maxillary central incisor.

Proximal Surfaces

Seen from this view is a typical wedge shape that renders the tooth adaptable for biting and incising food. Note that the **cervical line** curves incisally for about one-third the length of the crown (**Figure 5–4**).

The root is broad and smooth (with no depressions or furrows) and tapers, in the apical third, to a blunt apex. The tip of the root and the incisal edge are on the midline, providing balance for the tooth when functioning.

Clinical Considerations

Root length: 13 mm

Root depressions/furrows: None

CEJ: Curves incisally 2.5–3.5 mm

Cervical area: Smooth

© Cengage Learning 2013

Figure 5–4. Maxillary central incisor—mesial and distal surfaces

Summary of the Maxillary Central Incisor

LABIAL SURFACE

The characteristics of this surface are as follows:

- A straight incisal edge, slightly inclined toward distal
- A straight mesial side
- A sharp mesioincisal angle
- A mesial contact area (X) located at the mesioincisal angle
- A slightly convex distal side
- A rounded distoincisal angle
- A distal contact area (X) located in the incisal third
- Developmental depressions on the crown
- A cone-shaped root with a blunt apex

LINGUAL SURFACE

The characteristics of this surface are as follows:

- An outline that is the reverse of the labial
- A concave lingual fossa
- Mesial and distal marginal ridges that outline the fossa
- A convex cingulum that comprises the cervical third of the crown

PROXIMAL SURFACES

The characteristics of these surfaces are as follows:

- A cervical line that curves one-third of the tooth toward the incisal (3 mm on mesial, 2 mm on the distal)
- The tip of the incisal edge and the root located on the midline
- A root that is broad and tapers in the apical third
- No furrows or depressions on the root

MAXILLARY LATERAL INCISOR DESCRIPTION

Characteristics

Location in the arch	Distal to central incisor; second tooth from midline
Universal number	R-#7 L-#10
Eruption date	8–9 years
First evidence of calcification	1 year
Crown completion	4–5 years
Root completion	11 years
Function	Biting, incising
Length of crown	9 mm
Length of root	13 mm
Antagonists	Mandibular lateral incisor and canine
Location of Contact Area	
Mesial	Junction of middle and incisal third
Distal	Middle third

Identifying Features

- Resembles maxillary central incisor but is smaller, with more convex mesial and distal sides and incisal angles
- Developmental variations are frequent
- Refer to **Figure 5–5**.

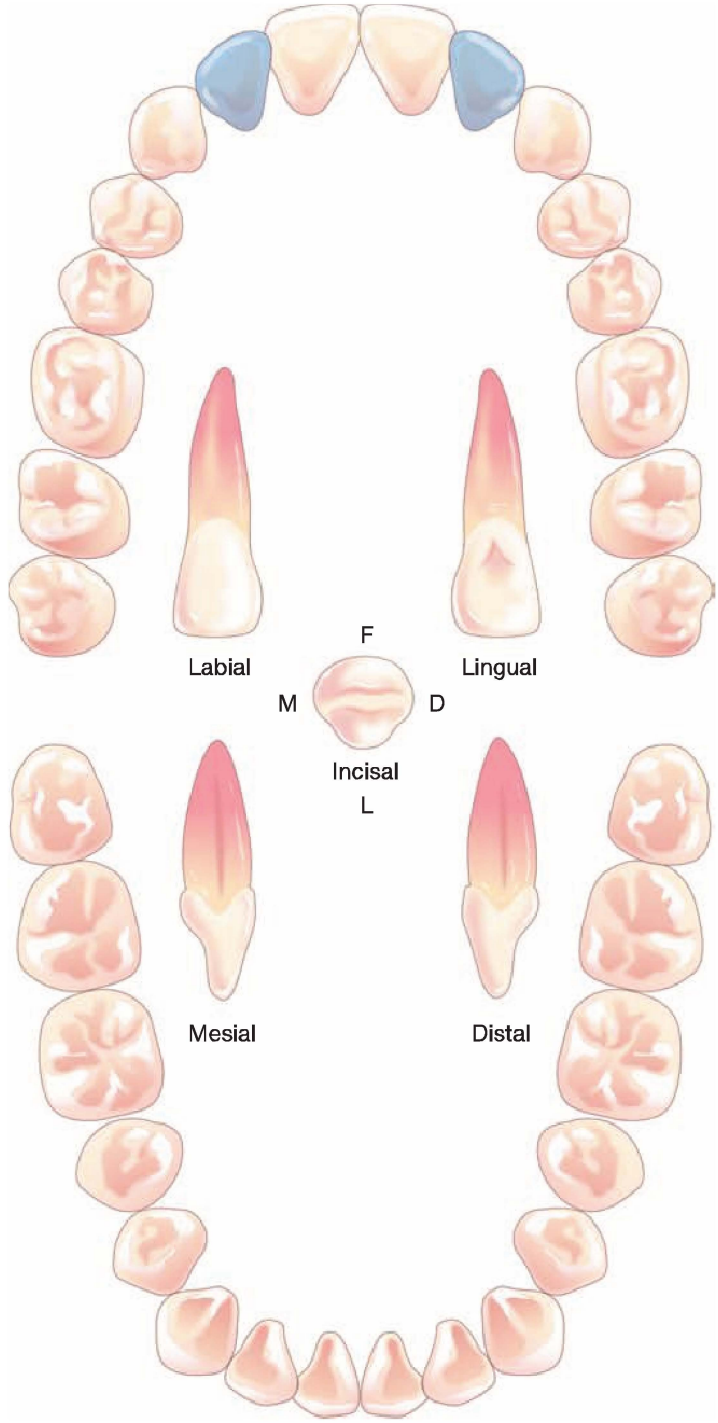

© Cengage Learning 2013

Figure 5–5. Maxillary lateral incisors.

Labial Surface

The lateral incisor has the same shape as the central incisor but is smaller and slightly more convex (**Figure 5–6**). The incisal edge inclines toward the distal. Both the mesial and distal incisal angles are rounded, and both the mesial and distal sides of the tooth are convex. As compared to the mesial, the distal outline is more convex and the angle more rounded. Although developmental depressions may be present, the labial surface is usually smooth. Both mesial and distal contact areas are located more cervically than on the central incisor. A cone-shaped root tapers, gradually, toward the apex.

© Cengage Learning 2013

Figure 5–6. Maxillary lateral incisor—labial surface.

Lingual Surface

The lingual outline is the reverse of the labial (**Figure 5–7**). However, the cingulum is very pronounced, and a developmental **pit** is often located in the fossa directly beneath it. The lingual fossa is more likely to have developmental grooves than the maxillary central incisor. All other structures are the same as those of the central incisor.

© Cengage Learning 2013

Figure 5–7. Maxillary lateral incisor—lingual surface.

Proximal Surfaces

The structures and shape, from this view, are the same as the maxillary central incisor. However, there is often a furrow, or long, shallow depression, present on the root (**Figure 5–8**).

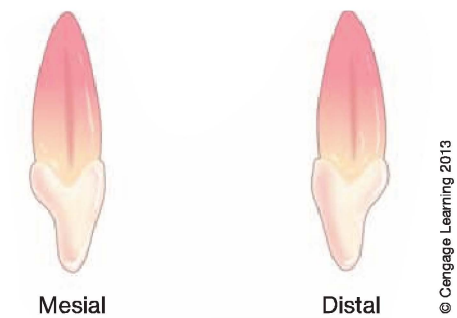

© Cengage Learning 2013

Figure 5–8. Maxillary lateral incisor—lingual surface.

Clinical Considerations

Root length: 13 mm

Root depressions/furrows: Mesial and distal vertical depressions usually present

CEJ: Curves incisally 2–3 mm

Cervical area: May have shallow concavity

Summary Of The Maxillary Lateral Incisor

LABIAL SURFACE

The characteristics of this surface are:

- A straight incisal edge that inclines toward the distal
- Rounded mesial and distal incisal angles
- Convex mesial and distal sides
- Mesial and distal contact areas that are more cervical than the central incisor
- A smooth labial surface
- A tapered root

LINGUAL SURFACE

The characteristics of this surface are:

- A prominent cingulum
- A developmental pit usually in the fossa below the cingulum

PROXIMAL SURFACES

The characteristics of these surfaces are:

- A wedged-shaped outline that is the same as the maxillary central incisor
- A cervical line that curves one-third of the tooth toward the incisal
- A broad root with furrows on both the mesial and distal surfaces

SUMMARY

Incisors are wedge-shaped teeth with sharp, straight incisal edges used to cut or incise food. Both the maxillary central and lateral incisors have similar shapes, although the lateral incisor is smaller and slightly more convex.

Complete the following chart with the information requested

	Central Incisor	Lateral Incisor
Universal Number		
Palmer's Notation		
Eruption Date		
Antagonists		
Anomalies		
Location of Contact Area		
Mesial		
Distal		
Succedaneous		
Number of Lobes		
*Labial Depressions**		
*Lingual**		
Ridges		
Cingulum		
Fossa		
Root Shape and Depressions		
Labial		
Proximal		

*Indicate location, size, and/or shape

Answer the following multiple-choice questions

1. The incisor most likely to be an anomaly is:

a. maxillary central incisor

b. maxillary lateral incisor

2. The maxillary lateral incisor differs from the maxillary central incisor by:

a. more rounded incisal angles

b. a pit on the lingual fossa

c. more convex mesial and distal sides

d. all of the above

3. The eruption date for the maxillary lateral is:

a. 6–7 years

b. 7–8 years

c. 8–9 years

d. 9–10 years

4. The total number of years for complete formation of an incisors is about:

a. 2–3 years

b. 5–6 years

c. 8–9 years

d. 10 years

5. The mesial surface of the maxillary right central contacts the:

a. distal surface of the maxillary right lateral

b. distal surface of the maxillary left central

c. mesial surface of the maxillary left central

d. distal surface of the maxillary left lateral

CHAPTER 6

Mandibular Incisors

- General Information
- Mandibular Central Incisor Description
- Mandibular Lateral Incisor Description

Objectives

At the completion of this chapter, you will be able to:

- Identify the mandibular incisors and provide information including the universal number, function, antagonist, and other characteristics.
- Describe the location and contour of each mandibular incisor.
- Define the new terms in the chapter.
- Complete the worksheet at the end of the chapter.

Key Terms

Antagonist

Bilaterally symmetric

Fossa

GENERAL INFORMATION

There are four mandibular incisors: two central incisors and two lateral incisors. Each quadrant has one central and one lateral incisor.

The central and lateral incisors appear quite similar, although the lateral incisor is larger. The opposite situation exists in the maxilla, where the central is larger than the lateral incisor.

As the smallest tooth in the dentition, the mandibular central incisor has only one **antagonist** (**Figure 6–1**). This tooth and the maxillary third molar are the only teeth that have one antagonist; all others have two.

Shortly after eruption, mamelons are usually worn away by attrition and the incisal edges of all incisors are straight. Viewed from the proximal surface, the mandibular incisors have the same wedge shape as the maxillary incisors, and so are suited, also, for incising food.

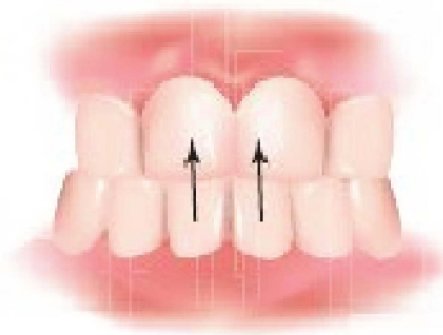

© Cengage Learning 2013

Figure 6–1. The mandibular central incisor has only one antagonist.

MANDIBULAR CENTRAL INCISOR DESCRIPTION

Characteristics	
Location in the arch	One, on either side of the midline
Universal number	R-#25 L-#24

Continues

Characteristics *continued*

Eruption date	6–7 years
First evidence of calcification	3–4 months
Crown completion	4–5 years
Root completion	9 years
Function	Incising, biting
Length of crown	9 mm
Length of root	12.5 mm
Antagonist	Maxillary central incisor
Location of Contact Area	
Mesial	Mesial incisal angle
Distal	Distal incisal angle

Identifying Features

- Smallest tooth in the oral cavity
- Bilaterally symmetric from labial or lingual view
- Smooth tooth; no developmental grooves or depression in crown
- Only one antagonist (**Figure 6–2**).

Labial Surface

The incisal edge is straight, joining the mesial and distal sides at sharp incisal angles. These angles are the contact areas. Both mesial and distal sides are straight, tapering evenly to the cervix where the cervical line forms an arc. See **Figure 6–3**.

The tooth is **bilaterally symmetric**—the same on both sides—so it is difficult to differentiate the mesial from the distal side. The root is straight, tapering gradually to the apex.

Lingual Surface

The outline from the lingual is the reverse of the labial view. This surface is very smooth; there are no pits or grooves and the **fossa** and cingulum merge with a gentle curve. Marginal ridges are not evident, unlike the maxillary incisors. The cingulum covers the cervical third of the crown; the smooth, shallow fossa occupies the remaining two-thirds.

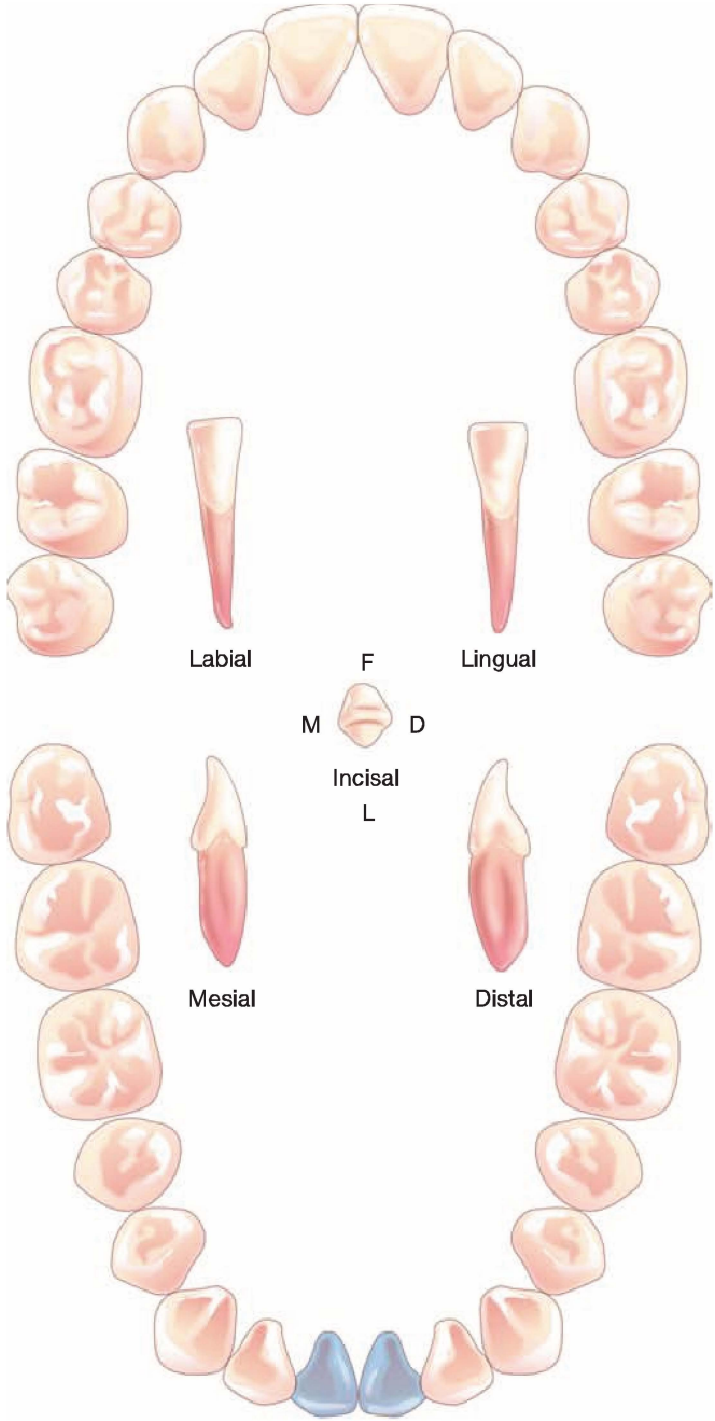

© Cengage Learning 2013

Figure 6–2. Mandibular central incisors.

© Cengage Learning 2013

Figure 6–3. Mandibular central incisor—labial surface.

Proximal Surfaces

The width, from labial to lingual, is broad to compensate for the narrow mesial to distal measurements seen from the labial view. The width is necessary to provide stability, in the bone, for such a small tooth. The root remains broad for two-thirds its length, tapering only at the apical third. Both the mesial and distal root surfaces have a deep depression extending most of the root length.

The incisal edge of the mandibular incisor is positioned lingual to the midline. When the teeth occlude, the labial surface of the mandibular incisors conforms to the lingual fossa of the maxillary incisors (**Figure 6–4**).

Incisal View

Observing this tooth from the incisal aspect assists in differentiating it from the mandibular lateral incisor. The central incisor has a straight incisal edge that is bilaterally symmetric (**Figure 6–5**). Usually, it is difficult to distinguish the mesial side from the distal side of the crown because of their similarity in structure.

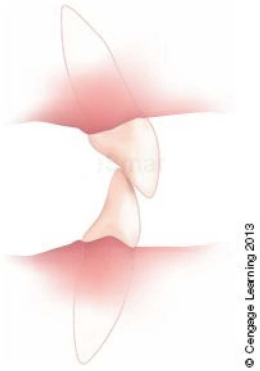

Figure 6–4. Mandibular incisors—incisal view.

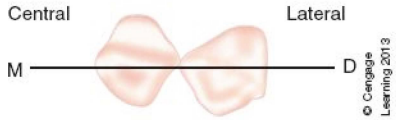

Figure 6–5. Mandibular right incisors—proximal surface.

Clinical Considerations

Root length: 12.5 mm

Root depressions/furrows: Deep vertical depressions on both mesial and distal surfaces

CEJ: Curves incisally 2–3 mm

Cervical area: May have shallow concavity on both mesial and distal surfaces

© CourseSmart

Summary of the Mandibular Central Incisor

LABIAL SURFACE

The characteristics of this surface are:

- A straight incisal edge with sharp incisal angles
- Mesial and distal sides that taper evenly to the cervix
- Mesial and distal contact areas located at the incisal angle
- A smooth crown surface with no depressions
- A straight root, tapering at the apical third

LINGUAL SURFACE

The characteristics of this surface are:

- An outline that is the reverse of the labial view
- A smooth fossa; a smooth cingulum
- A convex cingulum that is one-third of the crown

PROXIMAL SURFACES

The characteristics of these surfaces are:

- The tip of the incisal edge sitting lingual to the midline
- A cervical line that curves toward the incisal edge
- A broad root, tapering at the apical third
- A root furrow or depression on the mesial and distal surfaces

INCISAL VIEW

The characteristics of this surface are:

- A straight incisal ridge
- A bilaterally symmetric form

MANDIBULAR LATERAL INCISOR DESCRIPTION

Characteristics	
Location in the arch	Distal to central incisor; second tooth from midline
Universal number	R-#26 L-#23

Continues

Characteristics *continued*

Eruption date	7–8 years
First evidence of calcification	3–4 months
Crown completion	4–5 years
Root completion	10 years
Function	Biting, incising
Length of crown	9.5 mm
Length of root	14 mm
Antagonists	Maxillary central and lateral incisors
Location of Contact Area	
Mesial	Mesial incisal angle
Distal	Cervical to the incisal angle

Identifying Features

- Slightly larger than the central incisor
- Slightly more convex than the central incisor
- Incisal ridge curves to the distal
- Crown distally displaced
- Refer to **Figure 6–6**.

Labial Surface

The lateral incisor looks like the central incisor in overall appearance but is slightly larger and not bilaterally symmetric. Whereas the central incisor has a level incisal edge, the incisal edge of the lateral declines toward the distal and forms a rounded incisal angle with the distal side. The distal side is slightly convex. The mesial incisal angle is sharp; the mesial side can be straight or slightly convex as it tapers toward the cervical line. Both the mesial and distal contact areas are at the incisal angle. The cervical line forms a narrow arch. The root is straight, tapering at the apical third.

Lingual and Proximal Surfaces

Except for size and length, the mandibular lateral incisor is similar to the central incisor and has the same characteristics. However, the cingulum is distally displaced as it starts to curve toward the canine. See **Figure 6–7**.

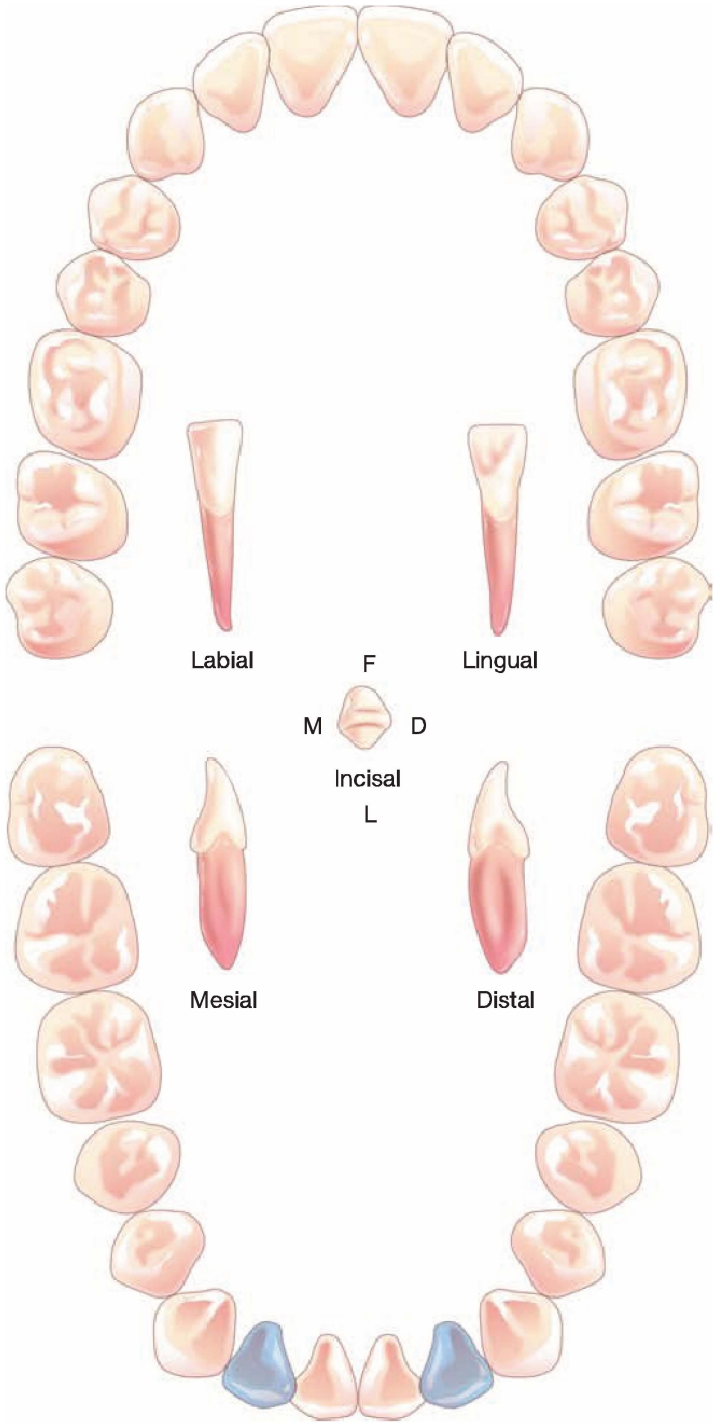

© Cengage Learning 2013

Figure 6–6. Mandibular lateral incisors.

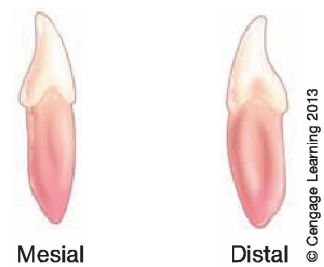

© Cengage Learning 2013

Figure 6–7. Mandibular lateral incisor—mesial and distal surface.

Incisal View

The incisal edge of the lateral incisor curves toward the distal, following the contour of the mandibular arch, whereas the incisal edge of the central incisor is straight. The curvature on the lateral incisor creates a distally displaced cingulum as compared to the centrally situated cingulum of the central incisor. This structure assists in distinguishing the two teeth from each other, and is shown in **Figure 6–4**.

Clinical Considerations

Root length: 14 mm

Root depressions/furrows: Both mesial and distal with deeper distal depression

CEJ: Curves incisally 2–3 mm

Cervical area: May have shallow concavity

Summary of the Mandibular Lateral Incisor

LABIAL SURFACE

The characteristics of this surface are:

- An incisal edge that declines toward the distal
- A mesial surface that tapers gradually toward the cervix
- A distal side that is slightly convex, tapering toward the cervix
- A sharp mesial incisal angle; a rounded distal incisal angle
- Mesial and distal contact areas at the junction of the incisal edge and the mesial or distal side
- A smooth surface
- A straight root that tapers evenly

LINGUAL SURFACE

The characteristics of this surface are:

- An outline that is the reverse of the labial side
- Cingulum, fossa, and ridges that appear the same as those on the central incisor

PROXIMAL SURFACES

The characteristics of these surfaces are:

- Root depressions on the mesial and distal surfaces; the distal depression is deeper
- All other characteristics that are the same as those pertaining to the central incisor

INCISAL VIEW

The characteristics of this view are:

- An incisal edge that curves toward the distal and inward toward the lingual
- A cingulum that is distally displaced

SUMMARY

Mandibular incisors assist the maxillary incisors in biting and cutting food. From the labial view, both mandibular incisors are small, narrow teeth with a straight incisal edge and tapering mesial and distal sides. The mandibular central incisor is the smallest tooth in the dentition.

Complete the following chart with the information requested

	Central Incisor	Lateral Incisor
Universal Number		
Palmer's Notation		
Eruption Date		
Antagonists		
Anomalies		
Location of Contact Area		
Mesial		
Distal		
Succedaneous		
Number of Lobes		
*Labial Depressions**		
*Lingual**		
Ridges		
Cingulum		
Fossa		
Root Shape and Depressions		
Labial		
Proximal		

*Indicate location, size, and/or shape

Answer the following multiple-choice questions

1. When viewing the mandibular lateral incisor from the labial, it would differ from the mandibular central incisor by a:

a. more rounded distal incisal angle

b. more prominent labial ridge

c. less curved cervical line

d. shorter crown

2. The contact area for the mandibular incisors is located:
- **a.** in the apical third
- **b.** in the middle third
- **c.** at the incisal edge

3. When viewing the mandibular central incisor from the incisal view, the crown is:
- **a.** centered to the mesial
- **b.** centered to the distal
- **c.** bilaterally symmetric

4. The antagonist(s) for the mandibular central incisors is(are):
- **a.** the maxillary central and lateral incisors
- **b.** the maxillary incisors
- **c.** the maxillary lateral incisor and canine

5. Which is the first incisor to erupt?
- **a.** maxillary central
- **b.** maxillary lateral
- **c.** mandibular central
- **d.** mandibular lateral

CHAPTER 7

Canines

- General Information
- Maxillary Canine Description
- Mandibular Canine Description

Objectives

At the completion of this chapter, you will be able to:

- Identify the canines and provide information including universal number, function, antagonist, and other characteristics.
- Describe the location and contour of each canine.
- Define the new terms in the chapter.
- Complete the worksheet at the end of the chapter.

Key Terms

Aesthetics
Cornerstone
Cusp slope
Cuspids
Labial ridge
Lingual fossa
Lingual ridge

GENERAL INFORMATION

There are two canines in each arch: one in each quadrant. Maxillary and mandibular canines are similar, with variations as noted in the descriptions. Both maxillary and mandibular canines have a sharp, pointed cusp, thus attaining their alternate name of "**cuspids**." They are long, strong, stable teeth. Note their size and length (**Figure 7–1**) as compared to the adjacent teeth. Canines usually have one root. However, with variation, the mandibular canine may have two roots, and thus two pulp canals.

Because they are located at the corner of each arch, canines are referred to as the "**cornerstone**" teeth. Their position is important to **aesthetics** because they provide shape to the face. If dentures are needed and the size or position of the canine is varied, the entire facial appearance can change. Fortunately, canines are self-cleansing, because of their convexity and location at the corners of the arch, so that food easily rolls off them. Thus, they are usually the last teeth to be lost by dental decay. The shape of this tooth, particularly the sharp cusp, makes it adaptable for holding and tearing food.

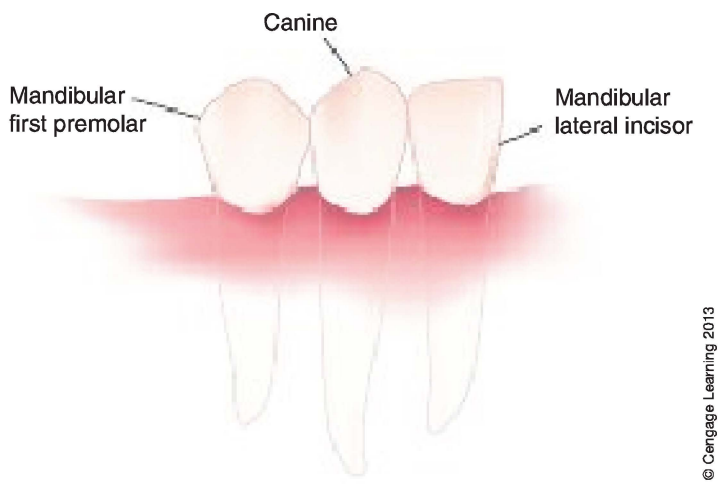

Figure 7–1. Mandibular canine with proximal teeth.

MAXILLARY CANINE DESCRIPTION

Characteristics

Location in the arch	Distal to lateral incisor; third tooth from midline
Universal number	R-#6 L-#11
Eruption date	11–12 years
First evidence of calcification	4–5 months
Crown completion	6–7 years
Root completion	13–15 years
Function	Tearing, holding
Length of crown	10 mm
Length of root	17 mm
Antagonist	Mandibular canine and first premolar

Location of Contact Area

Mesial	Junction of incisal and middle third
Distal	Middle third

Identifying Features

- Longest maxillary tooth
- Stable, sturdy tooth
- Cornerstone of the arch
- Sharp, pointed cusp
- Bulky cingulum and defined lingual ridges
- Refer to **Figure 7–2**.

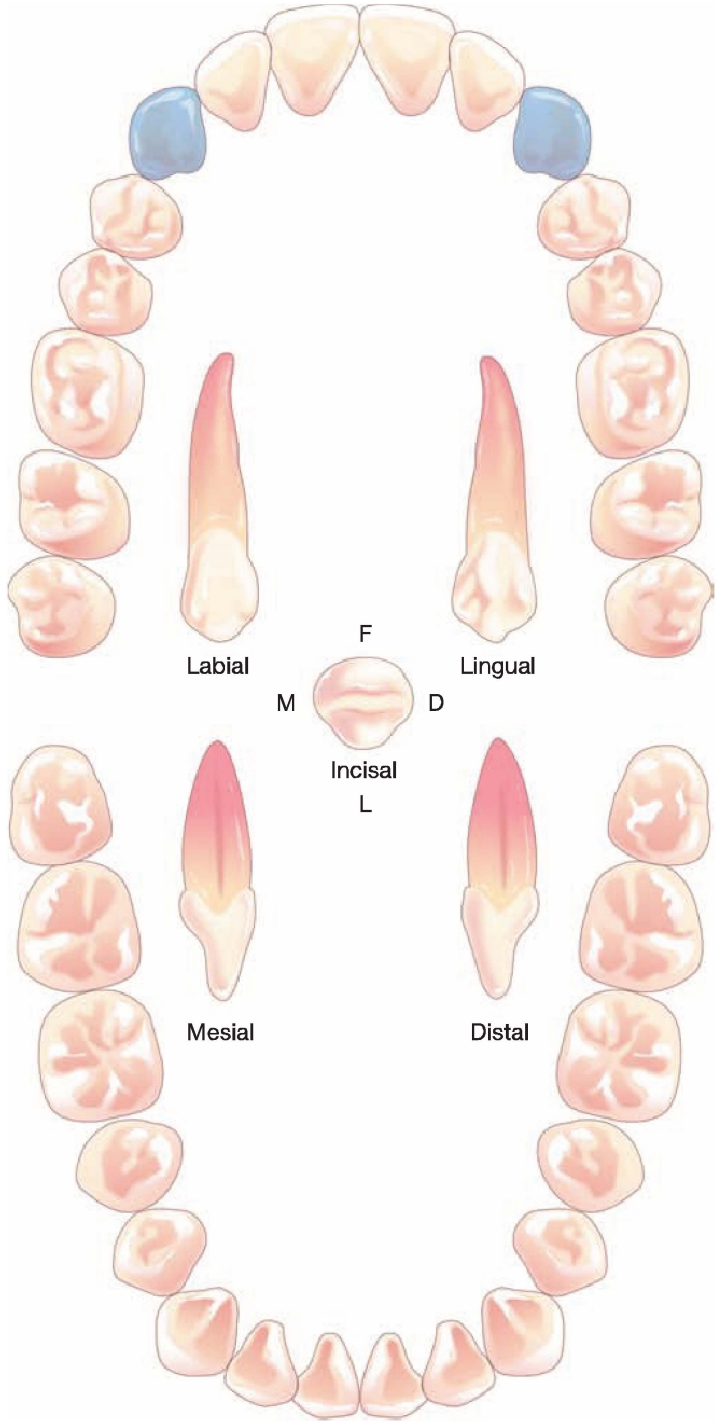

© Cengage Learning 2013

Figure 7–2. Maxillary canines.

Labial Surface

The area extending from the tip of the cusp to both the mesial and distal contact areas is called a **cusp slope**. Both contact areas are located near the junction of the incisal and middle third of the tooth. The mesial cusp slope is shorter than the distal cusp slope. It joins the mesial surface at the junction of the incisal and middle third; the mesial side is convex. Because of the longer cusp slope, the distal contact area is more cervical than the mesial and is located in the middle third of the crown. The distal side of the tooth is slightly concave before merging with the cervical line.

A well-developed middle lobe, called the **labial ridge**, is centrally located and extends from the cervix to the tip of the cusp. Shallow depressions extend, vertically, along both sides of the ridge. The root is cone shaped and usually smooth. See **Figure 7–3**.

© Cengage Learning 2013

Figure 7–3. Maxillary canine—labial surface.

Lingual Surface

The outline is the reverse of the labial view, but narrower. Forming the lingual surface are two fossae and a well-pronounced cingulum. The cingulum is situated in the cervical third of the crown. A **lingual ridge** divides the **lingual fossa** into two segments—a mesial lingual fossa and a distal lingual fossa—and extends from the base of the cingulum to the cusp tip. Raised mesial and distal marginal ridges outline the lateral border of the fossae, as shown in **Figure 7–4**.

© Cengage Learning 2013

Figure 7–4. Maxillary canine—lingual surface.

Proximal Surfaces

Both the length and width of the maxillary canine, as seen from the proximal surfaces, are greater than other anterior teeth. This width is needed to give the tooth stability. The root is broad for two-thirds its length, tapering only at the apical third. Deep depressions on the mesial and distal root surfaces give the tooth greater stability in the bone, needed during mastication, as illustrated in **Figure 7–5**.

© Cengage Learning 2013

Figure 7–5. Maxillary canine—mesial and distal surface.

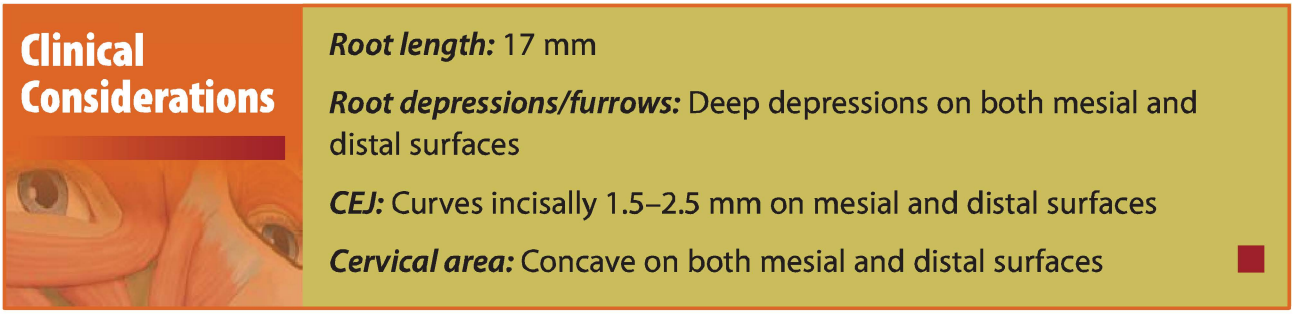

Summary of the Maxillary Canine

LABIAL SURFACE

The characteristics of this surface are:

- A mesial cusp slope that is shorter than the distal cusp slope
- A mesial contact area that is at the junction of the incisal and the middle third
- A distal contact area that is in the middle third of the tooth
- A slightly convex mesial side
- Slightly concave from cervix to contact area on distal side
- A well-developed middle lobe, called the *labial ridge*
- Depressions that are on either side of the labial ridge
- A cusp tip that is centered over the root
- A cone-shaped, smooth root

LINGUAL SURFACE

The characteristics of this surface are:

- An outline that is the reverse of the labial view
- A crown and root that converge so that both mesial and distal surfaces can be seen
- A fossa that is divided, by a lingual ridge, into mesiolingual and distolingual fossae
- A pronounced cingulum and marginal ridges

PROXIMAL SURFACES

The characteristics of these surfaces are:

- A broad crown and root
- A cervical line that curves toward the incisal
- A deep depression in the root surface

MANDIBULAR CANINE DESCRIPTION

Characteristics	
Location in the arch	Distal to lateral incisor; third tooth from midline
Universal number	R-#27 L-#22
Eruption date	9–10 years
First evidence of calcification	4–5 months
Crown completion	6–7 years
Root completion	12–14 years
Function	Tearing, holding
Length of crown	11 mm
Length of root	16 mm
Antagonists	Maxillary lateral incisor and canine
Location of Contact Area	
Mesial	Incisal third
Distal	Junction of incisal and middle third

Identifying Features

- Longest mandibular tooth
- Well-developed middle lobe called the *labial ridge*
- Slightly narrower and smoother than maxillary canine
- Refer to **Figure 7–6**.

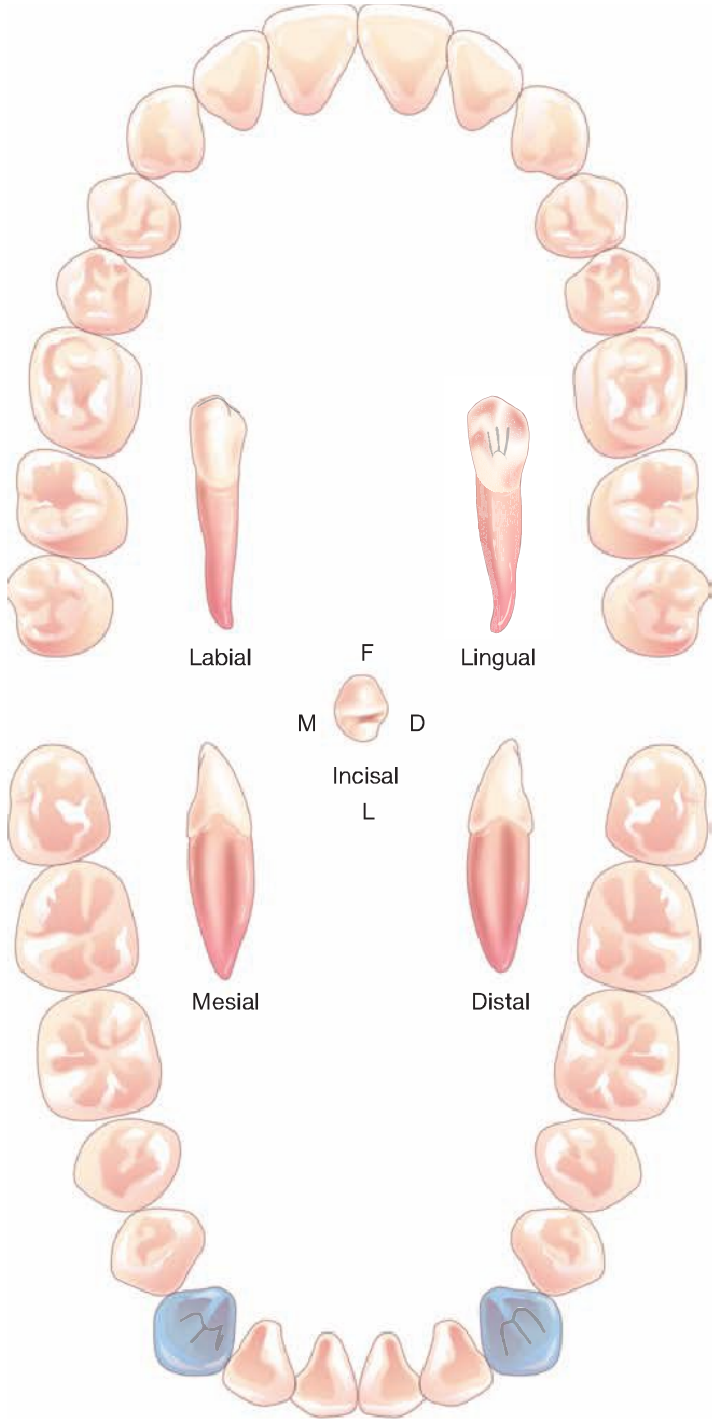

© Cengage Learning 2013

Figure 7–6. Mandibular canines.

Labial Surface

The crown of the mandibular canine looks similar to that of the maxillary canine but is narrower by 0.5 mm. It appears even narrower than this, as compared to the maxillary canine, because both the mesial and distal contact areas are located more incisally.

The mesial cusp slope is shorter than the distal; the mesial side of the tooth is straight, whereas the distal side is more convex. The labial ridge is not as prominent as on the maxillary canine, and there are depressions on either side of the ridge. The root tapers gradually, and the root tip frequently has a mesial inclination. See **Figure 7–7**.

© Cengage Learning 2013

Figure 7–7. Mandibular canine—labial surface.

Lingual Surface

The outline is the reverse of the labial view, but narrower, because the lingual converges. The structures are the same as those on the maxillary canine, but less pronounced, as shown in **Figure 7–8**.

© Cengage Learning 2013

Figure 7–8. Mandibular canine—lingual surface.

Proximal Surfaces

Again, the tooth is broad from this view, with an overall shape resembling that of the maxillary canine. There are deep depressions on both the mesial and distal root surfaces, as illustrated in **Figure 7–9**.

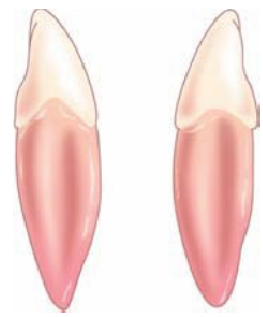

© Cengage Learning 2013

Figure 7–9. Mandibular canine—mesial and distal surface.

Summary of the Mandibular Canine

LABIAL SURFACE

The characteristics of this surface are:

- A mesial cusp slope that is shorter than the distal
- Contact areas that are more incisal than on the maxillary canine
- A straight mesial side
- A slightly convex distal side
- A tapered root

Clinical Considerations

Root length: 16 mm

Root depressions/furrows: Deep depressions on both mesial and distal surfaces

CEJ: Curves incisally 1–2.5 mm on mesial and distal surfaces

Cervical area: No concavity on either mesial or distal surface

LINGUAL SURFACE

The characteristics of this surface are:

- An outline that is the reverse of the labial view, but narrower
- Cingulum and marginal ridges that are smoother than the maxillary canine
- Two fossae divided by the lingual ridge
- Fossae that are shallower than on the maxillary canine

PROXIMAL SURFACES

The characteristics of these surfaces are:

- Greater width, providing stability
- Deep depressions on the root surface

SUMMARY

Canines, along with the incisors, are considered anterior teeth. Both maxillary and mandibular canines are long, broad, pointed teeth with a sharp cusp that is used to tear food when necessary. These strong, stable teeth are located at the corners of the arch. The pronounced buccal ridge of the crown and the canine eminence of the root provide shape to the face.

Complete the following chart with the information requested

	Maxillary Canine	Mandibular Canine
Universal Number		
Palmer's Notation		
Eruption Date		
Antagonists		
Anomalies		
Location of Contact Area		
Mesial		
Distal		
Succedaneous		
Number of Lobes		
*Labial Depressions**		
*Lingual**		
Ridges		
Cingulum		
Fossa		
Root Shape and Depressions		
Labial		
Proximal		

*Indicate location, size, and/or shape

Answer the following multiple-choice questions

1. When compared to the mandibular canine, the maxillary canine:

a. is longer from incisal to cervix

b. is more irregular on the lingual

c. erupts earlier

d. is narrower mesial to distal

2. When compared to the maxillary canine, the cingulum of the mandibular canine is:

a. more irregular
b. larger
c. smoother
d. no different

3. The structures on either side of the lingual ridge of the canine are referred to as:

a. lobes
b. pits
c. grooves
d. fossae

4. How does the mesial cusp slope of the canines differ from the distal cusp slope?

a. It is shorter.
b. It is longer.
c. It is the same.

5. The antagonists of the maxillary canine are:

a. mandibular canine and first premolar
b. mandibular first and second premolar
c. mandibular lateral and first premolar
d. mandibular canine and lateral

SECTION III

Permanent Posterior Teeth

General Information

Chapter 8 Maxillary Premolars

Chapter 9 Mandibular Premolars

Chapter 10 Maxillary First and Second Molars

Chapter 11 Mandibular First and Second Molars

Chapter 12 Third Molars

GENERAL INFORMATION

At the completion of this section, you will be able to identify the location in the dental arch of each posterior tooth, as well as its universal number, expected eruption date, usual crown and root completion dates, function, lengths of crown and root, antagonists and the location of contact areas, number of lobes, and pulp canals. You will be able to state at what age there is evidence of calcification in the formation of each tooth.

You will be able to describe the location and contour of the buccal, lingual, proximal, and occlusal surfaces as they apply to each posterior tooth. Your descriptions will include contact areas, grooves, cusps, pits, ridges, fossae, outlines, contact areas, and roots of the teeth. Use Appendix C to compare the depth of the cervical lines of the teeth and to identify the location of the root depressions.

You will also be able to define terms such as **comminution**, **intercuspation**, **interdigitation**, **bifurcation**, and **marginal**, **oblique**, **transverse**, and **triangular ridges**.

To avoid redundancy in each chapter, the following descriptions consolidate information relating to posterior teeth.

Occlusal Surface

The occlusal surface is the chewing surface. All posterior teeth have a chewing surface shaped by cusps, fossae, ridges, and grooves. The lingual cusps of the maxillary teeth sit in the fossae of the mandibular teeth and the buccal cusps of the mandibular teeth sit in the fossae of the maxillary teeth (**Figure III–2**). Cusps slope toward the grooves so that the teeth interdigitate when in contact with each other.

Lobes

Lobes are centers of calcification. All teeth develop from at least four lobes. The premolars, with two cusps, develop from four lobes: three buccal and one lingual. The mandibular second premolar, which has three cusps, develops from five lobes: three buccal and two lingual. Lobe formation of molars is equal to the number of cusps on the tooth. If a molar has four cusps, it develops from four lobes (**Figure III–1**).

Pulp Canals

The pulp canals are portions of the pulp located in the root of the tooth. Each root has one pulp canal *except* the mandibular first molar; the mesial root of this tooth usually has two pulp canals.

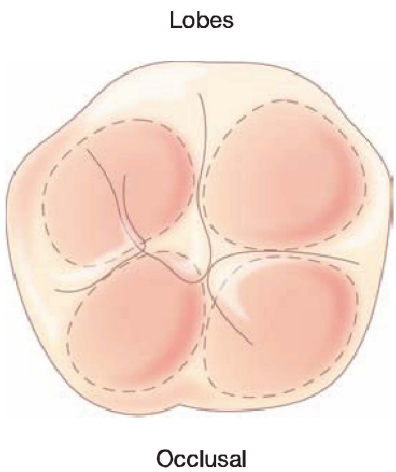

Figure III–1. The occlusal view of the maxillary molar showing the lobes and how they come together.

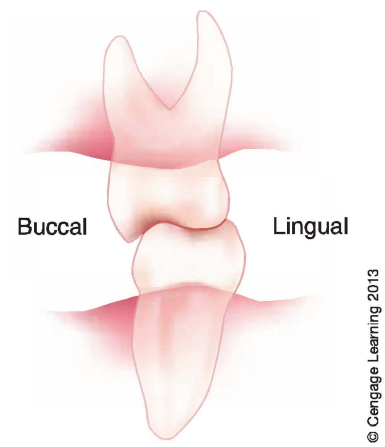

Figure III–2. Molars in occlusion—proximal view.

Pulp Horn

The pulp horn is the portion in the pulp chamber, or coronal pulp, that is elevated toward a cusp (**Figure III–3**).

Root Trunk

The root trunk is the portion of the root that extends from the cemento-enamel junction to the furcation. If the root trunk divides into two roots, it is **bifurcated**. All mandibular molars have bifurcated roots (**Figure III–4A**). All maxillary molars are **trifurcated**—that is, divided into three roots. The area on the root trunk where it separates is called the **furcation** or forking (**Figure III–4B**).

Contact Area

The contact area is the portion of the mesial or distal surface that touches, or contacts, the proximal or adjacent tooth.

Succedaneous Tooth

A succedaneous tooth is one that succeeds another tooth in the same position. Premolars are the only posterior teeth that are succedaneous. They succeed the deciduous molars. As permanent molars do not replace deciduous teeth, they are not succedaneous teeth.

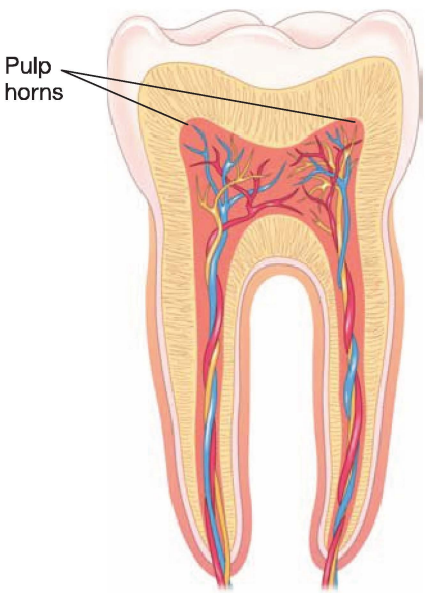

© Cengage Learning 2013

Figure III–3. Pulp horns.

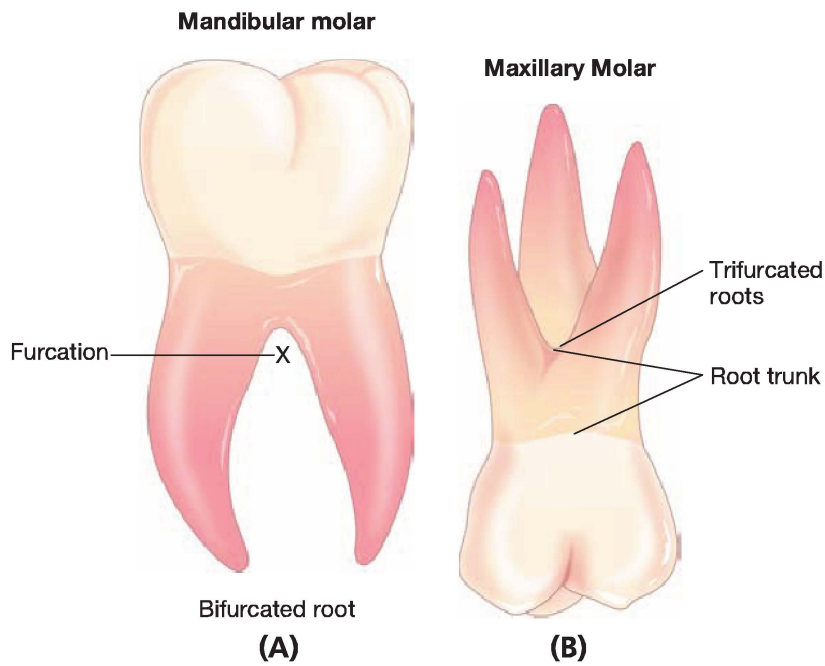

© Cengage Learning 2013

Figure III–4. Furcated roots (A) Mandibular molar. Furcated roots (B) Maxillary molar.

STRUCTURES COMMON TO ALL POSTERIOR TEETH

Ridge

A ridge is a linear elevation, named by its location or direction. There are several types:

Marginal ridge: A ridge around the perimeter of the occlusal surface (**Figure III–5**)

Transverse ridge: A ridge that crosses the occlusal surface from buccal to lingual (**Figure III–6**)

Triangular ridge: A ridge that slants from the cusp tip toward a groove and forms a triangular slope (**Figure III–7**)

Oblique ridge: A ridge that diagonally crosses the occlusal surface—for example, from mesiobuccal to distolingual (**Figure III–8**)

Cusp ridge: A ridge that slopes from the tip of the cusp toward the mesial or distal surface

Fossa

A fossa is a shallow depression named by its shape:

Circular fossa: A rounded depression

Triangular fossa: A "V"-shaped depression

Irregular fossa: A depression without definite shape

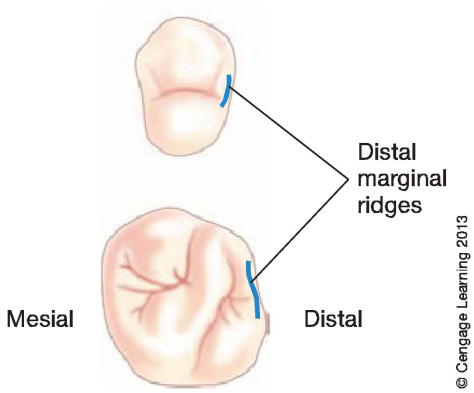

Figure III–5. The marginal ridges of the maxillary central, premolar, and molar.

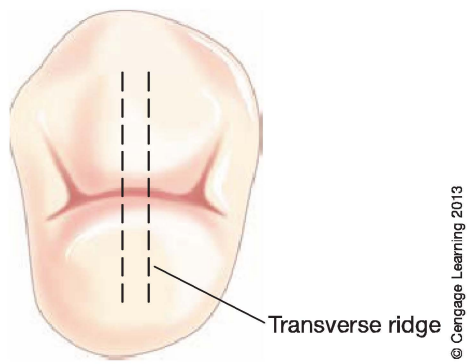

Figure III–6. The maxillary right first premolar occlusal surface showing the transverse edge.

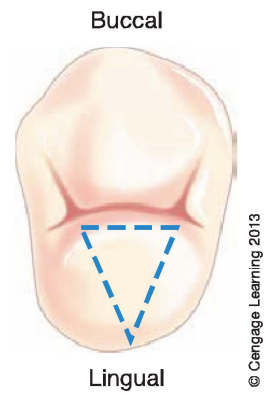

Figure III–7. Triangular ridge identified on the occlusal surface of a maxillary second premolar.

Groove

A groove is a linear depression. Each posterior tooth has a primary groove pattern unique to that tooth. These groove patterns are described in later chapters. Posterior teeth usually have additional or supplementary grooves that are not included with the descriptions or in the illustrations because of their variation in each person.

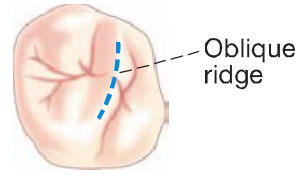

© Cengage Learning 2013

Figure III–8. A maxillary first molar with the oblique ridge identified.

Pit

A pit is a pinpoint depression where two or more grooves meet.

FACTS TO HELP AVOID CONFUSION

Premolars

Since premolars usually have two cusps, they are alternately referred to as *bicuspids*. However, the mandibular second premolar often has three cusps; therefore, these teeth are more accurately called *premolars*. All premolars have a well-developed middle buccal lobe that forms a buccal ridge ending at a pointed cusp.

Nomenclature

Cusps, grooves, fossae, and ridges are commonly named by their location, such as mesiobuccal cusp, central groove, or distal marginal ridge. With a little thought, you can probably name most of the structures without having to memorize them. Note that when the words "mesial" or "distal" are used in combination with another surface, the "al" is changed to "o" as in "mesiolingual."

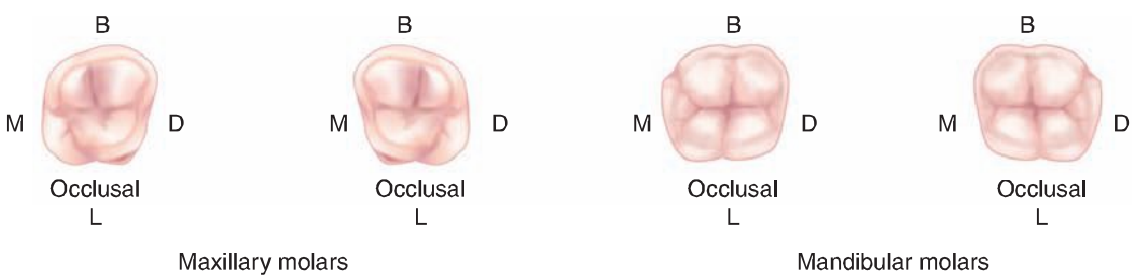

© Cengage Learning 2013

Figure III–9. Occlusal surfaces of the maxillary and mandibular molars.

Size and Shape of Surfaces

Because the mouth has less space toward the posterior region, distal surfaces of the teeth are generally smaller than mesial structures. Crowns, too, tip distally so that more of the occlusal surface can be seen when the distal side of the tooth is viewed.

Occlusal Surface

Technically, the occlusal surface is within the borders of the outer cusps and marginal ridges. Its structures are the inner cusps, grooves and pits. These structures of the occlusal surface are described in Chapters 8 through 12. (**Figure III–10**) The cusps and grooves of the maxillary teeth are arranged to contact the occlusal surfaces of the mandibular cusps and grooves so that they fit together or **interdigitate.** Because of this arrangement food can be easily chewed . Chewing is the process called **comminution**.

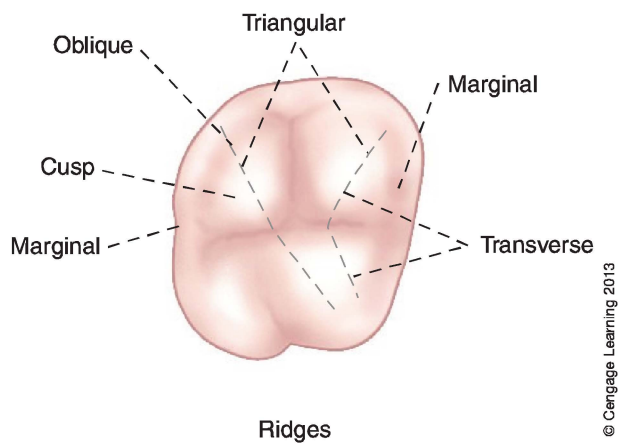

Figure III–10. Maxillary first molar—occlusal surface.

CHAPTER 8

Maxillary Premolars

- General Information
- Maxillary First Premolar Description
- Maxillary Second Premolar Description

Objectives

At the completion of this chapter, you will be able to:

- Identify the maxillary premolars and provide vital information to include universal number, function, antagonists, and other characteristics.
- Describe the location and contour of each maxillary premolar.
- Define the new terms in the chapter.
- Complete the worksheet at the end of the chapter.

Key Terms

Bifurcated
Buccal ridge
Major groove pattern
Mesial concavity
Mesial interradicular groove
Root trunk
Triangular fossa
Triangular ridge

GENERAL INFORMATION

There are four maxillary premolars: two in each quadrant. They are named by their position in the arch from anterior to posterior as first premolar and second premolar.

Maxillary premolars have one buccal and one lingual cusp. Both premolars have a prominent middle buccal lobe extending from the cervix to the tip of the buccal cusp, similar to the canine, with shallow depressions on either side.

The **root trunk** of the maxillary first premolar is **bifurcated**, dividing into two roots (buccal and lingual) that are seen only from the proximal view. The maxillary second premolar has only one root.

Viewed from the buccal, all premolars resemble one another, with their pointed buccal cusp and tapered root, so it is difficult to differentiate them. However, each has a unique structure on another surface that will assist in its identification.

Premolars replace deciduous molars; there are no deciduous premolars. The first premolar succeeds the deciduous first molar; the second premolar succeeds the deciduous second molar.

With their triangular-shaped cusps and fossae, the premolars are structured to assist with the grinding of food.

MAXILLARY FIRST PREMOLAR DESCRIPTION

Characteristics	
Location in the arch	Fourth tooth from the midline; distal to cuspid
Universal number	R-#5 L-#12
Eruption date	10–11 years
First evidence of calcification	1½ years

Continues

Characteristics *continued*

Crown completion	5–6 years
Root completion	12–13 years
Function	Grinding
Length of crown	8.5 mm
Length of root	14 mm
Antagonists	Mandibular first and second premolar

Location of Contact Area

Mesial	Middle of the tooth
Distal	Slightly more occlusal than the mesial contact

Identifying Features

- Two cusps: one buccal, one lingual
- Two roots: one buccal, one lingual
- Two pulp canals: one in each root
- Resembles canine but is shorter
- Mesial marginal groove
- Mesial concavity around CEJ
- Mesial root depression (mesial inter radicular groove) from CEJ to furcation
- Refer to **Figure 8–1**.

Buccal Surface

Only the buccal cusp and buccal root are visible, obscuring the shorter lingual cusp and root positioned directly behind them. A well-developed middle buccal lobe forms a **buccal ridge** extending from the cervix to the tip of the pointed buccal cusp (**Figure 8–2**). Shallow depressions parallel the ridge. The mesial cusp slope is longer than the distal cusp slope.

The *mesial side* is concave from the cervix to the contact area at the middle of the surface. The *distal side* is straighter than the mesial from the cervix to the contact area. The distal contact area is slightly more occlusal than the mesial, making the distal cusp slope shorter. The buccal root is tapered.

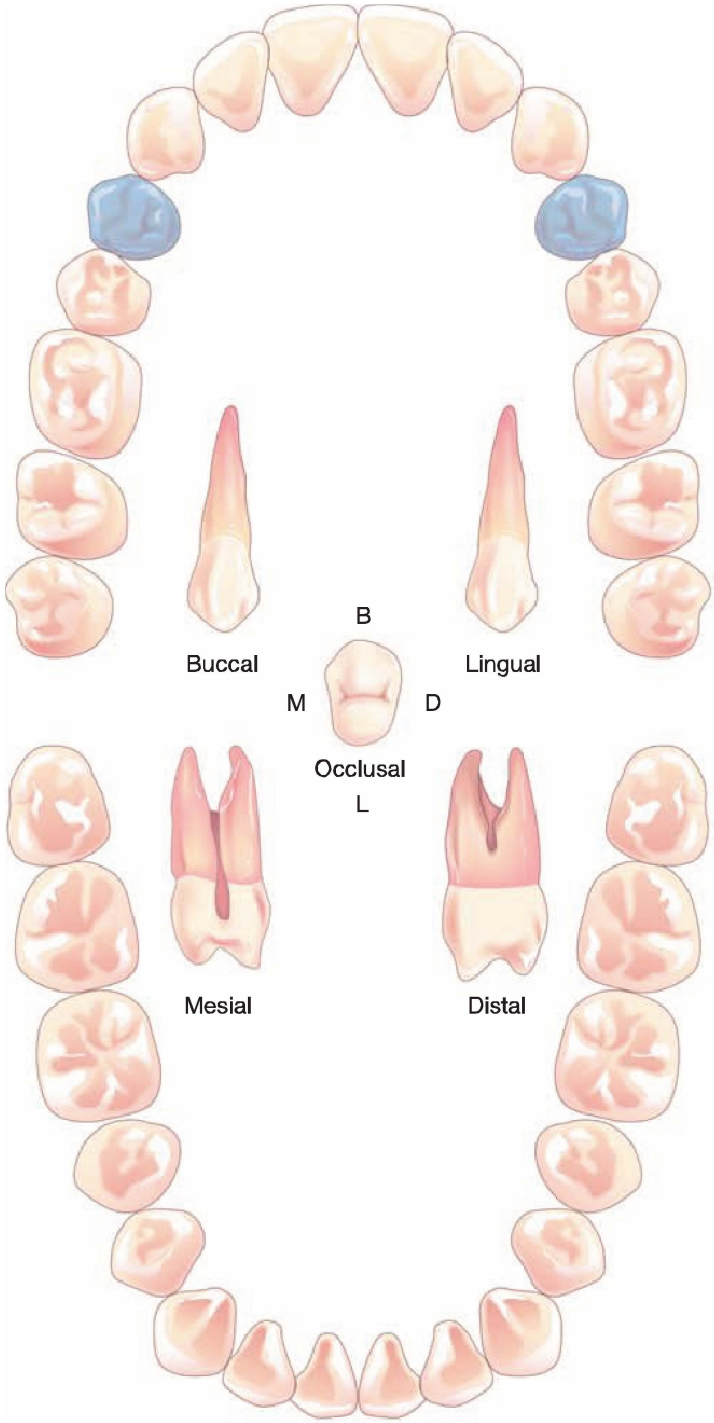

Maxillary first premolars (bicuspids)

© Cengage Learning 2013

Figure 8–1. Maxillary first premolars.

© Cengage Learning 2013

Figure 8–2. Maxillary first premolars—buccal surface.

Lingual Surface

Both cusps are visible from this view (**Figure 8–3**). As the lingual cusp is approximately 1 mm shorter, the tip of the buccal cusp extends below it. The lingual cusp is smooth—no ridge, no depressions. Some of the mesial and distal surfaces of both the crown and the root are seen because the lingual surface is narrower than the buccal.

© Cengage Learning 2013

Figure 8–3. Maxillary first premolar—lingual surface.

Proximal Surfaces

Both cusps and both roots are visible. Although the tooth appears small from the buccal view, it is about 2 mm wider when viewed from the proximal surface, from buccal to lingual. Both cusps are within the confines of the roots, thus helping to absorb some of the pressure from mastication.

The root trunk is bifurcated for one-half or less of its length. Both roots are straight until the apical third, where they incline toward each other.

Mesial Surface

Extending from the occlusal surface and crossing the marginal ridge onto the mesial surface is a mesial marginal groove (**Figure 8–4**). At its end, only a short distance onto the mesial surface, is a **mesial concavity** that continues onto the root and merges with the root bifurcation. There is a deep groove on the root that extends from the CEJ to bifurcation. It is termed the **mesial interradicular groove**.

Distal Surface

The distal surface of the crown is smooth; it has no groove or depression. The root does have a depression that extends into the bifurcation (**Figure 8–5**).

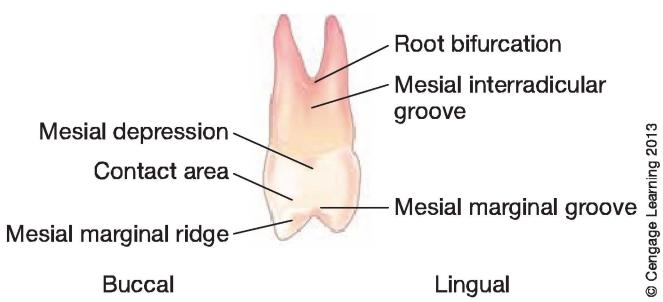

© Cengage Learning 2013

Figure 8–4. Maxillary second premolar—mesial surface.

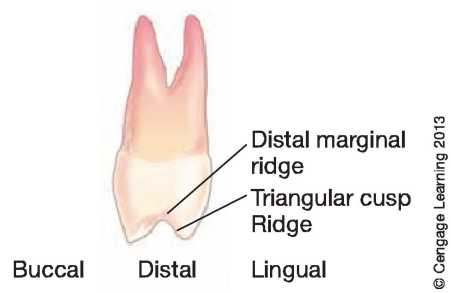

© Cengage Learning 2013

Figure 8–5. Maxillary first premolar—distal surface.

Occlusal Surface

The occlusal shape forms a hexagon, circumscribed by the marginal and cusp ridges. Because the cusps tip inward, both the buccal and lingual surfaces are visible.

Note that the buccal cusp tip is centered between the mesial and distal sides. Both the buccal and lingual cusps are pyramid shaped, with their sides sloping toward the central groove and fossae. The slope from the tip of the buccal cusp to the central groove and from the tip of the lingual cusp to the central groove forms a **triangular ridge**. The two fossae are the mesial triangular fossa and the distal **triangular fossa**.

Located at the base of the cusps, and separating them, are the grooves. Although there can be several supplementary grooves, the **major groove pattern** common to all maxillary first premolars includes the central, mesiobuccal, distobuccal, mesial marginal, and distolingual grooves (**Figure 8–6**). As with most occlusal patterns, these structures are named by their location.

It is common to find a pit where two or more grooves merge. Thus, it is likely that this occlusal will have a mesial and distal pit located in the fossae.

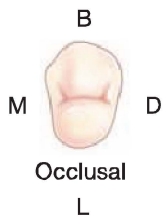

© Cengage Learning 2013

Figure 8–6. Maxillary first premolar—occlusal surface.

Clinical Considerations

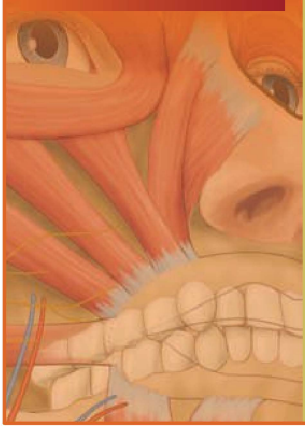

Root length: 14 mm

Root depressions/furrows: Deep depression on mesial surface extending from crown to root furcation, where there is a deeper groove into the bifurcation. Length of root trunk is approximately 7 mm from cervix to bifurcation. Distal root trunk has a depression extending from cervix to bifurcation.

CEJ: Very slight curvature (0–1 mm toward occlusal) on both mesial and distal surfaces

Cervical area: Concave on both mesial and distal surfaces, with deeper concavity on the mesial surface

Furcation: Approximately 7 mm from cervix

Summary of the Maxillary First Premolar

BUCCAL SURFACE

The characteristics of this surface are:

- A prominent buccal ridge.
- A pointed buccal cusp.

- A mesial side that is concave from the cervix to the contact area; a contact area that is in the middle of the surface; a cusp slope that is straighter and longer than the distal.
- A distal side that is straight from the cervix to the contact area; a contact area that is more occlusal than on the mesial; a cusp slope that is shorter than the mesial.
- Only the buccal root is visible.

LINGUAL SURFACE

The characteristics of this surface are:

- Both cusps are visible.
- A smooth lingual cusp that is shorter and narrower than the buccal cusp.
- Visible mesial and distal surfaces.

PROXIMAL SURFACES

The characteristics of these surfaces are:

- Two visible cusps; a lingual cusp that is 1 mm shorter than the buccal cusp.
- Two visible roots (two pulp canals).
- Cusps that are within the confines of the root trunk.
- A mesial crown surface with the mesial marginal groove and a mesial concavity that extends from the crown to the root bifurcation.
- A distal crown surface with no grooves and no depressions.
- Both roots straight until the apical third, then incline toward each other.
- Root that bifurcates for one-half its length with a deep mesial interradicular groove.

OCCLUSAL SURFACE

The characteristics of this surface are:

- Visible buccal and lingual surfaces.
- A buccal cusp centered between the mesial and distal side.
- Fossae: mesial and distal triangular.
- Grooves: central, mesiobuccal, mesiomarginal, distobuccal, and distolingual.

MAXILLARY SECOND PREMOLAR DESCRIPTION

Characteristics

Location in the arch	Fifth tooth from the midline; distal to the first premolar
Universal number	R-#4 L-#13
Eruption date	10–12 years
First evidence of calcification	2 years
Crown completion	6–7 years
Root completion	12–14 years
Function	Grinding
Length of crown	8.5 mm
Length of root	14 mm
Antagonists	Mandibular second premolar and first molar

Location of Contact Area

Mesial	Middle of the tooth
Distal	Middle of the tooth

Identifying Features

- Two cusps: one buccal, one lingual
- One root, one pulp canal
- Resembles first premolar with slight variations
- Refer to Figure 8–7.

The maxillary second premolar (**Figure 8–7**) looks like the maxillary first premolar but has the following variations:

- There is only one root and one pulp canal.
- The mesial buccal cusp slope is shorter than the distal buccal cusp slope (**Figure 8–8**).

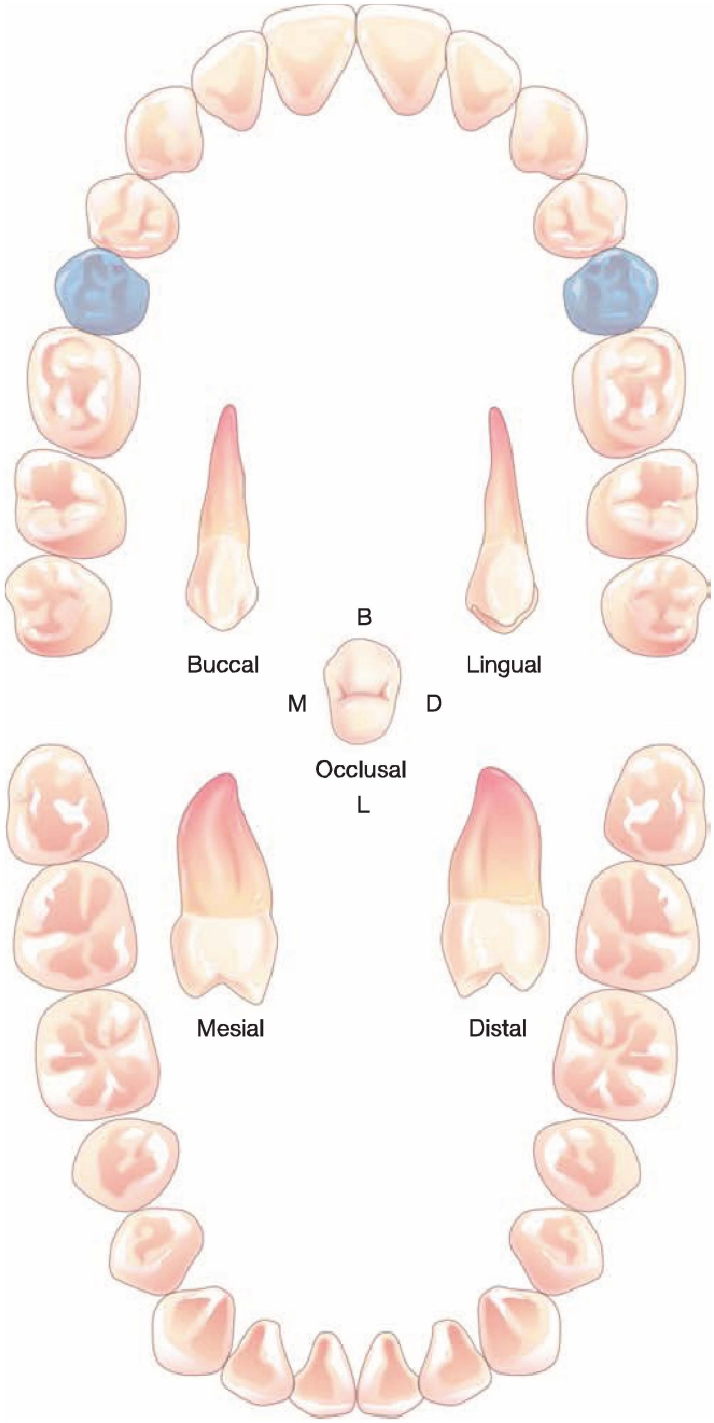

© Cengage Learning 2013

Maxillary second premolars (bicuspids)

Figure 8–7. Maxillary first premolar.

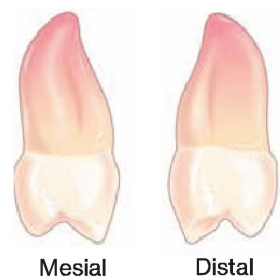

© Cengage Learning 2013

Figure 8–8. Maxillary second premolar—mesial and distal.

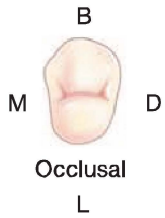

© Cengage Learning 2013

Figure 8–9. Maxillary second premolar occlusal view.

- Both cusps are about the same length (lingual is slightly shorter).
- The mesial surface of the crown has no groove and no concavity. From the occlusal view, there may be a mesial marginal groove but it seldom extends onto the mesial surface (**Figure 8–9**).
- A shallow depression is evident on the mesial surface of the root.

Clinical Considerations

Root length: 14 mm

Root depressions/furrows: A shallow depression on both mesial and distal surfaces extending the length of the root

CEJ: Very slight curvature (0–1 mm toward occlusal) on both mesial and distal surfaces

Cervical area: Concave on both mesial and distal surfaces, with deeper concavity on the mesial surface

Furcation: None

SUMMARY

Maxillary premolars are positioned just distal to the maxillary canines. There are two in each maxillary quadrant. Each premolar has two cusps, a buccal and a lingual, which account for their alternate designation of bicuspids. Lying between the cusps is an occlusal surface, which is used to crush and grind the food in preparation for digestion.

Premolars replace deciduous molars. These teeth, along with the molars, are considered posterior teeth.

The maxillary first premolar has two roots and two pulp canals; the second premolar has only one. Because of their similarities, the roots are the easiest way to distinguish the first from the second premolar.

Complete the following chart with the information requested

	Maxillary First Premolar	Maxillary Second Premolar
Universal Number		
Palmer's Notation		
Eruption Date		
Antagonists		
Succedaneous		
Number of Cusps		
Number of Roots		
*Identifying Features**		
Buccal		
Lingual		
Mesial		
Distal		
Occlusal Description		
Cusps		
Fossae		
Grooves		

*Size, number of cusps, location of grooves, etc.

Answer the following multiple-choice questions

1. When compared to the maxillary second premolar, the maxillary first premolar differs in the number of:

a. cusps
b. roots
c. lobes
d. surfaces

2. Which of the following grooves is not present on the maxillary second premolar?

a. mesiobuccal
b. distobuccal
c. distolingual
d. mesiomarginal

3. Which of the following teeth occludes with the maxillary second premolar?

a. mandibular first premolar
b. mandibular first molar
c. mandibular second molar
d. mandibular second premolar

4. Which is the correct universal number for the maxillary left first premolar?

a. #12
b. #13
c. #5
d. #6

5. The eruption date for the maxillary first premolar is:

a. 8–9 years
b. 9–10 years
c. 10–11 years
d. 11–12 years

CHAPTER 9

Mandibular Premolars

- General Information
- Mandibular First Premolar Description
- Mandibular Second Premolar Description

Objectives

At the completion of this chapter, you will be able to:

- Identify the mandibular premolars and provide information to include universal number, function, antagonist and other characteristics.
- Describe the location and contour of each mandibular premolar.
- Define the new terms in the chapter.
- Complete the worksheet at the end of the chapter.

Key Terms

Buccal ridge
Mesiolingual groove
Nonfunctioning cusp
Transverse ridge
Y-shaped groove pattern

GENERAL INFORMATION

There are four mandibular premolars: two in each quadrant. They are named by their position in the arch from anterior to posterior as first premolar and second premolar.

The mandibular first premolar has one buccal and one lingual cusp. Differing from the others, the mandibular second premolar often has one buccal and two lingual cusps; it is the only premolar with three cusps.

Both mandibular premolars usually have one root. Mandibular premolars assist the maxillary premolars with grinding and chewing food.

MANDIBULAR FIRST PREMOLAR DESCRIPTION

Characteristics	
Location in the arch	Fourth tooth from the midline; distal to canine
Universal number	R-#28 L-#21
Eruption date	10–12 years
First evidence of calcification	1¼–2 years
Crown completion	5–6 years
Root completion	12–13 years
Function	Grinding
Length of crown	8.5 mm
Length of root	14 mm
Antagonists	Maxillary cuspid and first premolar

Continues

Characteristics *continued*

Location of Contact Area

Mesial	Middle of the tooth
Distal	Middle of the tooth

Identifying Features

- Two cusps: one buccal, one lingual
- Lingual cusp is small and nonfunctioning
- One root, which sometimes tends to bifurcate at the apex
- Mesiolingual groove
- Refer to **Figure 9–1**.

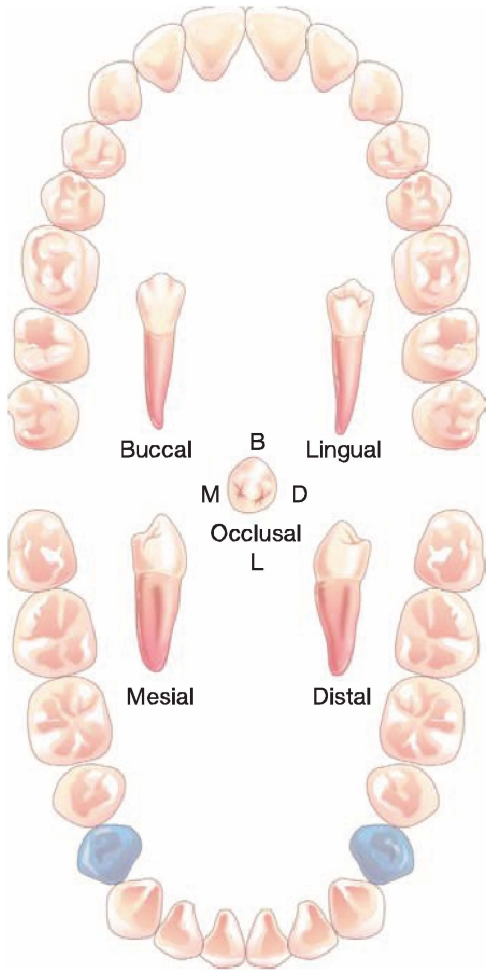

Figure 9–1. Mandibular first premolars.

© Cengage Learning 2013

Figure 9–2. Mandibular first premolar—buccal surface.

Buccal Surface

A very prominent **buccal ridge**, perhaps more rounded than any of the other premolars, extends to a pointed cusp (**Figure 9–2**). Again, as was evident in the maxillary premolars, shallow depression occurs on either side of the buccal ridge. The mesial cusp slope is shorter than the distal.

The *mesial side* is concave from the cervix to the rounded contact area in the middle of the surface. The *distal* outline is also slightly concave from the cervix to the contact area, at about the middle of the tooth.

The cervix is narrow. The root is tapered and about 3 to 4 mm shorter than the adjacent cuspid.

© Cengage Learning 2013

Figure 9–3. Mandibular first premolar—lingual surface.

Lingual Surface

The lingual cusp is short and poorly developed, extending only two-thirds the height of the crown (**Figure 9–3**). It is a **nonfunctioning cusp**. Because of the position of the cusps, most of the occlusal surface can be seen from this view. Extending from the occlusal surface onto the lingual is a **mesiolingual groove** that delineates the lingual cusp.

© Cengage Learning 2013

Figure 9–4. Mandibular first premolar—mesial and distal surfaces.

Mesial Surface

Both the buccal and lingual cusps, as well as some of the occlusal surface, are seen (**Figure 9–4**). The tip of the buccal cusp is centered over the root. Parallel to the buccal triangular ridge is the mesial marginal ridge, which is interrupted, or broken, by the mesiolingual groove.

A broad root, tapering only at the apical third, has a deep developmental groove near the apex. Often this groove will bifurcate the tip of the root.

Distal Surface

The overall shape is the reverse of the mesial, but the surface structures vary. The distal marginal ridge is perpendicular to the buccal cusp ridge, and there is no interruption by grooves (**Figure 9–4**). The root has a shallow depression, but there is seldom a groove near the apical third.

Occlusal View

Most of the buccal surface can be seen from this view (**Figure 9–5**), as well as the following occlusal structures:

- Fossae (both irregular in shape): mesial, distal
- Grooves: mesiobuccal, distobuccal, mesiolingual
- **Transverse ridge**: connects the buccal and lingual cusps

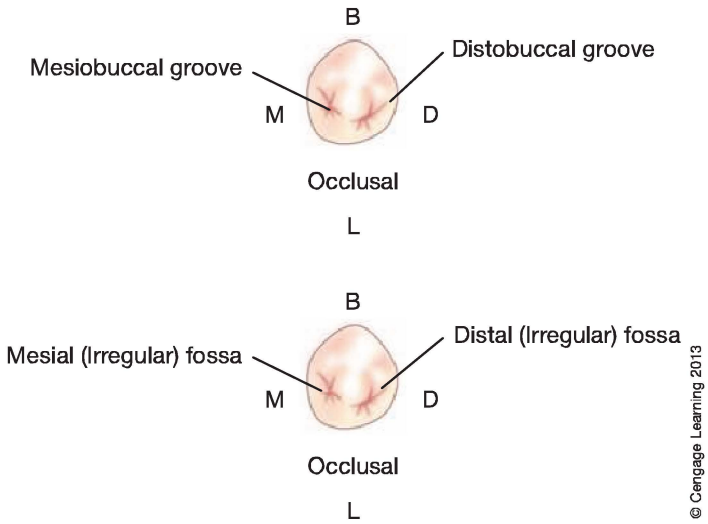

Figure 9–5. Mandibular first premolar—occlusal surface.

Clinical Considerations

Root length: 14 mm

Root depressions/furrows: The mesial depression becomes a deep groove near the apical third. This groove often bifurcates the root tip. The distal surface has a shallow depression but no groove at the apical third.

CEJ: Very slight curvature (0–1 mm toward occlusal) on both mesial and distal surfaces

Cervical area: Concave on both mesial and distal surfaces, with deeper concavity on the mesial surface

Furcation: None

Summary of the Mandibular First Premolar

BUCCAL SURFACE

The characteristics of this surface are:

- A prominent buccal ridge
- A pointed cusp
- A narrow cervix

- A mesial side that is concave from the cervix to the contact area; a contact area at the middle of the tooth; a mesial cusp slope shorter than the distal
- A distal that is concave from the cervix to the contact area; a contact area that is in the middle of the tooth; a cusp slope that is longer than the mesial

LINGUAL SURFACE

The characteristics of this surface are:

- Visible mesial and distal surfaces
- A short lingual cusp that is two-thirds the height of the crown
- A lingual cusp that is nonfunctional
- A mesiolingual groove that delineates the lingual cusp

MESIAL AND DISTAL SURFACES

The characteristics of this surface are:

- Both cusps visible
- The tip of the buccal cusp centered over the root
- A visible occlusal surface
- A mesial surface with a mesiomarginal ridge that is parallel to the buccal triangular ridge; a mesiolingual groove that interrupts the mesiomarginal ridge; a slight curve in the cervical line; a broad root with a deep developmental groove at the apical third
- A distal surface with a distal marginal ridge that is perpendicular to the buccal cusp ridge; a marginal ridge that is uninterrupted; a root that has a shallow depression but seldom has a groove; a cervical line that is straight; a concavity on the surface near the cervical line

OCCLUSAL SURFACE

The characteristics of this surface are:

- A visible buccal surface
- Two irregular fossae: mesial and distal
- Grooves: mesiobuccal, distobuccal, and mesiolingual
- A prominent transverse ridge

MANDIBULAR SECOND PREMOLAR DESCRIPTION

Characteristics

Location in the arch	Fifth tooth from the midline; distal to the first premolar
Universal number	R-#29 L-#20
Eruption date	11–12 years
First evidence of calcification	2½ years
Crown completion	6–7 years
Root completion	13–14 years
Function	Grinding
Length of crown	8 mm
Length of root	14.5 mm
Antagonists	Maxillary first and second premolar

Location of Contact Area

Mesial	Middle of the tooth
Distal	Middle of the tooth

Identifying Features

- Three cusps: buccal, mesiolingual, distolingual
- One root, one pulp canal
- Refer to **Figure 9–6**.

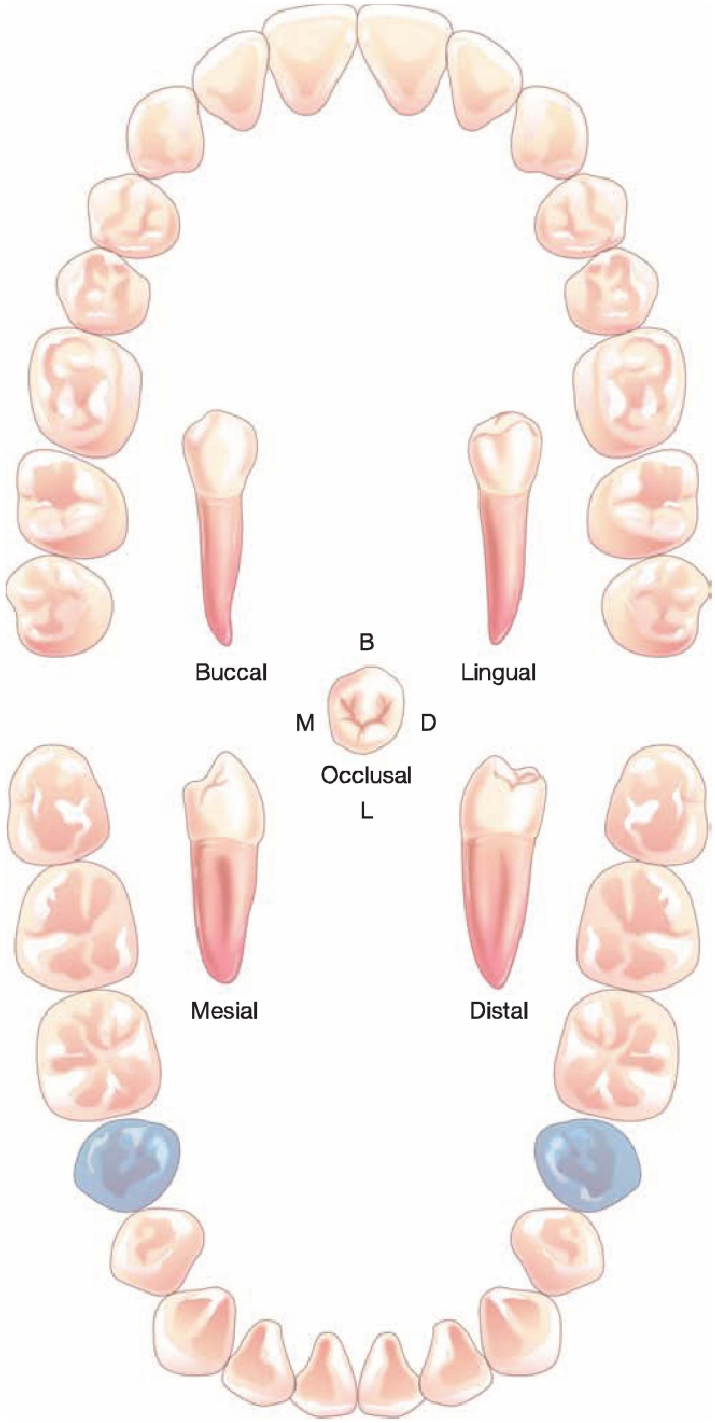

© Cengage Learning 2013

Figure 9–6. Mandibular second premolars.

The following description is of a mandibular second premolar with three cusps: the buccal, mesiolingual, and distolingual. When the mandibular second premolar has only two cusps, it resembles the mandibular first premolar.

Buccal Surface

From the buccal view, the second premolar looks similar to the first premolar, but it is slightly broader and shorter with contact areas a bit more occlusal than the first premolar. Only the buccal cusp is visible (**Figure 9–7**).

© Cengage Learning 2013

Figure 9–7. Mandibular second premolar—buccal surface.

Lingual Surface

Because the lingual cusps are shorter than the buccal cusp, all three cusps are visible from this aspect. Both the mesiolingual and the distolingual cusps are functioning cusps. Separating the two lingual cusps is the lingual groove (**Figure 9–8**). The mesiolingual cusp is the larger of the two lingual cusps.

© Cengage Learning 2013

Figure 9–8. Mandibular second premolar—lingual surface.

Mesial Surface

Because the mesial side of the tooth is larger than the distal, only the buccal and mesiolingual cusps are visible (**Figure 9–9**). The mesial marginal ridge forms a right angle with the buccal cusp slope; it is not broken by a groove. The mesial surface is smooth, with only a slight curvature at the cervical line. The root is broad, tapering at the apical third.

Distal Surface

Because the teeth converge toward the posterior portion of the mouth, the distal of the tooth is narrower than the mesial, revealing some of the occlusal surface. All three cusps can be seen (**Figure 9–9**).

© Cengage Learning 2013

Figure 9–9. Mandibular second premolar—mesial and distal surfaces.

Occlusal Surface

The order of cusp size, from largest to smallest, is buccal, mesiolingual, and distolingual. The cusps are divided by grooves forming a **"Y"-shaped groove pattern** (**Figure 9–10**). There are two fossae, both triangular in shape: mesial and distal triangular fossae. There is no transverse ridge on the three cusp variety. If there are only two cusps, there would be a transverse ridge connecting them.

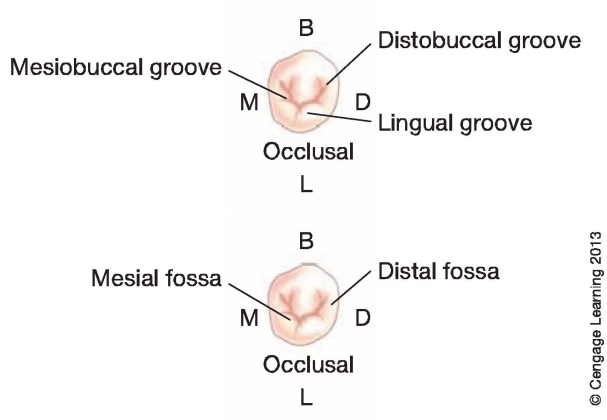

Figure 9–10. Mandibular second premolar—occlusal surface.



Clinical Considerations

Root length: 14.5 mm

Root depressions/furrows: Generally smooth, but mesial may have a shallow depression

CEJ: Very slight curvature (0–1 mm toward occlusal) on both mesial and distal surfaces

Cervical area: Slightly concave on both mesial and distal surfaces

Furcation: None

Summary of the Mandibular Second Premolar

BUCCAL SURFACE

The characteristics of this surface are:

- A resemblance to the mandibular first premolar but slightly shorter and broader
- Contact areas in the middle of the tooth but slightly more occlusal than in the first premolar

LINGUAL SURFACE

The characteristics of this surface are:

- Three visible cusps: buccal, mesiolingual, and distolingual
- Cusps are all functioning
- Lingual cusps are shorter than the buccal cusp
- A lingual groove that divides the two lingual cusps

MESIAL AND DISTAL SURFACES

The characteristics of these surfaces are:

- A mesial surface with visible buccal and mesiolingual cusps; a mesial marginal ridge that forms a right angle with the buccal cusp slope; a cervical line that has a slight curvature
- A distal surface having more of the occlusal surface visible; all three cusps visible
- Cusps, which in order of size are buccal, mesiolingual, and distolingual.
- A broad root tapering at the apical third

OCCLUSAL SURFACE

The characteristics of this surface are:

- Two triangular fossae: mesial and distal
- Mesiobuccal, distobuccal, and lingual grooves
- Grooves that form a "Y" shape on a three-cusp tooth

SUMMARY

Mandibular premolars are positioned just distal to the mandibular canines. There are two in each mandibular quadrant. Although the first premolar has two cusps, the second premolar frequently has three cusps; consequently, the term "bicuspid" would not be appropriate for this tooth.

The mandibular first premolar has not only a sharp, pointed buccal cusp but also a short, nonfunctioning lingual cusp that makes this tooth easy to distinguish from other premolars. The mandibular second premolar may have two cusps and resemble the first, but it frequently has three cusps (one buccal and two lingual) that are nearly the same height.

As with all posterior teeth, the occlusal surface is located between the cusps and outlined by marginal ridges. All cusps slope into grooves located at the base of the occlusal surface.

WORKSHEET

Complete the following chart with the information requested

	Mandibular First Premolar	Mandibular Second Premolar
Universal Number		
Palmer's Notation		
Eruption Date		
Antagonists		
Succedaneous		
Number of Cusps		
Number of Roots		
*Identifying Features**		
Buccal		
Lingual		
Mesial		
Distal		
Occlusal Description		
Cusps		
Fossae		
Grooves		

*Size, number of cusps, location of grooves, etc.

Answer the following multiple-choice questions

1. Which of the premolars has a nonfunctioning cusp?

a. maxillary first premolar
b. maxillary second premolar
c. mandibular first premolar
d. mandibular second premolar

2. Premolars cannot always be called bicuspids because which of the following may have more than two cusps?

a. maxillary first premolar
b. maxillary second premolar
c. mandibular first premolar
d. mandibular second premolar

3. Which of the premolars has a cuspid for an antagonist?

a. maxillary first premolar
b. maxillary second premolar
c. mandibular first premolar
d. mandibular second premolar

4. Most of the occlusal surface is visible from the lingual view on which of the following premolars?

a. maxillary first premolar
b. maxillary second premolar
c. mandibular first premolar
d. mandibular second premolar

5. The mandibular first premolar replaces which of the following deciduous teeth?

a. deciduous first premolar
b. deciduous second premolar
c. deciduous first molar
d. deciduous second molar

CHAPTER 10

Maxillary First and Second Molars

General Information
Maxillary First Molar Description
Maxillary Second Molar Description

Objectives

At the completion of this chapter, you will be able to:

- Identify the maxillary first and second molars and provide information to include universal number, function, antagonist, and other characteristics.
- Describe the location and contour of each first and second maxillary molar.
- Define the new terms in the chapter.
- Complete the worksheet at the end of the chapter.

Key Terms

Cusp of Carabelli
Oblique ridge
Pulp canal
Succedaneous
Trifurcated
Tubercle

GENERAL INFORMATION

There are six maxillary molars: three in each quadrant. Like the premolars, molars are named by their position in the arch from anterior to posterior or first molar, second molar, and third molar. Permanent molars erupt posterior to the primary second molars and do not replace deciduous teeth.

The first molar is the first permanent tooth to erupt. The mandibular first molar precedes the maxillary first molar by a few months, but both usually erupt before the permanent central incisors.

With the exception of third molars, all maxillary molars have at least four cusps. The maxillary first molar usually has a fifth, nonfunctioning cusp, or **tubercle**, that is positioned on another cusp. This fifth cusp is known as the **cusp of Carabelli**. The number of lobes from which a molar develops is the same as the number of cusps.

Maxillary molars have **trifurcated** (divided into three) roots: mesiobuccal, distobuccal, and lingual. Each root has one **pulp canal**.

Molars are structured so that they are narrower (that is, they converge) toward the posterior portion of the mouth. Thus, the distal of the tooth is narrower than the mesial. Because they have multicusps, molars perform the major tasks of mastication and comminution by grinding and pulverizing food.

MAXILLARY FIRST MOLAR DESCRIPTION

Characteristics	
Location in the arch	Sixth tooth from the midline; distal to maxillary second premolar
Universal number	R-#3 L-#14
Eruption date6	7 years
First evidence of calcification	Birth

Continues

Characteristics *continued*

Crown completion	2½–3 years
Root completion	9–10 years
Function	Mastication and comminution of food
Length of crown	7.5 mm
Length of root	12 mm buccal, 13 mm lingual
Antagonists	Mandibular first and second molars

Location of Contact Area

Mesial	2/3 distance from cervical line
Distal	Middle of the tooth

Identifying Features

- Five cusps: mesiobuccal, distobuccal, mesiolingual, distolingual, cusp of Carabelli
- Three roots: mesiobuccal, distobuccal, lingual
- Three pulp canals, one in each root, the mesiobuccal root may have two pulp canals
- Cusp of Carabelli, or fifth cusp, located on the mesiolingual cusp, is a nonfunctioning cusp
- Largest and strongest of the maxillary teeth
- Refer to **Figure 10–1**.

Buccal Surface

The two buccal cusps and the cusp tips of the two longer lingual cusps are seen from this view (**Figure 10–2**). Dividing the mesiobuccal and distobuccal cusps is the buccal groove. This extends about one-half the length of the crown, ending in a shallow depression.

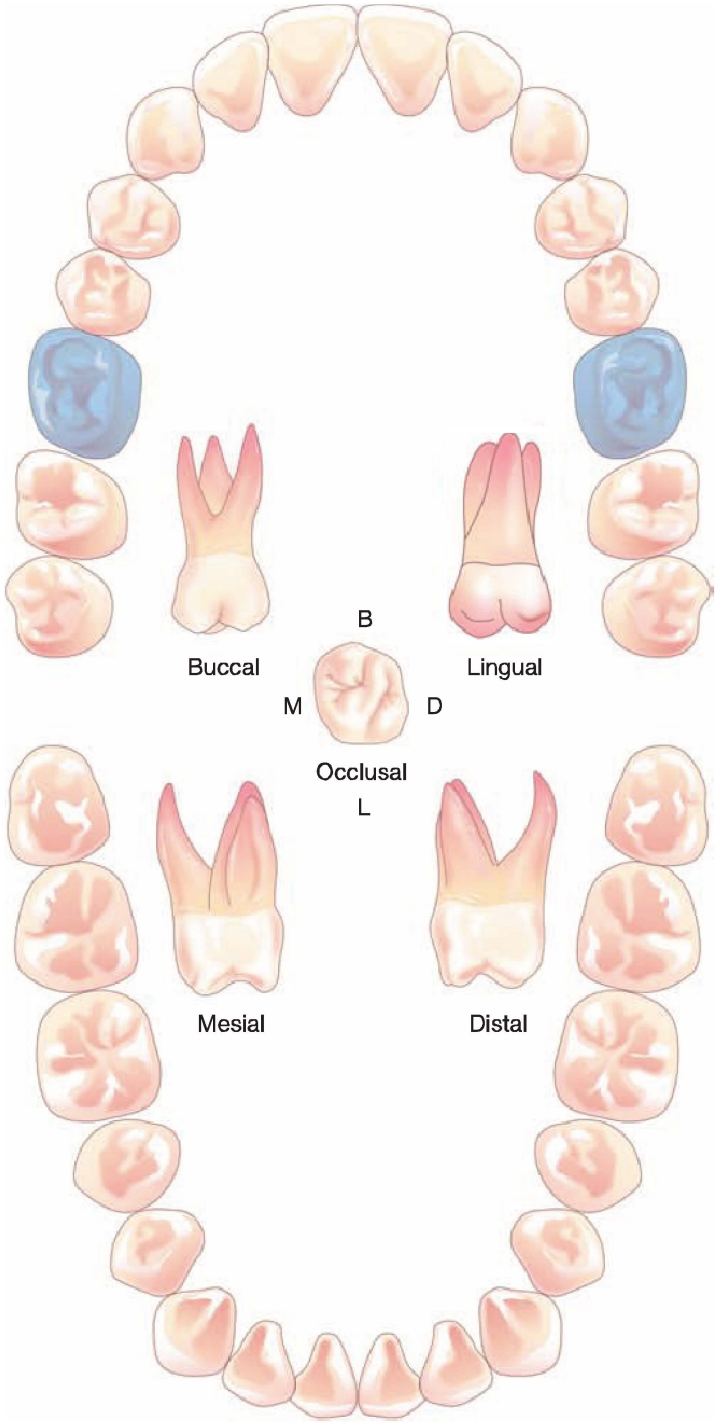

© Cengage Learning 2013

Figure 10–1. Maxillary first molars.

© Cengage Learning 2013

Figure 10–2. Maxillary first molar—buccal surface.

The mesial side, from cervix to contact area, is straight. The contact area, located about two-thirds the distance from the cervical line, is convex. The distal side is convex and reaches the contact area in the middle of the tooth. The cervical line forms a slight curve.

Before bifurcating into the mesiobuccal and distobuccal root, the root trunk extends about 4 mm. A shallow depression continues from the cervical line to its end as a deep groove at the bifurcation. The mesiobuccal root extends halfway in a mesial direction before curving distally; the smaller distobuccal root is straight for half its length, then curves mesially. The mesiobuccal root may have two pulp canals. Seen between the two buccal roots and extending above them by 1 mm is the lingual root.

Lingual

Figure 10–3. Maxillary first molar—lingual surface.

Lingual Surface

© Cengage Learning 2013

Because the two lingual cusps, mesiolingual and distolingual, are longer than the buccal cusps, they block the buccal cusps from view. Dividing the two lingual cusps is the lingual groove (**Figure 10–3**). The mesiolingual cusp is about three-fifths the width of the crown and supports the fifth cusp, the cusp (or tubercle) of Carabelli. The mesiolingual cusp is the largest cusp. The fifth cusp is not always present; even when it is, it may not be well developed because it is a nonfunctioning cusp. A short groove, the fifth cusp groove, is usually present on the mesiolingual cusp when the tubercle is absent. The distolingual cusp is a smooth spheroid.

Although the lateral borders of the two buccal roots can be seen, the lingual root is dominant. It is broad with a furrow extending most of its length, and it tapers to a blunt apex.

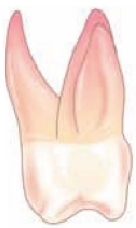

Mesial

Figure 10–4. Maxillary first molar—mesial surface.

Mesial Surface

© Cengage Learning 2013

Because the mesial side is wider than the distal, only the mesiobuccal and mesiolingual cusps and the cusp of Carabelli are seen. The mesial marginal ridge, connecting the cusps, is about one-fifth the distance from the cusp tips; it obstructs the occlusal surface. Just cervical to the contact area is a shallow depression that continues from the crown onto the root trunk.

Both the mesiobuccal and lingual root block the smaller distal root. The mesiobuccal root is flat but broad, with a depression spanning most of its length. The lingual root is long and narrow (banana shaped) from this aspect (**Figure 10–4**).

Distal

Figure 10–5. Maxillary first molar—distal surface.

Distal Surface

© Cengage Learning 2013

Because the crown converges, some of the buccal surface can be seen (**Figure 10–5**). The distal marginal ridge curves more cervically than the mesial marginal ridge, exposing some of the occlusal surface.

The cervical line is almost straight. Although all three roots are visible, only the outline of the mesiobuccal root can be seen. From the cervical line to the distobuccal root is a depression. There is no concavity at the bifurcation.

Occlusal Surface

The width from buccal to lingual is wider than from mesial to distal. Looking down onto the occlusal surface, you can more easily see the convergence of the crown toward the distal and the size of the five cusps. From largest to smallest, the cusps are mesiolingual, mesiobuccal, distobuccal, distolingual, and cusp of Carabelli.

The buccal groove extends from the buccal surface onto the occlusal and joins the central groove. The distobuccal cusp and the mesiolingual cusp, which form an **oblique ridge**, are divided by a transverse groove, an extension of the central groove that continues into the distal fossa. On the occlusal surface, the two lingual cusps are divided by the distal oblique groove, an extension of the lingual groove (lingual surface) that, obviously, extends obliquely into the distal fossa.

All cusps slope downward toward the grooves. It is the base and sides of the cusp slopes that form the fossa. On this tooth there is a large circular central fossa. Notice, in **Figure 10–6**, the number of cusps that slope into it. The two lingual cusps slope into the distal linear fossa as well as into the mesial and distal triangular fossa.

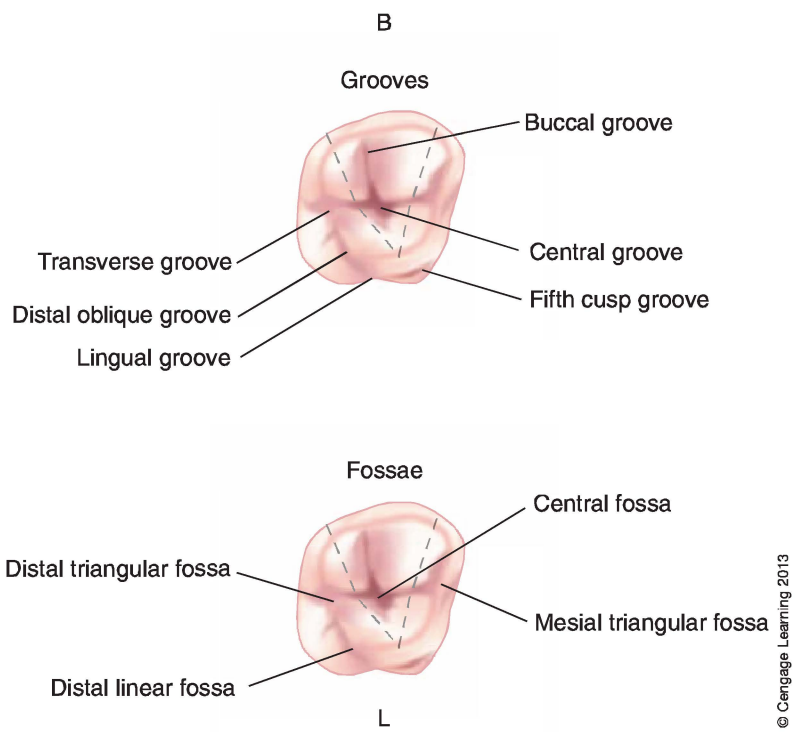

Figure 10–6. Maxillary first molar—occlusal surface.

Clinical Considerations

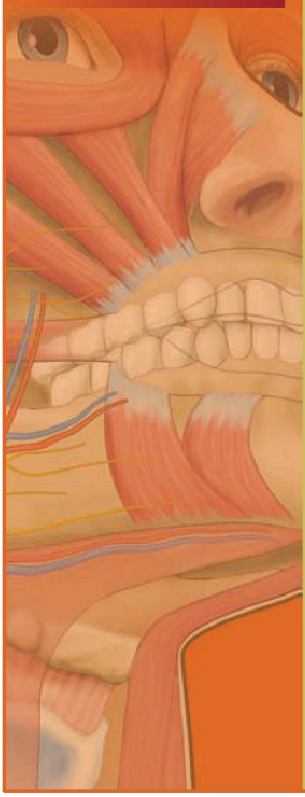

Root length: Buccal root is 12 mm; lingual root is 13 mm

Root depressions: (1) On the buccal surface, a shallow depression from the cervical line ends in a deep groove at the bifurcation. The root trunk is approximately 4 mm in length. (2) On the lingual surface, a broad depression extends most of its length. (3) On the mesial surface, a depression from the contact area of the crown continues onto the root trunk; the mesiobuccal root has a broad depression extending most of its length; and the lingual root is smooth. Bifurcation is approximately 4 mm from cervix. (4) On the distal surface, a depression extends from the cervical line to the distobuccal root. Root bifurcation occurs at 4–5 mm, with no concavity.

CEJ: Very slight curvature (0–1 mm toward occlusal) on both mesial and distal surfaces

Cervical area from buccal or lingual surface: Both the mesial and distal surfaces are concave

Furcation: The buccal surface bifurcates at 4 mm from cervical line; the mesial surface bifurcates 4 mm from cervical line; the distal surface bifurcates 4–5 mm from cervical line; the lingual surface has no furcation.

Summary of the Maxillary First Molar

BUCCAL SURFACE

The characteristics of this surface are:

Crown

- There are two buccal cusps: mesiobuccal and distobuccal.
- Two longer lingual cusp tips are visible.
- The buccal groove divides the two buccal cusps; it extends one-half the crown length and terminates in a shallow depression.
- The mesial outline is straight.
- The mesial contact is two-thirds the distance from the cervical line.
- The distal side is convex.
- The distal contact area is in the middle of the surface.

Root

- There are two buccal roots: mesiobuccal and distobuccal.
- The mesiobuccal root extends in a mesial direction for half its length and then curves distally.
- The distobuccal root is straight for half its length, then curves mesially.
- The root trunk is about 4 mm long before bifurcating.
- A shallow depression extends from the cervical line and terminates in a deep groove at the bifurcation.
- The lingual root extends between and above the buccal roots.

LINGUAL SURFACE

The characteristics of this surface are:

Crown

- Three visible cusps: mesiolingual, distolingual, and cusp of Carabelli
- A mesiolingual cusp about three-fifths the width of the crown
- A cusp of Carabelli positioned on the mesiolingual cusp
- A fifth cusp groove on the mesiolingual cusp if the fifth cusp is not present
- A lingual groove dividing the two lingual cusps

Roots

- A broad, tapered lingual root, the longest of the three roots, with a furrow or depression
- A visible outline of both buccal roots

MESIAL SURFACE

The characteristics of this surface are:

Crown

- Visible cusps: mesiobuccal, mesiolingual, and cusp of Carabelli
- A depression on the crown from the contact area to the root trunk
- A mesial marginal ridge about one-fifth the distance from the cusp tips

Root

- Two visible roots: a broad, flat mesiobuccal root and a tapered lingual root
- A depression on the lingual root

DISTAL SURFACE

The characteristics of this surface are:

Crown

- Visible buccal and occlusal surfaces
- An almost straight cervical line

Root

- All three roots visible (only the border of the mesiobuccal root can be seen)
- A depression from the cervical line to the distobuccal root
- No concavity in the root bifurcation

OCCLUSAL SURFACE

The characteristics of this surface are:

- Dimensions that are wider from the buccal to the lingual than from the mesial to the distal
- Four functioning *cusps* and a small fifth cusp (in order of size): mesiolingual, mesiobuccal, distobuccal, distolingual, and cusp of Carabelli
- Grooves: buccal, central, transverse groove of the oblique ridge, and distal oblique; the lingual and fifth cusp groove are visible from this view
- Fossae: central, distal linear, mesial triangular, and distal triangular

MAXILLARY SECOND MOLAR DESCRIPTION

Characteristics	
Location in the arch	Seventh tooth from the midline; distal to the first molar
Universal number	R-#2 L-#15
Eruption date	12–13 years

Continues

Characteristics *continued*

First evidence of calcification	2½–3 years
Crown completion	7–8 years
Root completion	14–16 years
Function	Mastication and comminution
Length of crown	7 mm
Length of root	11 mm buccal, 12 mm lingual
Antagonists	Mandibular second and third molars

Location of Contact Area

Mesial	2/3 from cervical line
Distal	Middle of the tooth

Identifying Features

- Four cusps: mesiobuccal, distobuccal, mesiolingual, distolingual
- Three roots: mesiobuccal, distobuccal, lingual
- Three pulp canals—one in each root
- Refer to **Figure 10–7**.

The maxillary second molar is similar to the maxillary first molar in size, shape, and function but has the following differences:

- Both the crown and root are slightly smaller.
- The second molar has only four cusps: mesiobuccal, distobuccal, mesiolingual, and distolingual.
- There is no cusp of Carabelli.
- The roots are not as divergent. They are closer together.
- The occlusal surface has more supplementary grooves.
- There is no transverse groove of the oblique ridge.

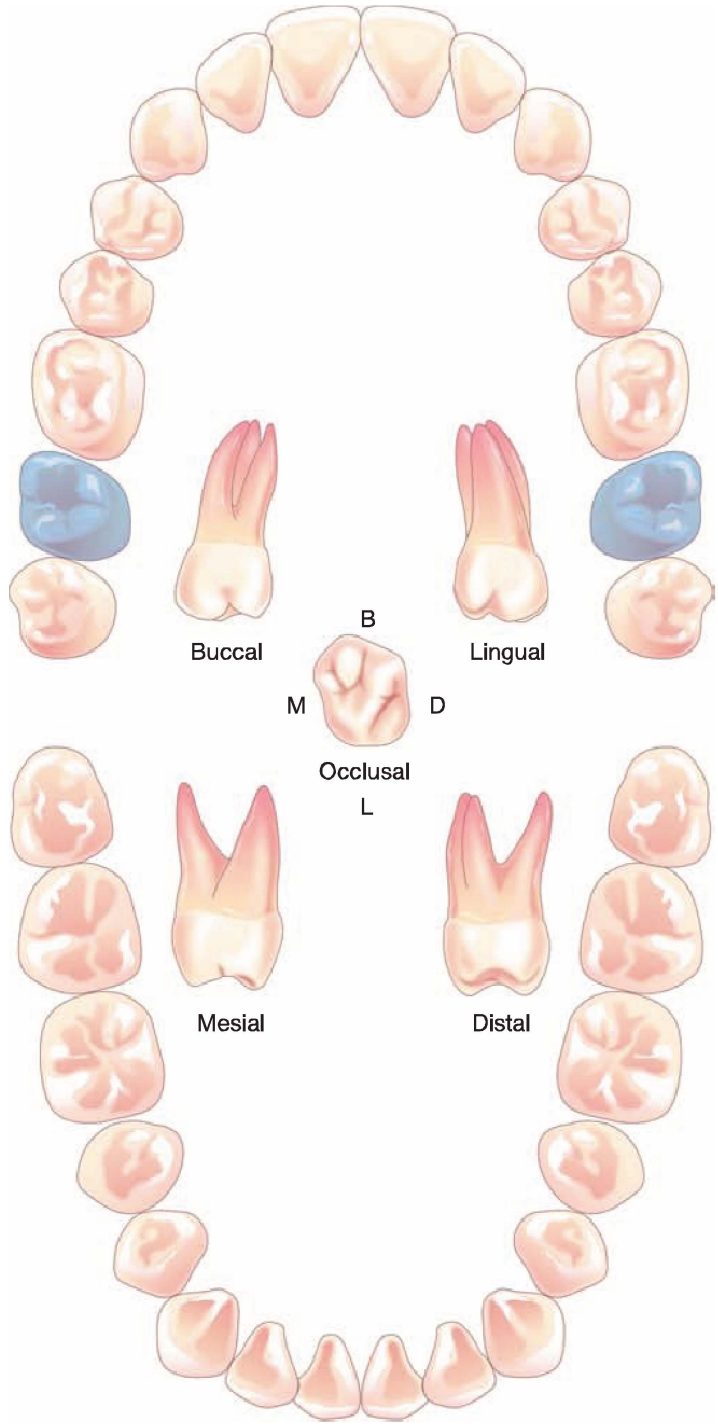

© Cengage Learning 2013

Figure 10–7. Maxillary second molars.

Occlusal Surface

The characteristics of this surface, shown in **Figure 10–8**, are:

- Grooves: buccal, lingual, distal oblique, and central groove
- Fossae: central, distal linear, distal triangular, and mesial triangular
- Cusps, in order of size: mesiolingual, mesiobuccal, distobuccal, and distolingual

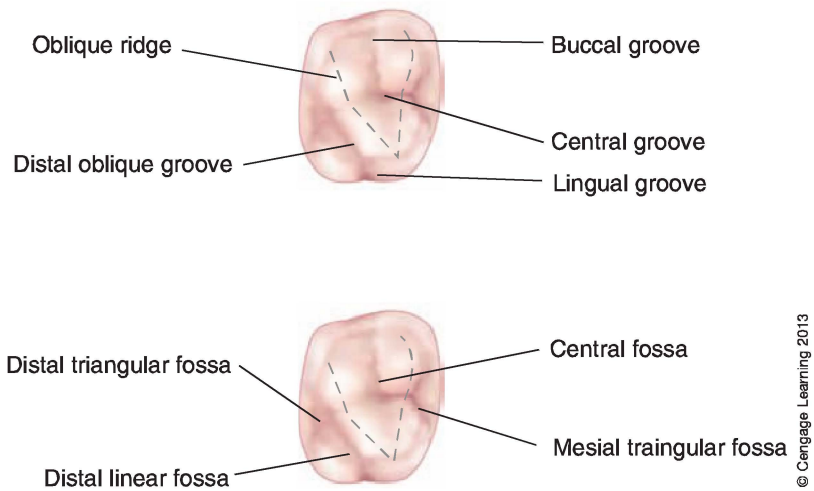

Figure 10–8. Maxillary second molar—occlusal surface.

Clinical Considerations



Root length: 11 mm buccal; 12 mm lingual

Root depressions/furrows: Similar to those on maxillary first molar

CEJ: Very slight curvature (0–1 mm toward occlusal) on mesial and distal surfaces

Cervical area from buccal or lingual surface: Similar to that of maxillary first molar

Furcation: Similar to that of maxillary first molar

SUMMARY

There are three maxillary molars in each maxillary quadrant. They have at least four cusps and a broad occlusal surface. Because of their size, the molars perform the major task of grinding and pulverizing food.

The maxillary first molar has four functioning cusps and one small tubercle on the mesiolingual cusp called the fifth cusp, or cusp of Carabelli. The first molar is the largest and strongest of the maxillary teeth. The second molar resembles the first but does not have a fifth cusp, and its overall dimensions are slightly smaller than the first.

All maxillary molars have three roots, each with one pulp canal. The mesiobuccal root of the maxillary first molar may have two pulp canals. Molars are *not* **succedaneous** teeth.

Complete the following chart with the information requested

	Maxillary First Molar	Maxillary Second Molar
Universal Number		
Palmer's Notation		
Eruption Date		
Antagonists		
Succedaneous		
Number of Cusps		
Number of Roots		
*Identifying Features**		
Buccal		
Lingual		
Mesial		
Distal		
Occlusal Description		
Cusps		
Fossae		
Grooves		

*Size, number of cusps, location of grooves, etc.

Label the following on each Maxillary Molar diagram below

	Grooves	Fossae	Ridges	Pit
FIRST	Buccal Central Transverse Distal oblique Lingual Fifth cusp	Central Distal triangular Mesial triangular Distal linear	Marginal Oblique	Central
SECOND	Buccal Central Distal oblique Lingual	Central Distal triangular Mesial triangular Distal linear	Marginal Oblique	Central

Maxillary first molar

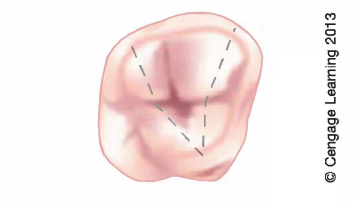

© Cengage Learning 2013

Maxillary second molar

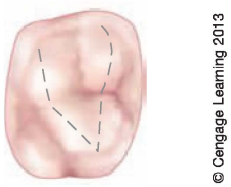

© Cengage Learning 2013

Answer the following multiple-choice questions

1. The maxillary first molar differs from the maxillary second molar in:

- **a.** number of cusps
- **b.** number of roots
- **c.** number of fossae
- **d.** all of the above

2. The occlusal groove on the maxillary first molar that is not present on the maxillary second molar is the:

- **a.** buccal groove
- **b.** distal oblique groove
- **c.** transverse groove
- **d.** lingual groove

3. Which tooth is an antagonist of both maxillary molars?

a. mandibular second premolar

b. mandibular first premolar

c. mandibular second molar

d. mandibular third molar

4. The eruption date of the maxillary second molar is:

a. 9–10 years

b. 10–11 years

c. 12–13 years

5. The largest cusp of the maxillary molars is the:

a. mesiobuccal cusp

b. distobuccal cusp

c. distolingual cusp

d. mesiolingual cusp

CHAPTER 11

Mandibular First and Second Molars

General Information
Mandibular First Molar Description
Mandibular Second Molar Description

Objectives

At the completion of this chapter, you will be able to:

- Identify the mandibular first and second molars, and identify the vital information including universal number, function, antagonist, and other characteristics.
- Describe the location and contour of each first and second molar.
- Define the new terms in the chapter.
- Complete the worksheet at the end of the chapter.

Key Terms

Alignment
Bifurcated
Central pit
Distal cusp
Keystone
Mastication
Succedaneous

GENERAL INFORMATION

There are six mandibular molars: three in each quadrant. As with the maxillary molars, they are named for their position in the arch: first, second, and third molar. Again, molars erupt posterior to the primary second molars and are not **succedaneous** teeth.

The mandibular first molar is the first permanent tooth to erupt, and its positioning in the arch is important for the appropriate **alignment** of the other permanent teeth. (See Chapter 15, "Occlusion.") Therefore, it is considered the "**keystone**" of the dental arch.

Mandibular molars have either four or five cusps; the number of lobes from which they develop is the same as the number of cusps. The roots of mandibular molars are **bifurcated** (divided in two) into a mesial and distal root. Although each root of a tooth usually has one pulp canal, the mandibular first molar is the exception and has two pulp canals in the mesial root. The major function of the mandibular molars is to assist the maxillary molars with grinding and pulverizing the food.

MANDIBULAR FIRST MOLAR DESCRIPTION

Characteristics	
Location in the arch	Sixth tooth from the midline; distal to second premolar
Universal number	R-#30 L-#19
Eruption date	6–7 years
First evidence of calcification	Birth
Crown completion	2½–3 years
Root completion	9–10 years

Continues

Characteristics *continued*

Function	Mastication and comminution of food
Length of crown	7.5 mm
Length of root	14 mm
Antagonists	Maxillary second premolar and first molar

Location of Contact Area

Mesial	Occlusal third
Distal	Occlusal third

Identifying Features

- Five cusps: mesiobuccal, distobuccal, distal, mesiolingual, distolingual
- Two roots: mesial and distal
- Three pulp canals: two in mesial root, one in distal root
- Largest mandibular tooth
- First permanent tooth to erupt
- Refer to **Figure 11–1**.

Buccal Surface

Three buccal cusps and the tips of the two higher lingual cusps can be seen. The buccal cusps are flat and separated by grooves (**Figure 11–2**). The cusps, in order of size, are mesiobuccal, distobuccal, and distal. They are divided by the mesiobuccal and distobuccal grooves, respectively. Slight depressions are at the base of each groove.

The *mesial side*, from cervix to contact area, is concave, becoming convex at the contact area in the occlusal third. The *distal side* is straight from cervix to contact area, where it becomes convex. The contact area is located slightly more toward the occlusal than on the mesial side.

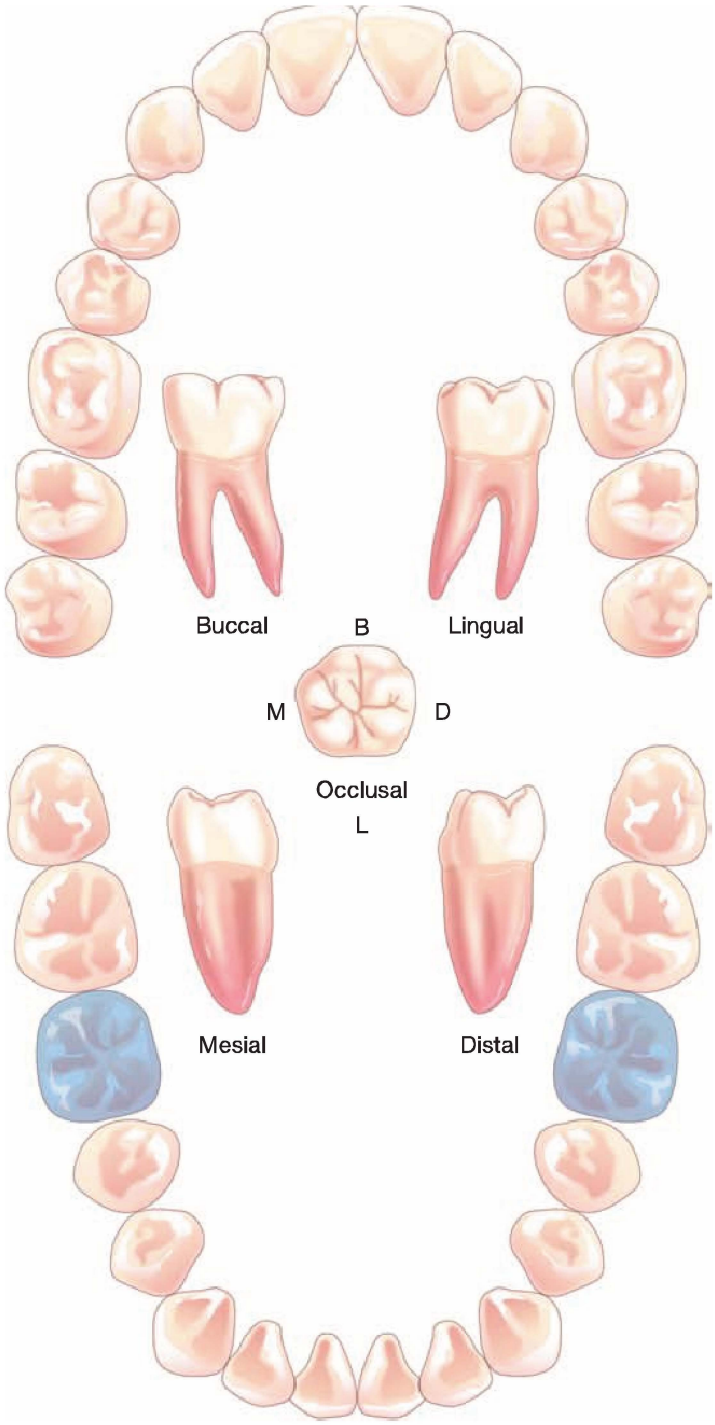

© Cengage Learning 2013

Figure 11–1. Mandibular first molars.

© Cengage Learning 2013

Figure 11–2. Mandibular first molar—buccal surface.

Lingual

Figure 11–3. Mandibular first molar—lingual surface.

© Cengage Learning 2013

The cervical line curves slightly in an apical direction. The root trunk, about 3 mm in length, bifurcates into a mesial and distal root. For half its length, the mesial root curves mesially; then it curves toward the distal. The distal root is less curved and slants in a distal direction.

Lingual Surface

There are two pointed lingual cusps, the mesiolingual and distolingual, divided by a lingual groove (**Figure 11–3**). The **distal cusp** can also be seen. At the root bifurcation is a deep developmental groove.

Mesial

Figure 11–4. Mandibular first molar—mesial surface.

© Cengage Learning 2013

Mesial Surface

Because the tooth is broader on the mesial side, only the mesiobuccal and mesiolingual cusps are seen (**Figure 11–4**). They are joined by the mesial marginal ridge, located about 1 mm below the cusp tips. The cervical line curves 1 mm in an occlusal direction.

Extending from the contact area and continuing onto the root is a shallow depression. The root remains broad for almost its entire length, tapering only at the apical third. This mesial root usually has two pulp canals.

Distal

Figure 11–5. Mandibular first molar—distal surface.

© Cengage Learning 2013

Distal Surface

Because the crown converges toward the distal, a portion of the buccal surface is seen. The distal portion of the crown is also shorter, such that all the cusps are visible (**Figure 11–5**). A relatively straight cervical line separates the crown and the root. A shallow depression is present on the distal root.

OCCLUSAL SURFACE

The dimensions are wider from mesial to distal than from buccal to lingual, the opposite of the maxillary molar. All five cusps are functioning cusps, each separated by a groove (**Figure 11–6**). The occlusal grooves extend from the buccal and lingual surface and have the same names: mesiobuccal, distobuccal, and lingual. These three grooves form a Y shape. They each join the central groove, which goes from mesial to distal across the center of the occlusal surface. There is a deep **central pit** where grooves merge.

The sides of each cusp slope to form fossae. There is a large central circular fossa as well as mesial and distal triangular fossae.

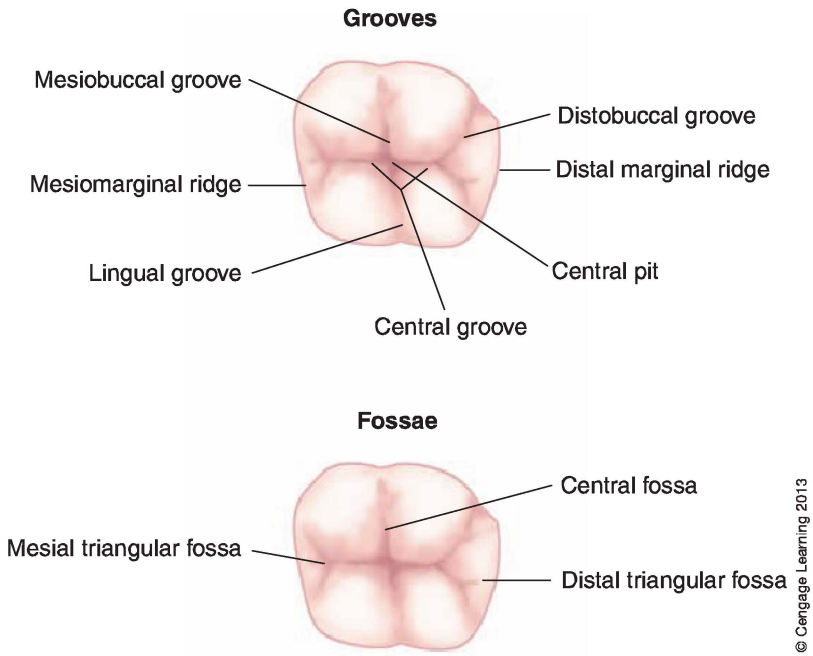

Figure 11–6. Mandibular right first molar—occlusal surface.

Clinical Considerations

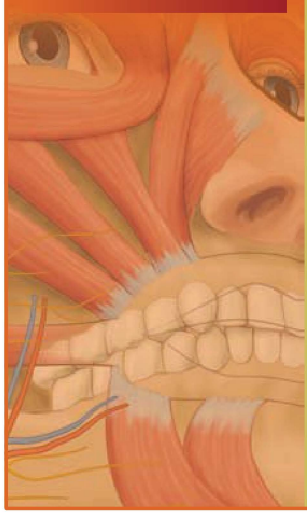

Root length: 14 mm

Root depressions: (1) On the buccal surface, a deep depression extending into the root bifurcation 3 mm from the cervical line; (2) on the lingual surface, a deep developmental depression at bifurcation; (3) on the mesial surface, a broad but shallow depression extending from the crown down the root surface; and (4) on the distal surface, a shallow depression extending most of root length.

CEJ: Very slight curvature (0–1 mm toward occlusal) on both mesial and distal surfaces

Cervical area from buccal or lingual surface: Mesial side is concave; distal surface is straight.

Furcation: Buccal surface is 3 mm from cervical line; lingual surface is 3–4 mm from the cervical line.

Summary of the Mandibular First Molar

BUCCAL SURFACE

The characteristics of this surface are:

Crown

- Three flat buccal cusps: mesiobuccal, distobuccal, and distal
- Five cusps are visible as the lingual cusps are longer and more pointed
- Mesiobuccal and distobuccal grooves divide the cusps
- Slight depression or pit at the base of each groove
- A concave mesial side
- A mesial contact area in the occlusal third
- A straight distal side
- A distal contact area that is more occlusal than the mesial contact area

Root

- The mesial root curves mesially for half its length, then curves distally.
- The distal root is less curved, with its axis in a distal direction.
- The root bifurcates about 3 mm below the cervical line and has a deep developmental depression.

LINGUAL SURFACE

The characteristics of this surface are:

Crown

- Two pointed lingual cusps: mesiolingual and distolingual
- A visible distal cusp
- A lingual groove that divides the lingual cusps

Roots

- A deep developmental depression at the root bifurcation

MESIAL SURFACE

The characteristics of this surface are:

Crown

- Two visible cusps: mesiobuccal and mesiolingual
- Mesial marginal ridge located about 1 mm below cusp tips
- Cervical line curves occlusally about 1 mm
- Concave area at the cervical line that continues onto the root

Root

- Only the mesial root is visible
- Mesial root usually has two pulp canals
- Broad and straight root, tapering in the apical third
- A broad concavity or depression on the root

DISTAL SURFACE

The characteristics of this surface are:

Crown

- Tooth converges toward distal so that some of the buccal surface is seen
- Crown is shorter on the distal so that all cusps are seen
- Relatively straight cervical line

Root

- A shallow depression is often evident on the root

OCCLUSAL SURFACE

The characteristics of this surface are:

- Dimensions are wider (by 1 mm) from distal to mesial than from buccal to lingual
- Five functioning cusps, in order of size, are mesiolingual, mesiobuccal, distolingual, distobuccal, and distal
- Major grooves: central, mesiobuccal, distobuccal, and lingual (Y shape)
- Major fossae: central (circular), mesial, and distal triangular (**Figure 11–6**)
- Pits: central, mesial, and distal

MANDIBULAR SECOND MOLAR DESCRIPTION

Characteristics	
Location in the arch	Seventh tooth from the midline; distal to the first molar
Universal number	R-#31 L-#18

Continues

Characteristics *continued*

Eruption date	11–13 years
First evidence of calcification	2½–3 years
Crown completion	7–8 years
Root completion	14–15 years
Function	Mastication and comminution
Length of crown	7 mm
Length of root	13 mm
Antagonists	Maxillary first and second molars

Location of Contact Area

Mesial	Occlusal third
Distal	Occlusal third

Identifying Features

- Four cusps: mesiobuccal, distobuccal, mesiolingual, distolingual
- Two roots: mesial and distal
- Two pulp canals: one in each root
- Refer to **Figure 11–7**.

Because of its similarity to the first molar, only the structural variations of the mandibular second molar are listed below (see **Figure 11–8** for buccal, lingual, mesial, and distal views of the mandibular second molar).

- It is smaller.
- There are only four cusps: mesiobuccal, distobuccal, mesiolingual, and distolingual.
- The buccal groove divides the two buccal cusps and continues onto the occlusal surface.
- The lingual groove divides the two lingual cusps and continues onto the occlusal surface.
- The mesial side of the tooth is wider (from buccal to lingual) than the distal. Therefore the mesial cusps are larger than the distal cusps.

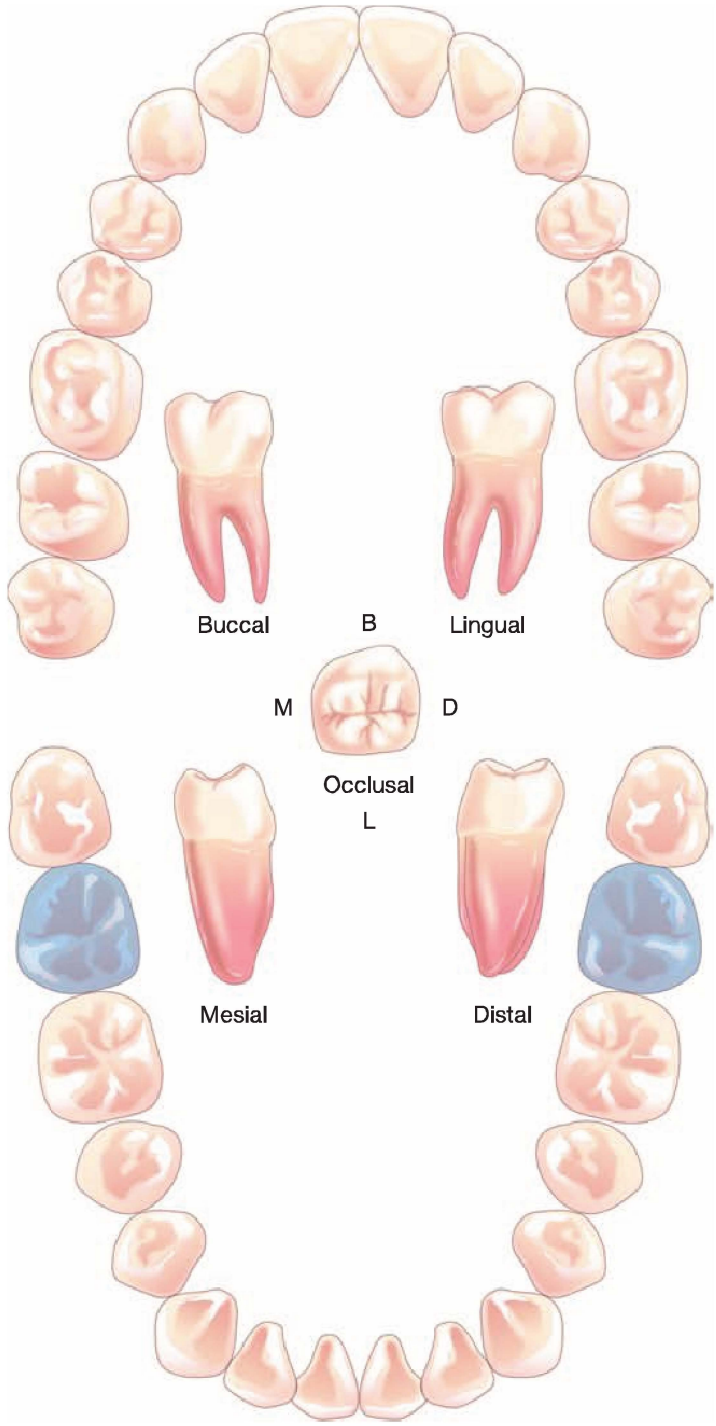

© Cengage Learning 2013

Figure 11–7. Mandibular second molars.

Figure 11–8. Mandibular second molar—buccal, lingual, mesial, and distal surfaces.

- The occlusal groove pattern, shown in **Figure 11–9**, is as follows:

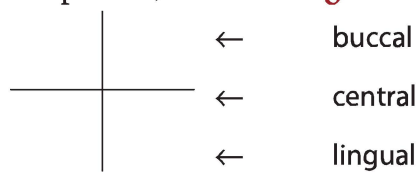

- The occlusal has more supplementary grooves.
- The mesial root has only one pulp canal.

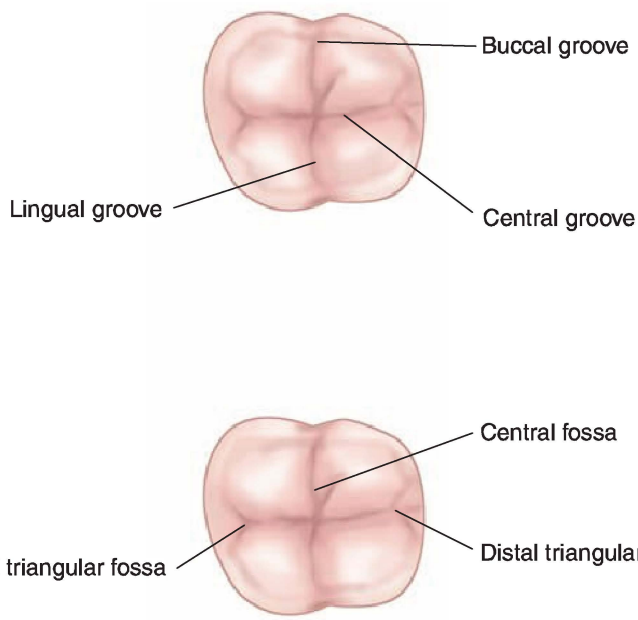

Figure 11–9. Mandibular second molar—occlusal surface.

Clinical Considerations

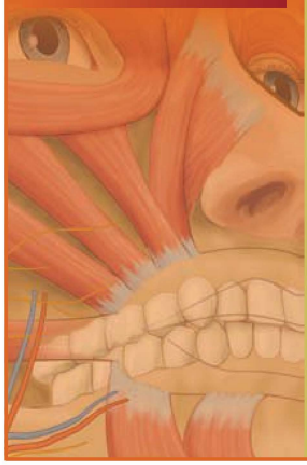

Root length: 13 mm

Root depressions: (1) On the buccal surface, the root bifurcation is 3 mm from cervical line; (2) on the lingual surface, a deep developmental groove is evident at the bifurcation; (3) on the mesial surface, a shallow depression extends from crown down the root surface; and (4) on the distal surface, a shallow depression extends most of root length.

CEJ: Very slight curvature (0–1 mm toward occlusal) on both mesial and distal surfaces

Cervical area from buccal or lingual surface: The mesial side is concave; the distal surface is straight.

Furcation: Buccal surface is 3 mm from cervical line; lingual surface is 3–4 mm from cervical line.

SUMMARY

Each mandibular quadrant has three mandibular molars. The mandibular first molar is usually the first permanent tooth to erupt, so its positioning is important for the appropriate alignment of the other permanent teeth. Thus, it is the "keystone" to the arch.

The mandibular first molar has five cusps, three buccal and two lingual; the second molar has four cusps, two buccal and two lingual.

Mandibular molars have two roots, one mesial and one distal. All teeth have one pulp canal in each root, but the mandibular first molar is often the exception. There are three pulp canals in the two roots: the mesial root has two pulp canals, and the distal root has one pulp canal. The mandibular second molar has only one pulp canal in each root.

The mandibular molars assist the maxillary molars in **mastication** and comminution.

WORKSHEET

Complete the following chart with the information requested

	Mandibular First Molar	Mandibular Second Molar
Universal Number		
Palmer's Notation		
Eruption Date		
Antagonists		
Succedaneous		
Number of Cusps		
Number of Roots		
*Identifying Features**		
Buccal		
Lingual		
Mesial		
Distal		
Occlusal Description		
Cusps		
Fossae		
Grooves		

*Size, number of cusps, location of grooves, etc.

Using the diagrams below, draw and label the grooves and fossae

Maxillary first molar

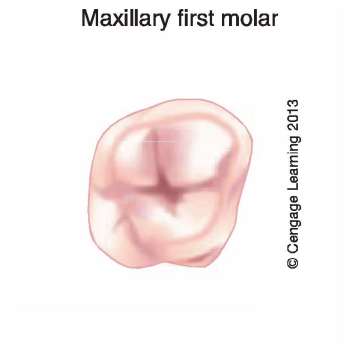

Maxillary second molar

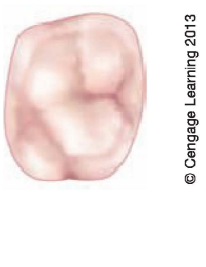

Grooves	Fossae	Ridges
Buccal	Central	Marginal
Buccal groove of central fossa	Mesial triangular	Cusp
Central	Distal triangular	Oblique
Transverse groove (first only) of the oblique ridge	Distal linear	
Distal oblique		
Lingual		
Fifth cusp groove (first only)		

Answer the following multiple-choice questions

1. The mandibular first molar usually shows first evidence of calcification at:
- **a.** birth
- **b.** 1 year of age
- **c.** 2 years of age
- **d.** 3 years of age

2. When compared to the mandibular second molar, the first has which additional cusp?
- **a.** mesiobuccal
- **b.** distobuccal
- **c.** distal
- **d.** distolingual

3. What molar has more pulp canals than roots?
- **a.** maxillary first molar
- **b.** maxillary second molar
- **c.** mandibular first molar
- **d.** mandibular second molar

4. Which deciduous tooth does the mandibular first molar replace?
- **a.** deciduous first molar
- **b.** deciduous second molar
- **c.** deciduous first premolar
- **d.** does not replace a deciduous tooth

5. Which is the correct eruption date for the mandibular second molars?
- **a.** 6–7 years
- **b.** 9–10 years
- **c.** 11–13 years
- **d.** 16 years

CHAPTER 12

Third Molars

General Information
Maxillary Third Molar Description
Mandibular Third Molar Description

Objectives

At the completion of this chapter, you will be able to:

- Identify the third molars and provide information including, universal number, function, antagonist, and other characteristics.
- Describe the location and contour of each third molar.
- Define the new terms in the chapter.
- Complete the worksheet at the end of the chapter.

Key Terms

Anomaly
Heart shape
Supplemental groove

GENERAL INFORMATION

Because both maxillary and mandibular third molars show considerable developmental variation, there is no standard structural description. These teeth, more than any of the others, are likely to be **anomalies**. Often, there is crown displacement and the roots are fused or malformed.

When the third molars develop properly, their structure will look like either the first or second molar, but they can be differentiated because they are smaller and will have numerous supplementary grooves on the occlusal surface. The root will usually be fused even when the crown is not malformed.

Third molars supplement the other molars in grinding food. Although it is not necessary to study the structure of third molars, it is helpful to examine specimens to realize their difference from other molars.

MAXILLARY THIRD MOLAR DESCRIPTION

Characteristics	
Location in the arch	Eighth tooth from midline; distal to maxillary second molar
Universal number	R-#1 L-#16
Eruption date	17–21 years
First evidence of calcification	7–9 years
Crown completion	12–16 years
Root completion	18–25 years
Function	Mastication and comminution
Length of crown	6.5 mm

Continues

Characteristics *continued*

Length of root	11 mm
Antagonists	Mandibular third molar

Location of Contact Area

Mesial Distal	Variation from middle to occlusal third

Identifying Features

- Often the crown is heart shaped
- Fused roots (three roots)
- May resemble first or second molar
- Refer to **Figure 12–1**.

MANDIBULAR THIRD MOLAR DESCRIPTION

Characteristics

Location in the arch	Eighth tooth from midline; distal to mandibular second molar
Universal number	R-#32, L-#17
Eruption date	17–21 years
First evidence of calcification	8–10 years
Crown completion	12–16 years
Root completion	18–25 years
Function	Mastication and comminution

Continues

Characteristics *continued*

Length of crown	7 mm
Length of root	11 mm
Antagonists	Maxillary second and third molars

Location of Contact Area

Mesial Distal	Variation from middle to occlusal third

Identifying Features

- Often crowns do not conform to normal size
- Often have fused roots
- When well developed, will look like first or second molar
- Refer to **Figure 12–2**.

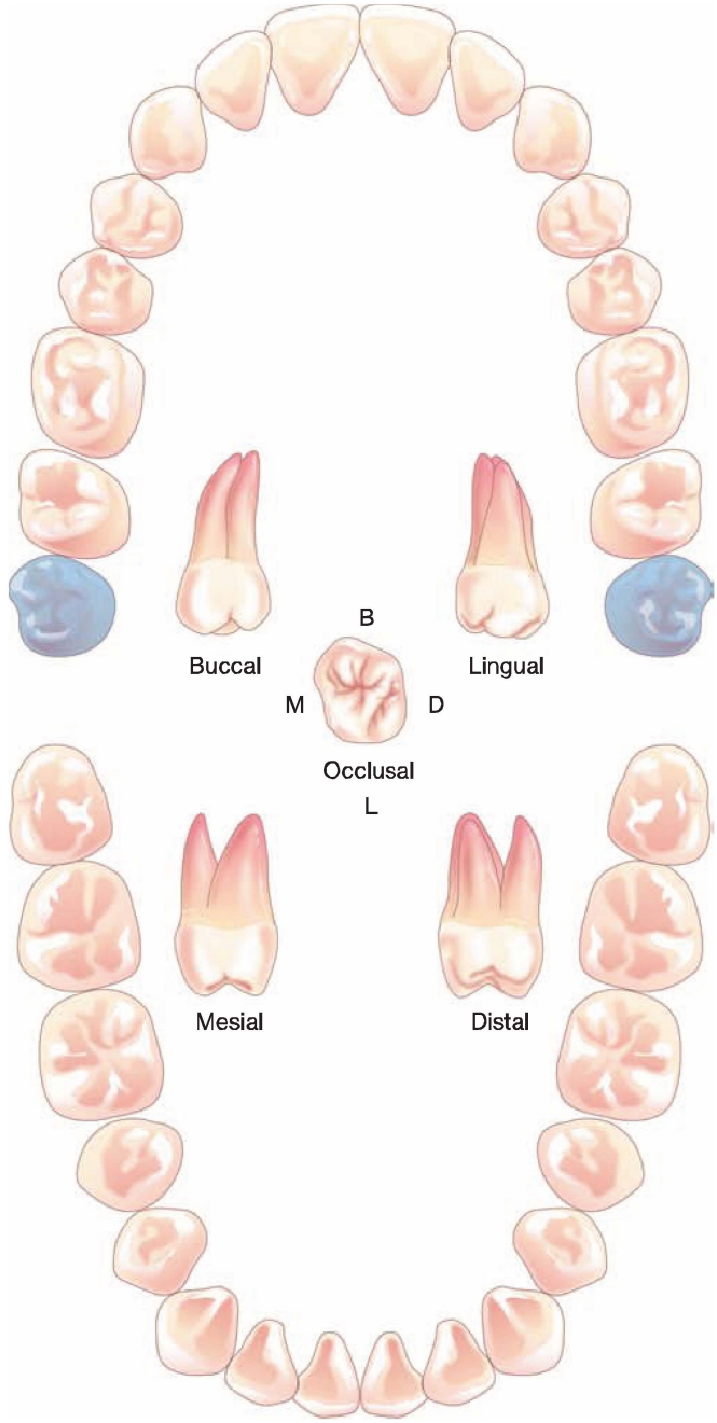

© Cengage Learning 2013

Figure 12–1. Maxillary third molars.

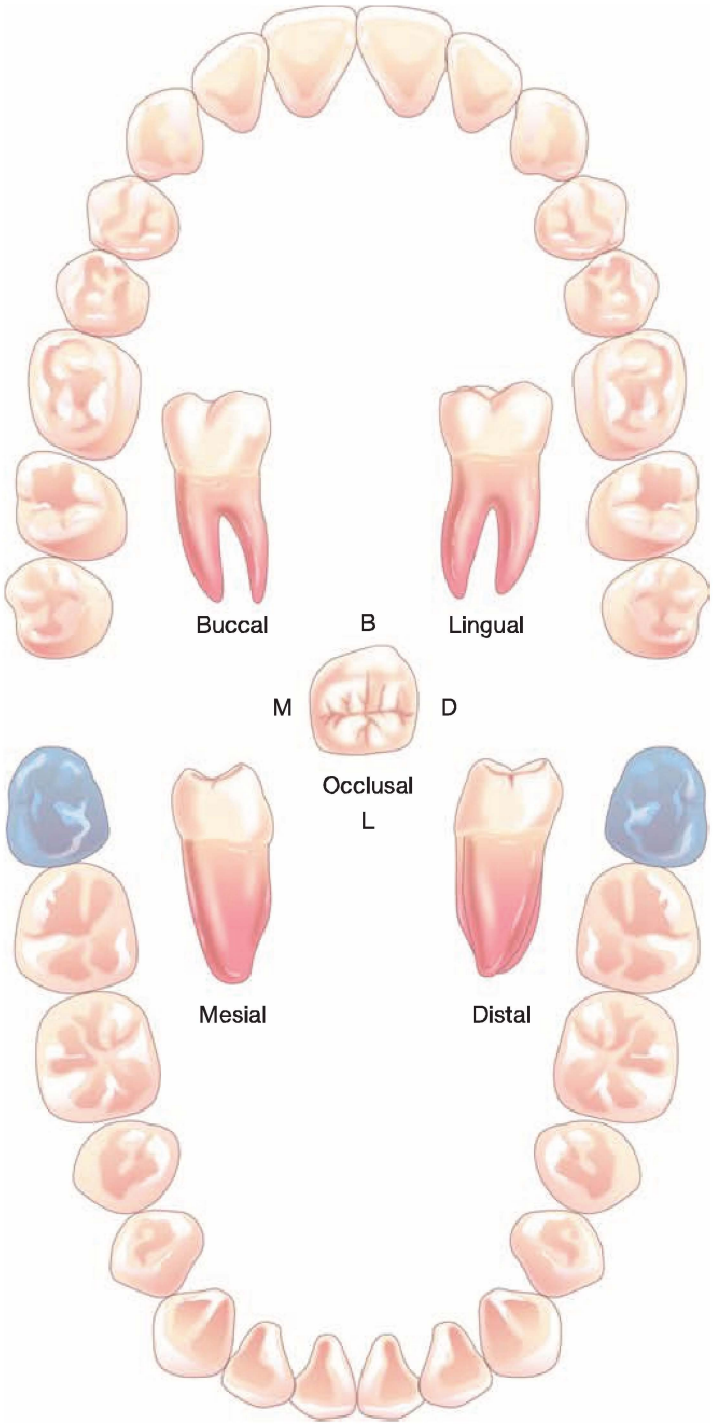

© Cengage Learning 2013

Figure 12–2. Mandibular third molars.

SUMMARY

Because of developmental variations, there is no standard description for the maxillary or mandibular third molars. When well formed, they will be smaller than but similar to the first molars in number of cusps and roots. Usually, however, the roots are fused and the crowns will have numerous **supplemental** (small, indistinct) **grooves**. Frequently, the maxillary third molar is **heart shaped**, but the mandibular third molar is often atypical.

Answer the following questions as completely as possible

1. What is the most common shape of the crown of the maxillary third molar?
2. What is a common feature of the roots of both maxillary and mandibular third molars?
3. What maxillary and mandibular third molars develop normally, what do they resemble?

Answer the following multiple-choice questions

1. Third molars frequently resemble first molars but which of the following helps to differentiate them?
   - **a.** more supplementary grooves on the occlusal surface
   - **b.** smaller size
   - **c.** often an anomaly
   - **d.** all of the above
2. Which of the following is an antagonist of the maxillary third molar?
   - **a.** mandibular first molar
   - **b.** mandibular second molar
   - **c.** mandibular third molar
3. The eruption date for the third molars is:
   - **a.** 10–12 years
   - **b.** 12–14 years
   - **c.** 17–21 years
4. A frequent atypical shape for the maxillary third molar is:
   - **a.** rhomboid
   - **b.** square
   - **c.** heart shaped

SECTION IV

Related Topics

Chapter 13 Primary Dentition
Chapter 14 Tooth Development
Chapter 15 Occlusion
Chapter 16 Form and Function

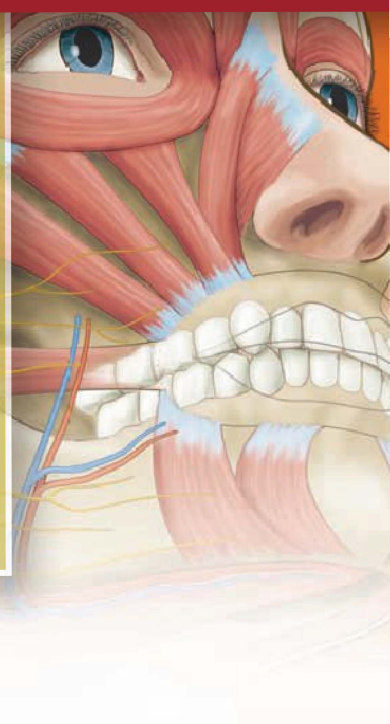

CHAPTER 13

Primary Dentition

The Names and Number of the Primary Teeth
Eruption/Exfoliation
Comparison with Permanent Teeth
Description of Primary Teeth
Importance of Primary Teeth

Objectives

At the completion of this chapter, you will be able to:

- Identify the names, number, and eruption dates of the primary teeth.
- Describe the value of the primary teeth to their function.
- Compare the primary teeth to the permanent teeth.
- Complete the worksheet at the end of the chapter.

Key Terms

Cervical ridge
Deciduous
Eruption
Exfoliation
Flared (divergent) roots
Mixed dentition
Primate spacing

THE NAMES AND NUMBER OF THE PRIMARY TEETH

There are 20 primary teeth: 10 maxillary and 10 mandibular. In each quadrant there is a central incisor, lateral incisor, canine, first molar, and second molar (**Figure 13–1**). There are no premolars in the primary dentition. Primary teeth are also referred to as **deciduous** teeth, baby teeth, milk teeth, or first teeth.

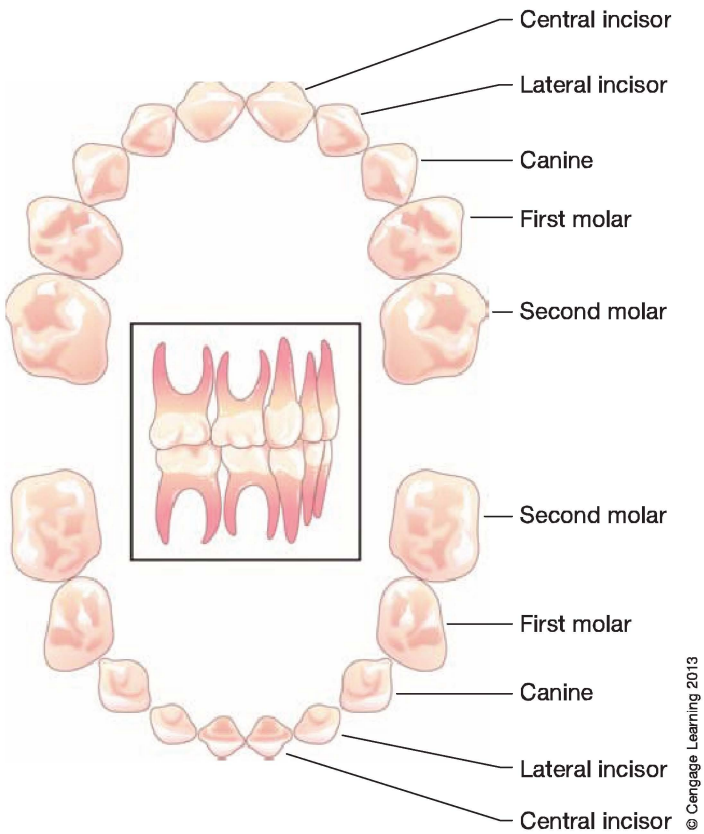

Figure 13–1. The primary dentition with tooth identification.

ERUPTION/EXFOLIATION

The period of eruption for the primary teeth occurs from 6 months to 2½–3 years of age. The specific eruption date for each tooth is listed in Appendix A. All the primary teeth usually have emerged and are in alignment by the time the child is 3 years old. Although each permanent tooth contacts its proximal tooth, there is spacing between each anterior primary tooth. This spacing, called **primate spacing**, allows for the development and growth of the larger succedaneous tooth forming in the bone beneath each primary tooth. Primate spaces are usually located between the primary maxillary lateral incisor and canine, and between the primary mandibular canine and first molar.

At 6 years, just prior to the **eruption** of the permanent mandibular central incisor, exfoliation of the primary teeth begins. The mandibular central incisors are the first to exfoliate. The **exfoliation** sequence is the same as the eruption sequence of the permanent dentition.

During the period when both deciduous and permanent teeth are present in the oral cavity, the person has a **mixed dentition**. By about 12 years of age, all primary teeth are normally replaced by permanent teeth.

COMPARISON WITH PERMANENT TEETH

All primary anterior teeth resemble their permanent counterparts although they are smaller. The primary first molars have several cusps, and although they can be identified as molars, they are not anatomically identical to any permanent tooth. All primary second molars resemble the first permanent molars.

Primary teeth have a more pronounced **cervical ridge**. In addition, the **roots** of the posterior teeth are more **flared (divergent)**, thus allowing for growth of the permanent teeth forming beneath them. Because the roots are flared, the cervix appears to be more constricted than the cervix of the permanent teeth.

The primary crowns have less enamel than do the permanent teeth, and the pulp horns extend more occlusally than on the permanent teeth. Therefore, the pulp is closer to the surface. Special consideration must be given to

reducing excessive friction when rubber cup polishing these teeth, since the heat could cause injury to the pulp.

Once you have become familiar with permanent tooth anatomy, you can more easily differentiate the primary teeth from permanent teeth in the clinical examination.

DESCRIPTION OF PRIMARY TEETH

Maxillary Incisors

The labial crown of the incisor is smooth with a straight incisal edge; there are no mamelons. The crown is wide with a cingulum and marginal ridges on the lingual (**Figures 13–2** and **13–3**).

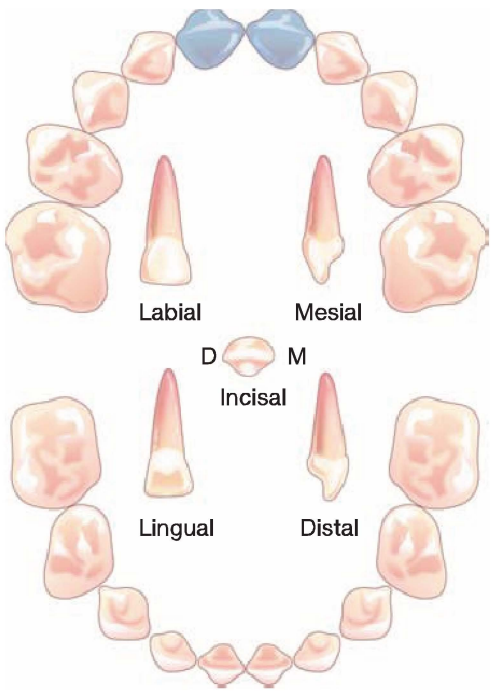

Figure 13–2. Maxillary central incisors.

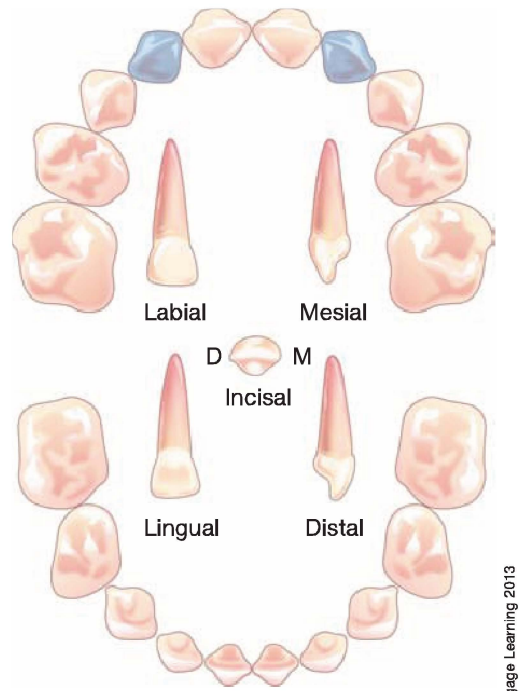

Figure 13–3. Maxillary lateral incisors.

Maxillary Canine

A broad cervical ridge on the canine causes the cervix to appear constricted. The cusp tip is pointed, but short; the root is long and slender (**Figure 13-4**).

Maxillary First Molar

The number of cusps varies from 2 to 4. There is no groove on the buccal surface to divide the cusps.

The occlusal surface has a central fossa and a mesial triangular fossa connected by a central groove. There are three roots on all maxillary molars, and the bifurcation of the two buccal roots begins almost apically to the cervix (**Figure 13–5**).

Maxillary Second Molar

The anatomy is the same as that of the permanent maxillary first molar. There are two buccal cusps divided by a buccal groove and two lingual cusps with a cusp of Carabelli, or fifth cusp groove, on the mesiolingual cusp. There are three roots: two buccal, one lingual (**Figure 13–6**).

MANDIBULAR INCISORS

Both labial and lingual surfaces are smooth, although there is a slight cingulum and marginal ridges on the lingual (**Figures 13–7** and **13–8**).

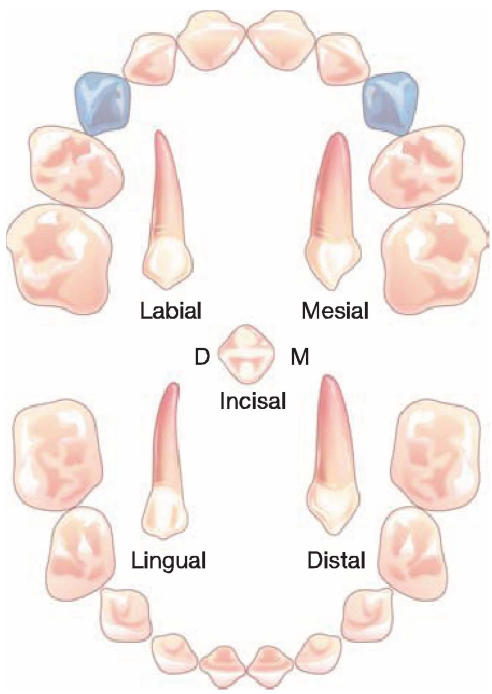

Maxillary deciduous canines (cuspids)

Figure 13–4. Maxillary canines.

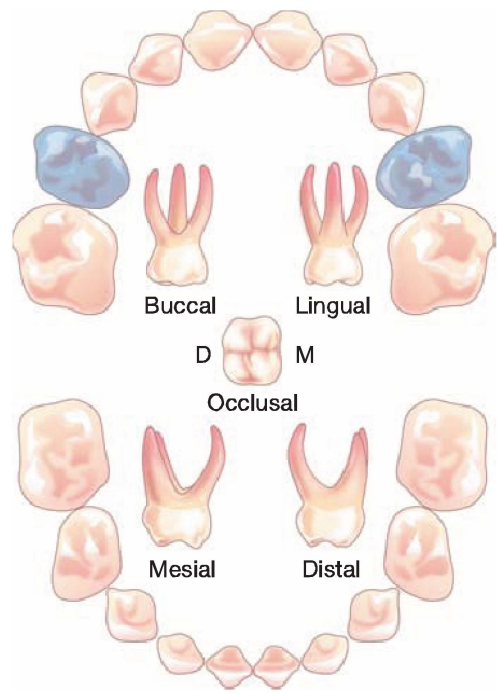

Maxillary deciduous first molars

Figure 13–5. Maxillary first molars.

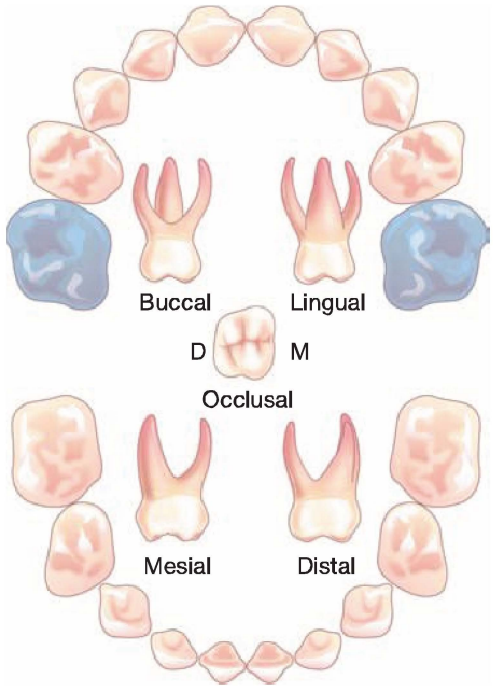

Maxillary deciduous second molars

Figure 13–6. Maxillary second molars.

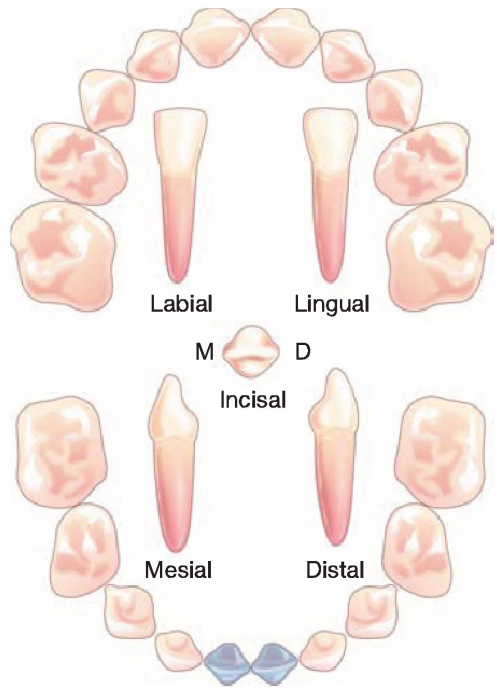

Mandibular deciduous central incisors

Figure 13–7. Mandibular central incisors.

Mandibular Canines

The buccal surface has a pronounced cervical ridge. The lingual surface has a cingulum and lingual ridges (**Figure 13–9**).

Mandibular First Molar

As with the maxillary first molar, there is no definite anatomy. Usually there are two buccal cusps divided by a depression, rather than a groove, and two lingual cusps. There are two roots; both are long, slender, and divergent. The occlusal surface has a central groove crossed by the buccal groove and a lingual groove (**Figure 13–10**).

Mandibular Second Molar

The anatomy is identical to that of the permanent mandibular first molar. Grooves divide the three buccal cusps and the two lingual cusps. The occlusal groove pattern is also the same as that on the permanent mandibular first molar, although there may be more supplemental grooves. There are two long, thin, divergent roots, which can be twice as long as the crown (**Figure 13–11**).

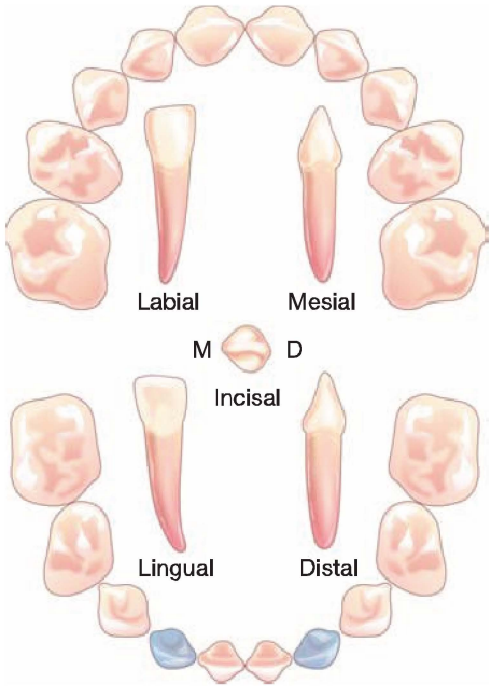

© Cengage Learning 2013

Mandibular deciduous lateral incisors

Figure 13–8. Mandibular lateral incisors.

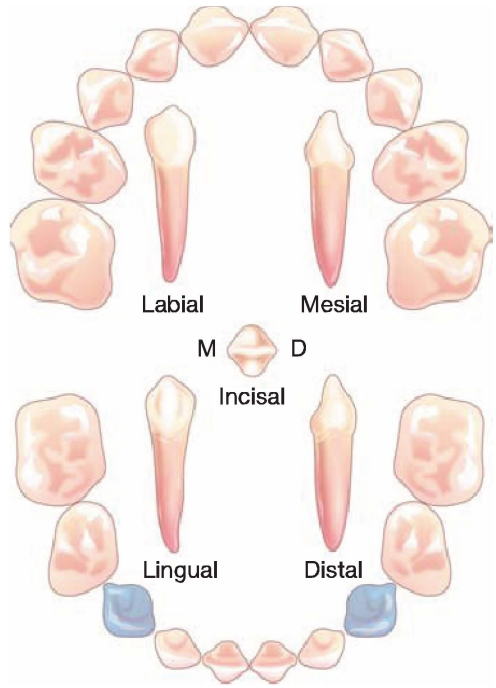

© Cengage Learning 2013

Mandibular deciduous canines (cuspids)

Figure 13–9. Mandibular canines.

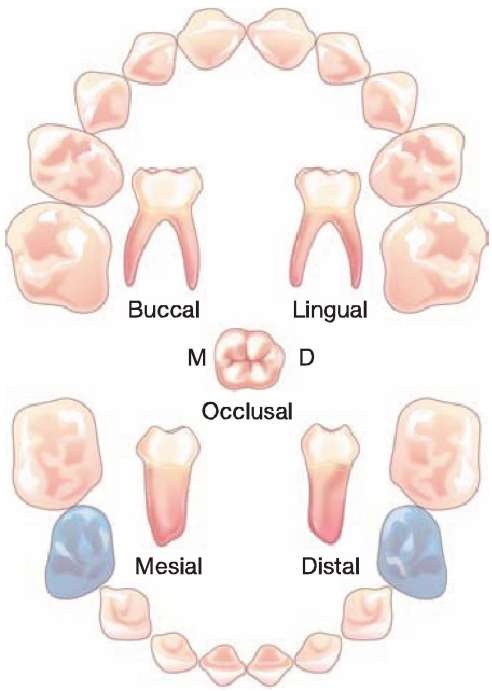

© Cengage Learning 2013

Mandibular deciduous first molars

Figure 13–10. Mandibular first molars.

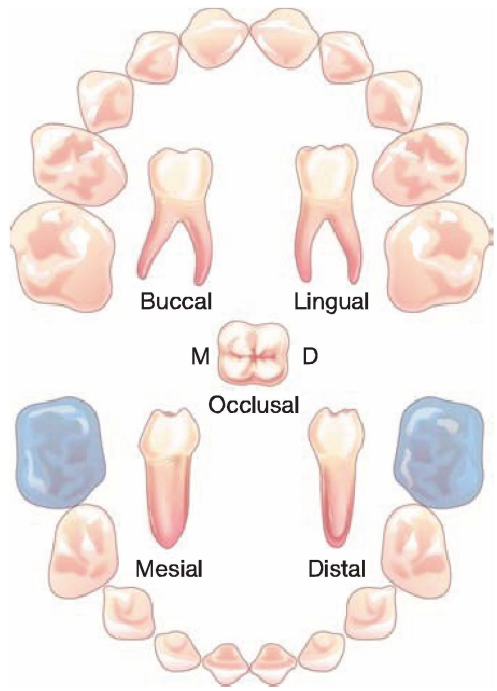

© Cengage Learning 2013

Mandibular deciduous second molars

Figure 13–11. Mandibular second molars.

IMPORTANCE OF PRIMARY TEETH

Both the form and function of the primary dentition are important. Each primary tooth has the same function as the permanent tooth that succeeds it, and each maintains a position for its permanent tooth replacement. If prematurely lost, the permanent replacement may erupt too early or emerge in an incorrect position. This may result in improper alignment and cause future malocclusion and periodontal problems. Because of these factors, it is important to stress care and maintenance of the primary teeth with the patient. The deciduous molars must be in a condition to function for 10 to 12 years. The development of good dental habits during these early years will result in a healthier permanent dentition.

SUMMARY

The primary dentition includes 10 maxillary and 10 mandibular teeth. Eruption begins around the 6th month of life and is completed between 2½ and 3 years. Each primary tooth resembles its succeeding permanent tooth but is proportionately smaller. The posterior teeth have flared roots that allow for concurrent growth of the permanent teeth growing directly below.

The primary teeth are an important part of the dentition; each of these teeth has a necessary function. It is important that they are cared for so that they endure until their natural exfoliation.

Review the eruption sequence of the deciduous teeth. List the teeth in the correct sequence of eruption

_____

_____

_____

_____

_____

_____

_____

_____

_____

Answer the following multiple-choice questions

1. The deciduous mandibular second molar has the same anatomy as the permanent:

- **a.** mandibular first molar
- **b.** mandibular second molar
- **c.** mandibular first premolar
- **d.** mandibular second premolar

2. The first deciduous tooth erupts at age:

- **a.** 3 months
- **b.** 6 months
- **c.** 12 months
- **d.** 14 months

3. Which of the following teeth are not part of the deciduous arch?

- **a.** four incisors
- **b.** two canines
- **c.** four premolars
- **d.** four molars

4. Which of the following characteristics of the deciduous teeth is different from the permanent teeth?

a. smaller

b. more pronounced cervical ridge

c. more divergent roots

d. all of the above

5. The normal spacing between deciduous anterior teeth is referred to as:

a. primate spacing

b. primate dentition

c. space maintenance

d. contact spacing

CHAPTER 14

Tooth Development

Introduction
Growth and Development
Eruption
Developmental Anomalies

Objectives

At the completion of this chapter, you will be able to:

- Describe the development of the tooth during the following stages: growth (initiation, proliferation, histodifferentiation, and morphodifferentiation), apposition, and calcification.
- Define active and passive eruption, proliferation, histodifferentiation, morphodifferentiation, apposition, supernumerary, and anomaly.
- Complete the worksheet at the end of the chapter.

Key Terms

Active eruption
Anomaly
Apposition
Calcification
Ectoderm
Endoderm
Histodifferentiation
Initiation
Mesoderm
Morphodifferentiation

Continues

Key Terms *continued*

Passive eruption
Proliferation
Stomodeum
Supernumerary

GENERAL INFORMATION

The development of a human begins with an embryo, which has three layers: the **ectoderm**, the **mesoderm**, and the **endoderm**. The ectoderm will form not only the outer covering of the body but also the lining of the oral cavity. The skeletal and muscular systems, as well as other structures including the cementum, dentin, and pulp of the tooth, form from the mesoderm. The lining of the internal organs develops from the endoderm.

During the third week of fetal life, when the embryo is only 3 mm long, the face begins its development. At one end of the embryo there is an invagination of the ectoderm forming the **stomodeum**, or primitive mouth, which later becomes the oral and nasal cavities.

The primitive mouth is lined with ectoderm and becomes the oral epithelium. Beneath this is the mesenchyme, developed from mesoderm, which becomes the underlying connective tissue.

Between the fifth and sixth week in utero, the first sign of tooth development is evident. Teeth are formed from the ectoderm and mesoderm in a complex histologic process simplified into the following pattern.

GROWTH AND DEVELOPMENT

The growth stage is defined by an increase in the number and size of the cells (**Figure 14–1**). The formation of the teeth is a progression that begins during the fifth or sixth week in utero with the formation of the primary mandibular anterior teeth, followed shortly by the development of the primary maxillary anterior teeth. This developmental process continues, posteriorly, until 10 maxillary and 10 mandibular teeth are formed. Permanent teeth begin forming about the fourth or fifth month of fetal life but do not calcify until after birth.

Initiation—Bud Stage

The first stage of *odontogenesis* (origin of the tooth) is referred to as the *bud stage* (**Figure 14–1A**). During this stage, initiation takes place. **Initiation** is when the tooth begins formation from the *dental lamina*. The dental lamina is a growth from the oral epithelium that gives rise to the tooth buds. Therefore, on a deciduous dentition, 10 growths on each arch are apparent or 10 buds later become the primary teeth. The first sign of a developing tooth is noted during the embryonic phase in the area that will eventually be the lower mandibular anterior region of the child's oral cavity. The permanent teeth develop in a similar manner. Each arch has 16 different buds developing into one tooth each. The last three molars in each quadrant develop behind the primary dentition. The 6-year molar begins developing at birth, the 12-year molar starts developing when the baby is about 6 months old, and the third molars (wisdom teeth) start when the child is approximately 5 years of age.

Proliferation—Cap Stage

The bud of the tooth grows and changes shape during the cap stage (**Figure 14–1B**). The organ is indented on the lower side and appears much like a cap, therefore the name *cap stage*. The primary embryonic ectoderm layer that has developed into the oral epithelium matures into the enamel of the developing tooth. The processes of **proliferation**, when the cells multiply, and **histodifferentiation**, when the cells develop into different tissues, take place along with early **morphodifferentiation**, when the cells begin to outline the future shape of the developing organ. During this process, the primary embryonic mesoderm layer develops into connective tissue that is referred to as the *mesenchyme* tissue. This connective tissue forms an enclosed area, referred to as a *dental sac*, and further matures into the dentin, cementum, and the pulp of the tooth. A portion of the mesenchyme surrounds the outside of the enamel organ, the cementum, and the periodontal ligament of the tooth.

Morphodifferentiation/Histodifferentiation—Bell Stage

Further specialization of the cells, or histodifferentiation, takes place in the bell stage (**Figure 14–1C**). The inner epithelium of the enamel organ becomes *ameloblasts,* enamel-forming cells. The peripheral cells of the dental papilla become *odontoblasts*, cells that form dentin. The *cementoblasts*, cementum-forming

cells, form from the dental sac. Continued morphodifferentiation takes place, forming the organ into a shape that resembles a bell (**Figure 14–1D**).

Apposition—Maturation State

The odontogenesis reaches completion in these final stages (**Figure 14–1E**). The tissues of enamel, dentin, and cementum are formed in layers and fused together in the appropriate manner. The process of depositing calcium salts and other minerals in the formed tooth takes place during the **apposition** stage. This process is called **calcification** (**Figure 14–1F**).and is the last developmental state prior to *eruption* (**Figure 14–1G**) of the tooth. The final stage of the life cycle of the tooth is *attrition*, or the wearing away of the incisal or occlusal surfaces of the tooth during normal function (**Figure 14–1H**).

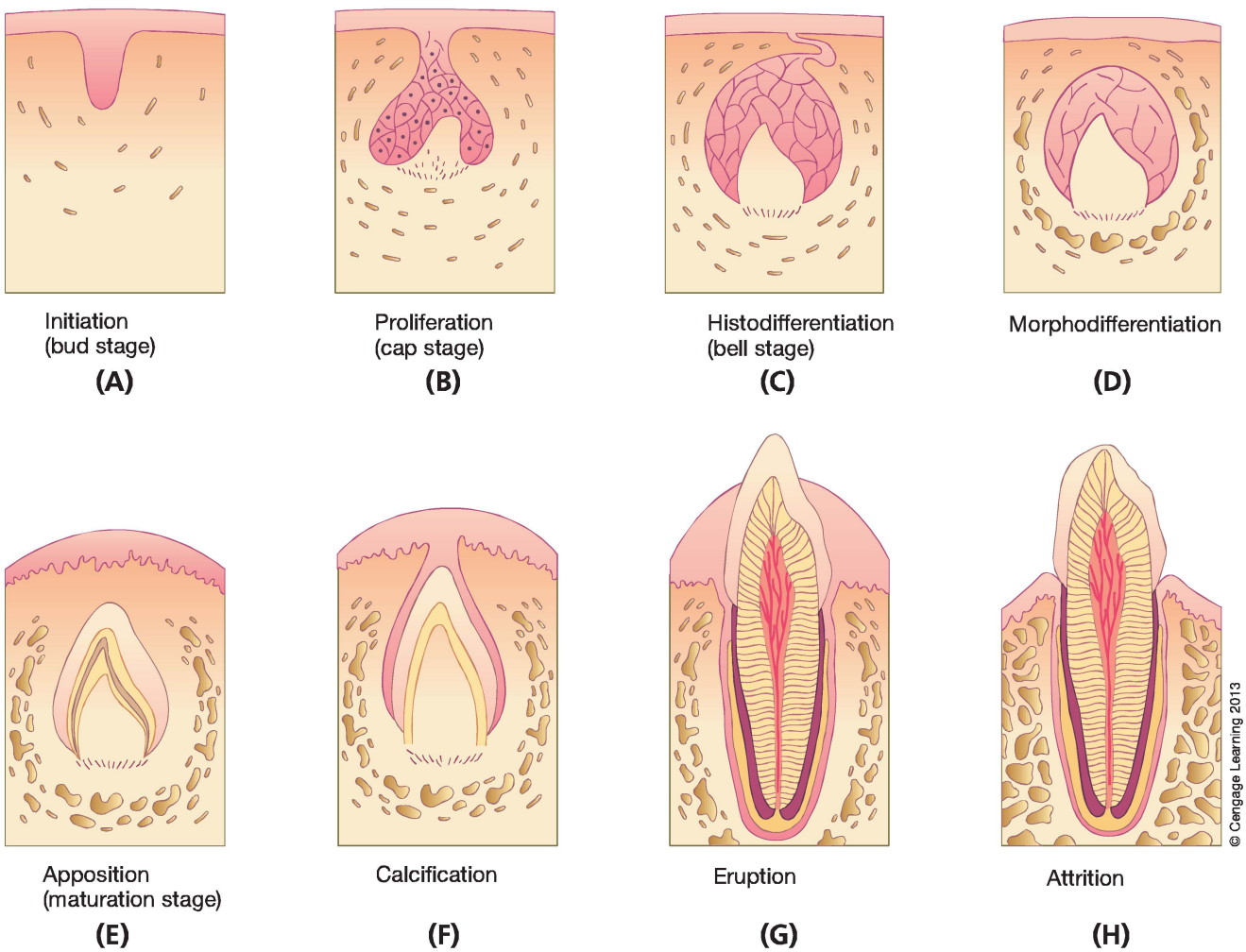

Figure 14–1. (A) Initiation (bud stage). (B) Proliferation (cap stage: begins proliferation, histodifferentiation, and morphodifferentiation). (C) Histodifferentiation. (D) Morphodifferentiation. (E) Apposition (maturation stage). (F) Calcification. (G) Eruption. (H) Attrition.

The root of the tooth does not develop fully prior to eruption. Eruption is the phase when the tooth passes through the bone and the oral mucosa and into its place in the oral cavity. Twenty of the permanent teeth are located below and distal to the primary teeth. As the permanent teeth erupt, they apply pressure to the apices of the roots of the primary teeth. During this force, *osteoclasts*, bone resorption cells, dissolve the root of the primary tooth. This resorption first takes place at the apex and continues up toward the crown of the tooth. When very little of the root structure of the primary tooth is left, the tooth loosens because of lack of support. Children often assist in the final stages of loosening the tooth by moving it back and forth until they break the attaching fibers.

The primary teeth occupy and maintain space in the dental arches for the permanent teeth and act as guides during the eruption process. If the primary teeth are removed early, the spaces may be diminished, causing crowding when the permanent teeth erupt.

ERUPTION

Eruption is the movement of the tooth from its position within the jaw to its position in the oral cavity The process is divided into active and passive eruption.

Active Eruption

This is the process whereby the crown of the tooth first moves from within the jaw into the oral cavity, a process that continues until the tooth meets its antagonist in the opposite jaw. **Active eruption** begins when the crown of the tooth is complete and a portion of the root has started to form. When the tooth emerges into the oral cavity, only a portion of the root has formed, as previously described.

It will take 1½ to 3 years for the completion of a deciduous root and about 3 years after eruption for the completion of a permanent root. The entire process of permanent tooth development, from initiation to completion, takes about 10 years.

By the time a primary tooth erupts, its succedaneous replacement, the permanent tooth, has begun forming. With the exception of the permanent molars, this occurs beneath the root(s) of the deciduous tooth. Again, refer to the chart on tooth development in Chapter 1 for a review of the growth rate

of teeth. Note that the first permanent molars begin calcifying after birth and develop in the area posterior to the second deciduous molars.

Passive Eruption

Once active eruption is complete, other factors that occur during life, such as wear from use or trauma, can cause attrition or breakdown on the periodontium. In turn, there can be exposure of cementum, wearing of the enamel, or gingival recession. The increase in the length of the clinical crown caused by gingival recession is referred to as **passive eruption**.

DEVELOPMENTAL ANOMALIES

Disturbances in the development stage of the teeth and bones can cause abnormalities. Hereditary or nutritional factors, such as excessive amounts of fluoride, may cause an **anomaly**, or deviation in the development of the teeth.

For example, any disturbance or interference in the fusion of the right and left maxillary process can result in a cleft of the palate. Disturbances during the formation of the tooth structure can cause faulty enamel or alteration of the shape of the tooth. Examples of this are enamel dysphasia, fluorosis, or peg-shaped lateral incisors. Occasionally, there may be an extra tooth that has formed, called a **supernumerary** tooth. It is helpful to review oral-histology literature detailing the explanation of the causes of various tooth abnormalities in order to more clearly understand when and how these deviations occur.

SUMMARY

Between the fifth and sixth week in utero, there is evidence of tooth development. An increase in growth and development of the cells continues until the entire tooth is formed, a process that lasts 2 to 3 years for the primary teeth and 9 to 10 years for the permanent teeth. Once a tooth is formed, it cannot repair itself as bones and skin do. It is necessary to provide a proper diet during tooth formation and preventive care after eruption so that the teeth will last a lifetime.

Number each stage of development in the order it occurs, and describe what occurs at each stage

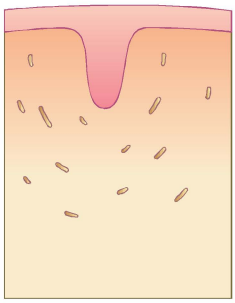

Initiation
(bud stage)

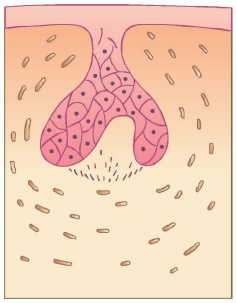

Proliferation
(cap stage)

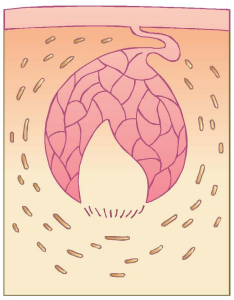

Histodifferentiation
(bell stage)

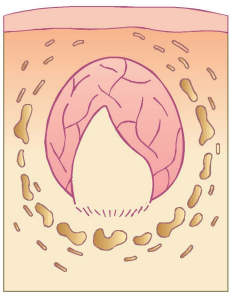

Morphodifferentiation

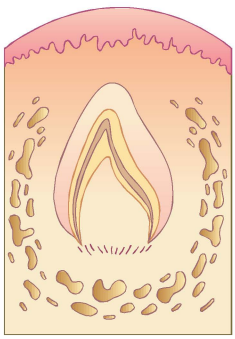

Apposition
(maturation stage)

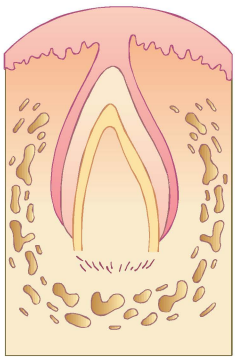

Calcification

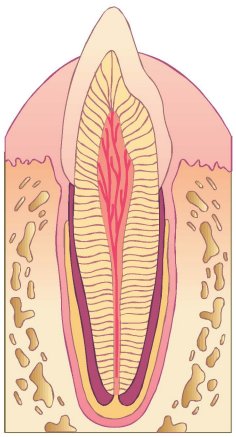

Eruption

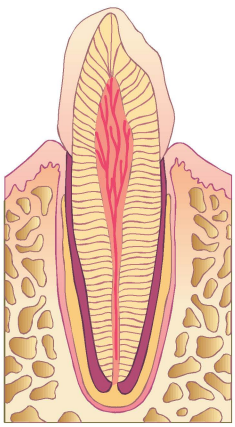

Attrition

© Cengage Learning 2013

Answer the following multiple-choice questions

1. Which embryonic layer forms the teeth?:
   - **a.** ectoderm
   - **b.** mesoderm
   - **c.** endoderm
2. The primitive mouth begins formation at approximately:
   - **a.** 3 weeks in utero
   - **b.** 4 weeks in utero
   - **c.** 5 weeks in utero

3. The enamel organ forms during:
- **a.** initiation
- **b.** proliferation
- **c.** histodifferentiation
- **d.** morphodifferentiation

4. The final stage of tooth formation is:
- **a.** proliferation
- **b.** histodifferentiation
- **c.** morphodifferentiation
- **d.** apposition

5. The process whereby the tooth moves into the oral cavity until it meets its antagonist is:
- **a.** active eruption
- **b.** passive eruption
- **c.** apposition
- **d.** differentiation

CHAPTER 15

Occlusion

General Information
Ideal Occlusion
Normal Occlusion
Malocclusion
Occlusal Deviations
Angle's Classification of Occlusion
Related Terms
Primary Teeth Occlusion

Objectives

At the completion of this chapter, you will be able to:

- Describe Angle's classification of occlusion.
- Describe five occlusal deviations that affect a group of teeth, and explain the importance of primary teeth spacing on the occlusion of permanent teeth.
- List and explain five deviations of individual tooth positioning.
- Describe three types of facial profiles.
- Define the following terms: ideal occlusion, normal occlusion, malocclusion, centric occlusion, centric relation, terminal mesial step, terminal plane, and primate spacing.
- Complete the worksheet at the end of the chapter.

Key Terms

Angle's classification
Buccoversion
Centric occlusion
Centric relation
Crossbite
Edge to edge
End to end
Ideal occlusion
Infraversion
Labioversion
Linguoversion
Malalignment
Malocclusion
Masticatory system
Mesognathic
Normal occlusion
Occlusion
Openbite
Overbite
Overjet
Prognathic
Retrognathic
Supraversion
Torsoversion
Underjet

GENERAL INFORMATION

Occlusion occurs when the maxillary and mandibular teeth contact each other in any functional relationship. The study of occlusion is concerned with all the factors involved in the development, stability, and function of the **masticatory system**, not only with the contacting of the teeth. The masticatory system includes the teeth and surrounding structures, jaws, temporomandibular joint (TMJ), muscles, lips, tongue, and related nerves and blood vessels. Thus, the study of occlusion can be complex, extending beyond the arrangement of the teeth to include areas such as growth and development of the entire masticatory system—that is, genetic as well as environmental factors.

Occlusion first occurs after the eruption of the primary dentition. The sequence of eruption, spacing, and positioning of the teeth as well as the relationship of the jaws can be critical to occlusion, particularly if they vary significantly from the normal. The final occlusal relationship of the permanent dentition is a result of the influence of hereditary and environmental factors such as trauma, oral habits, or faulty dental treatment.

IDEAL OCCLUSION

Ideal occlusion implies a complete, harmonious relationship of the teeth, as well as of all other structures involved in the masticatory system (**Figure 15–1**). In an ideal anatomic occlusal relationship, as S. Ramfjord and M. Ash have noted, the teeth conform to a specific pattern that includes 138 occlusal contacts in the closure of the 32 permanent teeth. This ideal relationship, however, rarely exists.

When the maxillary and mandibular teeth are in an ideal position, the maxillary teeth facially overlap the mandibular teeth by one-third, and each maxillary tooth has a distal relationship to its mandibular counterpart by the distance of about one-half a tooth. Lingual cusps of maxillary posterior teeth occlude in specific fossae of mandibular teeth. An intercusp relationship such as this is referred to as *interdigitation*.

Ideal occlusion is noted, also, by the positioning of the permanent first molars and canines. The mesiobuccal cusp of the maxillary first molar will be positioned in the mesiobuccal groove of the mandibular first molar. And the maxillary canine will occlude in the middle of the mandibular canine and the mandibular first premolar.

© Cengage Learning 2013

Figure 15–1. Permanent teeth in occlusion.

NORMAL OCCLUSION

As ideal occlusion seldom occurs, **normal occlusion** conforms closely to an ideal occlusal relationship but involves some variations from it. With normal occlusion, variations are considered optimum if there is functional comfort and stability of alignment. Normal or optimum occlusion is needed to maintain or protect the periodontium and/or TMJ, as well as for stabilization of alignment and aesthetics.

It is necessary that each tooth be able to withstand the forces exerted during mastication. The biting force of the posterior teeth is about 100 to 170 pounds. According to Ralph W. Phillips in *Elements of Dental Materials*, this represents 28,000 pounds per square inch or 300 pounds of pressure exerted by pressing down on a point with a medium-sharp pencil. In proper occlusion, each tooth has an appropriate opposing contact. A malpositioned tooth can cause improper distribution of stress, resulting in a breakdown of the periodontium and/or TMJ pathology.

According to Dr. Edward Angle, in a normal relationship, the first permanent molars are considered the key to occlusion and their position is the same as an ideal occlusion: the mesiobuccal cusp of the maxillary first molar rests in the mesiobuccal groove of the mandibular first molar.

MALOCCLUSION

Any deviation from ideal positioning of the teeth, whether it is a minor deviation of one tooth or a severe variation involving several teeth or the jaws, creates a **malocclusion**. The best-known system for classifying malocclusions was first described by Dr. Angle in 1898. His system is based on the mesiodistal relationship of the maxillary and mandibular first molars and canines to each other—the maxillary first molar being his "key" to occlusion. Any variation in this relationship constitutes a malocclusion.

OCCLUSAL DEVIATIONS

Malocclusion or **malalignment** can affect an individual tooth or several teeth (refer to **Table 15–1**). Occlusal deviations involving several teeth are:

- **Openbite**—an existing space between the mandibular and maxillary teeth, and can be either of the following:
  - **a.** Anterior
  - **b.** Posterior—unilateral or bilateral

TABLE 15–1. Malpositions of Groups of Teeth

TERM	DESCRIPTION	ILLUSTRATION
Anterior crossbite	Abnormal relationship of a tooth or a group of teeth in one arch to the opposing teeth in the other arch; in anterior crossbite, the maxillary incisors are positioned lingually to the opposing mandibular incisors	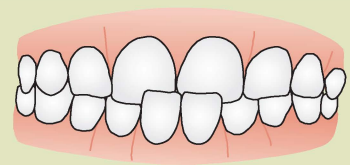 © Cengage Learning 2013
Posterior crossbite	Abnormal relationship of teeth in one arch to the opposing teeth in the other arch; in posterior crossbite, the primary or permanent maxillary posterior teeth are positioned lingually to the mandibular teeth	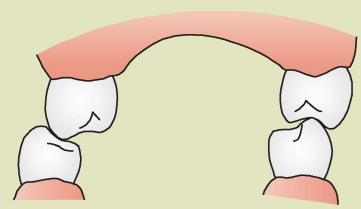 © Cengage Learning 2013
Edge-to-edge bite	Incisal surfaces of maxillary anterior teeth meeting the incisal surfaces of mandibular anterior teeth	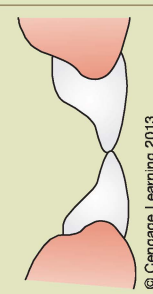 © Cengage Learning 2013
End-to-end bite	Maxillary posterior teeth meeting mandibular posterior teeth	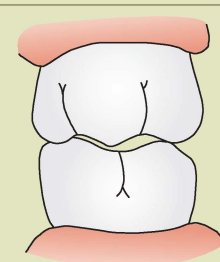 © Cengage Learning 2013

Continues

TABLE 15–1. Malpositions of Groups of Teeth *continued*

Openbite	Cusp to cusp instead of in the normal fashion; failure of the maxillary and mandibular to occlude (meet)	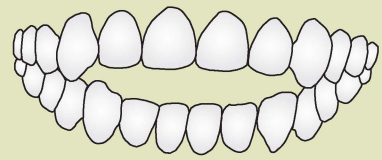
Overjet (horizontal overlap)	An abnormal horizontal distance between the labial surface of mandibular anterior teeth and the labial surface of maxillary anterior teeth	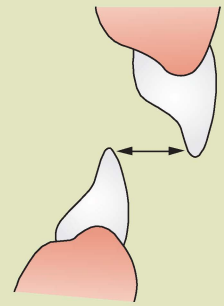
Overbite (vertical overlap)	Normally, the maxillary teeth extend vertically over the incisal one-third of the mandibular anterior teeth; when the vertical overlap is greater than this, the person is said to have an overbite	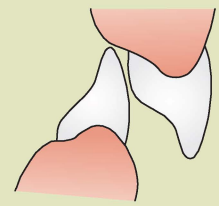
Underjet	Maxillary anteriors positioned lingually to mandibular anteriors with excessive space between labial of maxillary anteriors and lingual of mandibular anteriors	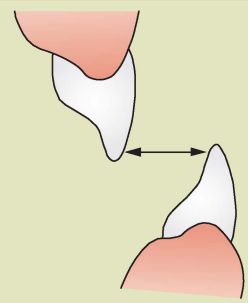

© Cengage Learning 2013

- **Overbite**—a deep or vertical overlap of the maxillary teeth onto the mandibular teeth that exceeds the normal, or one-third the depth of the mandibular incisors
- **Overjet**—a horizontal overlap creating a protrusion or space between the labial surface of the mandibular incisors and the lingual surface of the maxillary incisors
- **Crossbite**—a facially positioned mandibular tooth, or teeth, which can be either of the following:
  - **a.** Anterior
  - **b.** Posterior—buccal or lingual

- **Edge to edge** or **end to end**—a contacting of the incisal edges or cusp tips rather than an interdigitation of cusp and fossae, which is actually a crossbite or precrossbite condition
- **Underjet**—a horizontal relationship where the maxillary anteriors are lingual to the mandibular anteriors

Occlusal deviations involving individual teeth are:

- **Labioversion** or **buccoversion**—a tooth positioned more facially than normal (**Figure 15–2**)
- **Linguoversion**—a tooth positioned more lingually than normal (**Figure 15–3**)
- **Infraversion**—a tooth positioned below the plane of occlusion (**Figure 15–4**)
- **Supraversion**—a tooth positioned above the plane of occlusion (**Figure 15–5**)
- **Torsoversion**—a rotated tooth (**Figure 15–6**)

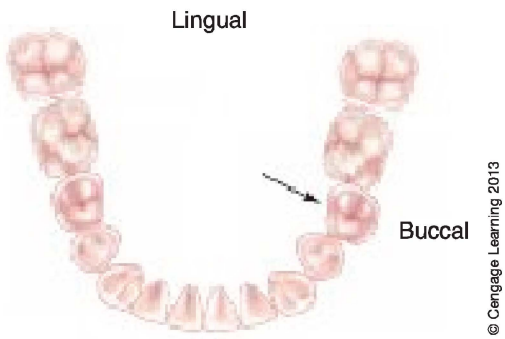

Figure 15–2. Buccoversion.

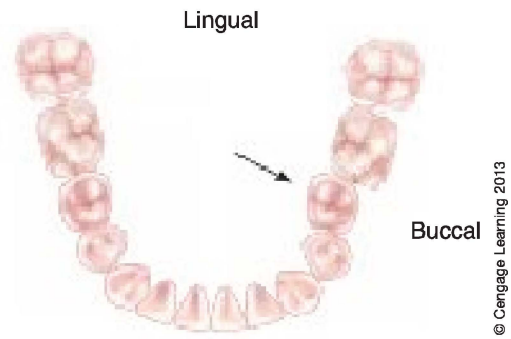

Figure 15–3. Linguoversion.

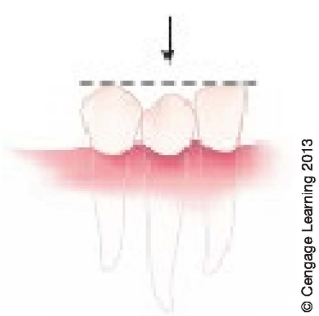

Figure 15–4. Infraversion.

Figure 15–5. Supraversion.

Figure 15–6. Torsoversion.

ANGLE'S CLASSIFICATION OF OCCLUSION

Dr. Angle was the first to develop a system to classify malocclusion. Because the mandible is movable, **Angle's classification** relates to the anterior-posterior or mesiodistal deviations in relation to the first molar. There are three classifications (see **Table 15–2**).

Class I—Neutrocclusion (Normal)

Both the permanent first molar and canine relationship are in ideal position. The mesiobuccal cusp of the maxillary first molar rests in the mesiobuccal groove of the mandibular first molar, and the maxillary canine occludes with the distal inclined plane of the mandibular canine and the mandibular first premolar.

In a Class I relationship, there can be deviations of a single tooth or several anterior teeth such as an overjet or overbite, but the molars will have ideal positioning.

TABLE 15–2. Angle's Classifications of Malocclusion and Facial Profiles

CLASS NAME	MOLAR RELATIONSHIP	DESCRIPTION	ILLUSTRATION	FACIAL PROFILE
Neutrocclusion	Mesiobuccal cusp of maxillary first permanent molar occludes with the buccal groove of mandibular first permanent molar	Similar to normal occlusion with individual teeth or groups of teeth out of position	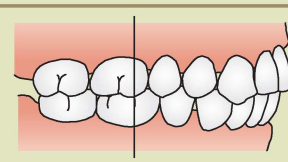 Class I	Mesognathic
Distocclusion	Buccal groove of the mandibular first permanent molar is distal to mesiobuccal cusp of maxillary first permanent molar	Division 1—maxillary teeth in labioversion	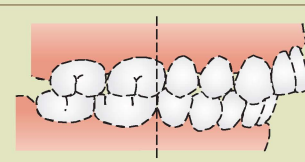 Class II, Division 1	 Retrognathic

Continues

TABLE 15–2. Angle's Classifications of Malocclusion and Facial Profiles *continued*

CLASS NAME	MOLAR RELATIONSHIP	DESCRIPTION	ILLUSTRATION	FACIAL PROFILE
		Division 2—linguoversion of mandibular teeth	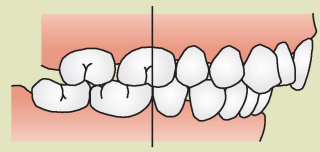 Class II, Division 2	
Mesiocclusion	Buccal groove of the mandibular first permanent molar is mesial to mesiobuccal cusp of maxillary first permanent molar	Mandibular teeth mesial to normal position	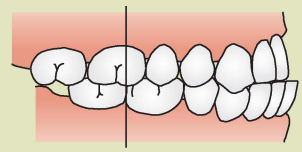 Class III	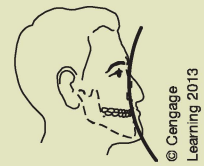 Prognathic

© Cengage Learning 2013

Class II—Distocclusion

In a Class II relationship, the mandibular first permanent molar and canine are distal—that is, more posterior, by at least the width of a premolar, than the ideal position. Even when the molars are in a more distal position, other deviations can occur, creating two divisions within a Class II occlusion.

DIVISION I

This is a protrusion of incisors or overjet; overbite, crowding, or a labial inclination of the maxillary incisors.

DIVISION II

This is a protrusion of the maxillary lateral incisors; a retrusion of the maxillary central incisors.

A Class II malocclusion can occur on one side of the arch while the other side remains a Class I.

Class III—Mesiocclusion

In a Class III relationship, the permanent mandibular first molar and canine are mesial—that is, more anterior, by at least the width of a premolar, than the normal position. When the molars are more mesially located, there are other

conditions that can also occur such as an anterior crossbite or edge-to-edge contact of the anterior teeth.

Although it was developed almost 100 years ago, Angle's classification remains the most popular method of classifying malocclusions today. However, this classification is based solely on clinical examination. With the development of other techniques to diagnose true malocclusions, principally that of cephalometric radiographs and analyses, today's definitions of malocclusions go far beyond the relationship of maxillary and mandibular teeth to each other. These include the mesiodistal and anterior-posterior relationship of the mandible and maxilla to each other and to some fixed reference point, namely, the cranial bone. Today, the classification of malocclusion is more complicated becauses it considers not only dental anomalies but also skeletal and developmental deviations, together with soft tissue and nasal and oral airway influences.

RELATED TERMS

Profiles: **Mesognathic** describes the normal profile (**Table 15–2**). When the mandible protrudes it is called **prognathic** (**Table 15–2**); when the mandible retrudes it is called **retrognathic** (**Table 15–2**).

Centric occlusion: This refers to the relationship of the occlusal surfaces of one arch to those in the opposing arch. The posterior teeth are closed; the anterior teeth have a very light or no contact.

Centric relation: This refers to the most retruded position of the condyle in the mandibular fossa.

Mastication: Mastication is the process whereby food is chewed. Food is chewed first on one side of the mouth and then shifted to the other side. The posterior teeth, with assistance of the cheeks, tongue, and lips, perform the major portion of this work.

Functional malocclusion: This is an occlusal deviation created by habits or muscular dysfunctions. Certain habits such as thumbsucking or reverse or deviant swallowing may cause a malocclusion depending on the intensity, duration, and/or age at which they occur.

Missing teeth: Premature loss of primary teeth, missing permanent teeth, or supernumerary teeth can also contribute to a malocclusion because they cause adjacent teeth to shift from their normal alignment.

PRIMARY TEETH OCCLUSION

The spacing of the primary teeth plays an important part of the occlusion of the permanent teeth. Proximal contact is needed for the overall integrity of the permanent teeth, but spacing between primary teeth, particularly the anterior teeth, is needed to provide adequate room for larger permanent teeth. This normal spacing between the anterior deciduous teeth is called *primate spacing*.

Although the jaws will grow, the growth may not provide enough width for the permanent teeth. Lack of primate spacing, or crowding of the anterior teeth, may suggest a future orthodontic problem.

The position of the primary second molar is also an important determinant of permanent tooth alignment. If the second molars are in a Class I position, the permanent teeth will usually be guided into a Class I position. The positioning of the primary second molars is then referred to as *Class I—mesial step* (Figure 15–7).

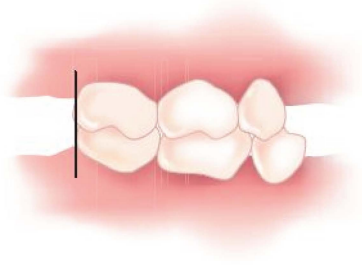

© Cengage Learning 2013

(A)

Figure 15–7. (A) Straight (Flush) Terminal Plane. The distal surfaces of the second primary molars are on the same vertical plane. A moderate number of children have this relationship.

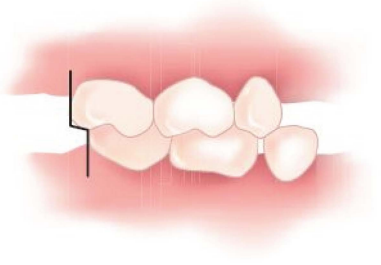

© Cengage Learning 2013

(B)

Figure 15–7. (B) Mesial Step. The distal surface of the mandibular molar is mesial to that of the maxillary molar, thereby forming a mesial step. Most children have this relationship.

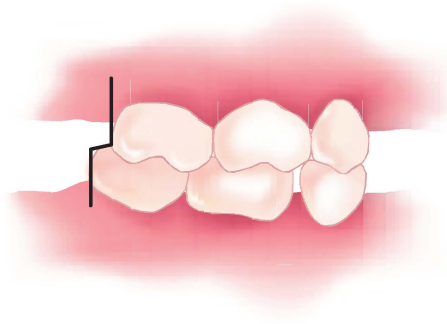

© Cengage Learning 2013

(C)

Figure 15–7. (C) Distal Step. The distal surface of the mandibular molar is distal to that of the maxillary molar, thereby forming a distal step. Few children have this relationship.

Often the primary molars will show a cusp-to-cusp (end-to-end) relationship called *terminal plane* (Figure 15–7). An actual end-to-end relationship between the second primary molars is also considered Class I. If the primary molars guide the permanent molars into position, a malocclusion may be seem likely but, in fact, often does not occur. Extra space is provided in the area of the primary molars, allowing for a mesial shift of the permanent mandibular first molars. The primary second molars are wider mesiodistally than the premolars that will replace them, and there is a primate space between the primary canine and first molar. With these two factors and more growth in the arch between ages 8 and 9, a Class I relationship can occur.

SUMMARY

Occlusion occurs when the maxillary and mandibular teeth are in contact in any functional relationship. Ideal occlusion occurs when the teeth conform to a specific pattern of contacts. To simplify the study of occlusion, Angle's classification is frequently used to describe the relationship of first molars and canines. Deviations in the position of teeth or groups of teeth provide a basic understanding of occlusion, but a thorough study of this subject would include all the factors involved in the development, stability, and function of the masticatory system.

Using the following illustrations of the maxillary incisor as a guide, draw the mandibular incisor in the appropriate position as labeled

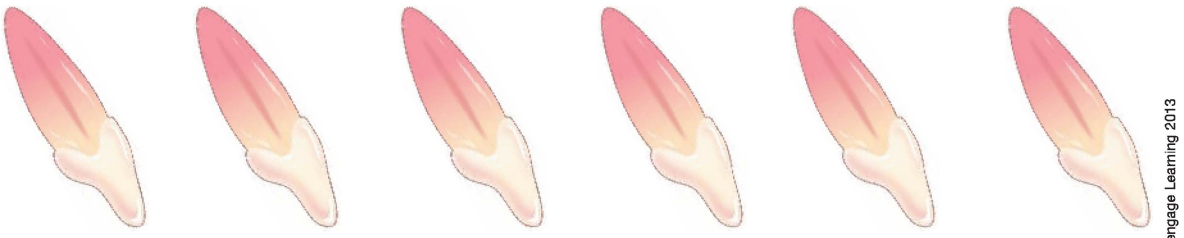

© Cengage Learning 2013

Answer the following multiple-choice questions

1. "The maxillary teeth in contact with the mandibular teeth in any functional relationship" describes:
   - **a.** Angle's classification
   - **b.** occlusion
   - **c.** edge-to edge bite
   - **d.** mesiognathic

2. When the permanent mandibular first molar and canine are more mesial (or anterior) than normal, it is referred to by Angle's classification as:
   - **a.** Class I
   - **b.** Class II
   - **c.** Class III

3. A rotated tooth is referred to as:
   - **a.** infraversion
   - **b.** linguoversion
   - **c.** torsoversion
   - **d.** crossbite

4. A horizontal overlap of the maxillary teeth creating protrusion is a(an):

a. openbite

b. overbite

c. overjet

d. crossbite

5. When the mesiobuccal cusp of the maxillary first molar rests in the mesiobuccal groove of the mandibular molar, the Angle classification is:

a. Class I

b. Class II

c. Class II

CHAPTER 16

Form and Function

General Information

Proximal Contact Areas

Interproximal Spaces

Embrasures

Compensating Curvatures

Objectives

At the completion of this chapter, you will be able to:

- Describe proximal contact areas, interproximal spaces, and embrasures, and understand their importance to the function and integrity of the masticatory system.
- Define curve of Spee and curve of Wilson.
- Complete the worksheet at the end of the chapter.

Key Terms

Compensating curvatures

Curve of Spee

Curve of Wilson

Embrasure

Interproximal space

Proximal contact area

GENERAL INFORMATION

In order for the teeth to cut and masticate food, their appropriate position in the arch must be maintained. Correct positioning is also necessary to assist in the protection of the supporting structures, which in turn sustain the teeth so that they can function properly. Form and function are concerned with how both the position and shape of the teeth enable them to function.

The entire topic of tooth form and function is considerably broad, covering all the conditions that affect tooth alignment in the arches. *Wheeler's Dental Anatomy, Physiology and Occlusion*, by M. Ash, includes nine aspects in the study of this topic:

1. The development of occlusion
2. Dental arch form
3. Compensating curvatures and planes of the dental arches
4. Angulation of the individual teeth in relation to various planes
5. Functional form of the teeth at their incisal and occlusal thirds
6. Facial relations of each tooth in one arch to its antagonist(s) in the opposing arch in centric occlusion
7. Occlusal contact and intercusp relations of all teeth of one arch with those in the opposing arch in centric occlusion
8. Occlusal contact and intercusp relations of all teeth during various functional mandibular movements
9. Neurobehavioral aspects of occlusion

An entire study of occlusion would be necessary to thoroughly cover these topics. Only a basic introduction to form and function is given in this chapter, covering those aspects that are most useful to the dental assistant. This includes the topics of proximal contact areas, interproximal space, and embrasures. Further study is recommended when considering oromotor functions, prosthetic rehabilitation, or orthodontics.

PROXIMAL CONTACT AREAS

The **proximal contact area** is a small spot on the mesial and distal surface of each tooth that touches, or contacts, the proximal tooth. Every tooth, except the last molars in each arch, has both a distal and mesial contact area.

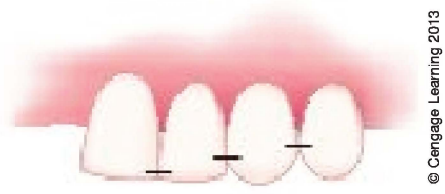
© Cengage Learning 2013

Figure 16–1. Contact areas.

Contact areas are shown in **Figure 16–1** by horizontal lines. This area is generally the widest point on the crown of the tooth.

Contact areas of the anterior teeth are located more incisally that those of the posterior teeth. A review of the individual teeth shows the contact areas of the posterior teeth located at about the middle of the tooth.

Function of Contact Areas

Proper contact between teeth prevents food from packing between them, thus protecting the gingiva from any irritation that could result from food that is lodged between the teeth. In addition, contact areas stabilize the teeth in the arch by providing mutual support.



INTERPROXIMAL SPACES

The **interproximal space** is an area between each tooth normally filled with the interdental papilla. Its boundaries form a triangle with the sides of the proximal surfaces of the teeth; the base in the alveolar crest and the apex is the contact area (**Figure 16–2**).

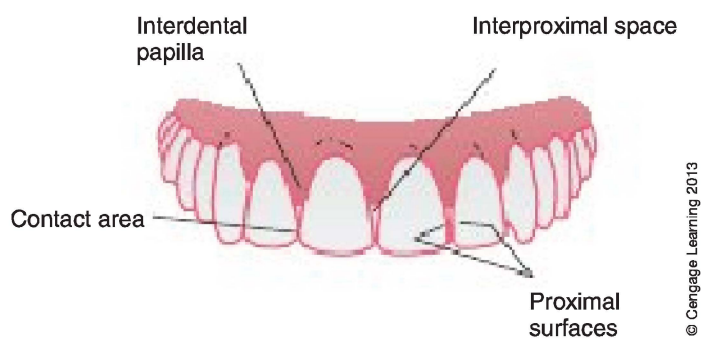

© Cengage Learning 2013

Figure 16–2. Proximal surfaces and contact areas.

Function of the Interproximal Space

Appropriate width between each tooth (the base of the triangle) is important to provide enough space for periodontal structures; to allow ample bone between each tooth for adequate support; and to maintain the level of the gingival tissue (Figure 16–3).

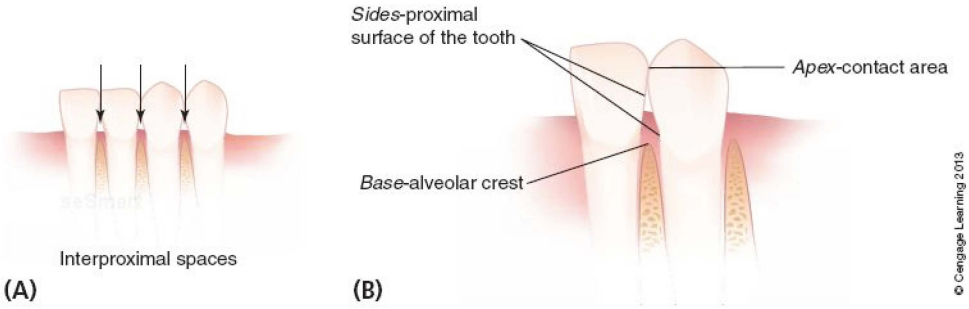

Figure 16–3. (A) Interproximal spaces. (B) The boundaries of the interproximal space form a triangle.

EMBRASURES

Any curvature, either toward or away from the contact area, is an **embrasure** (Figure 16–4). Embrasures are located on the incisal, occlusal, lingual, or facial surface and are often referred to as *spillways* because they assist the food in "spilling" away from the tooth.

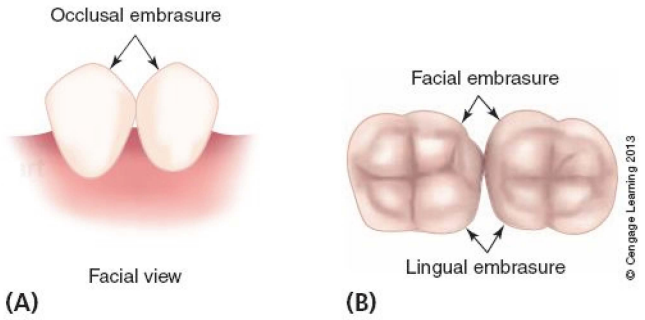

Figure 16–4. (A) Facial view of an occlusal embrasure. (B) Lingual and facial embrasures.

Function of the Embrasures

The embrasures or spillways act as an escapement for food so that it does not cling to the teeth or get forced into the interproximal spaces. In this way, embrasures act to assist in cleansing the tooth and to protect the gingival tissue from being irritated by keeping the food away from it.

COMPENSATING CURVATURES

The occlusal plane of the tooth is a line that extends from the incisal edge of the central incisors to the distal buccal cusp of the second molar. Von Spee first noted that this line, when viewed from a point opposite the first molars, forms a curve when the teeth have erupted and are in normal alignment. This curve, which is concave toward the mandible, is the **curve of Spee**, named after Von Spee, who first defined it (**Figure 16–5A**).

When the arches are viewed from a frontal position, another curvature is seen extending from the cusp tip of the right molar to the cusp tip of the left molar. This concave curvature is the **curve of Wilson** (see **Figure 16–5B**).

Together, these and other **compensating curvatures** of the arches account for strength and efficiency in mastication and assist in the stability of the teeth. Compensating curvatures have no special use other than to help define occlusion. Their main use is in the construction of dentures or in the balancing of the arches for orthodontia.

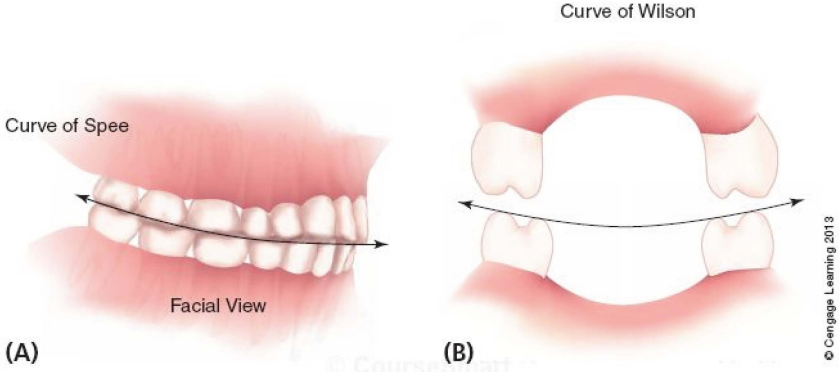

Figure 16–5. (A) Curve of Spee—frontal view. (B) Curve of Wilson—frontal view.



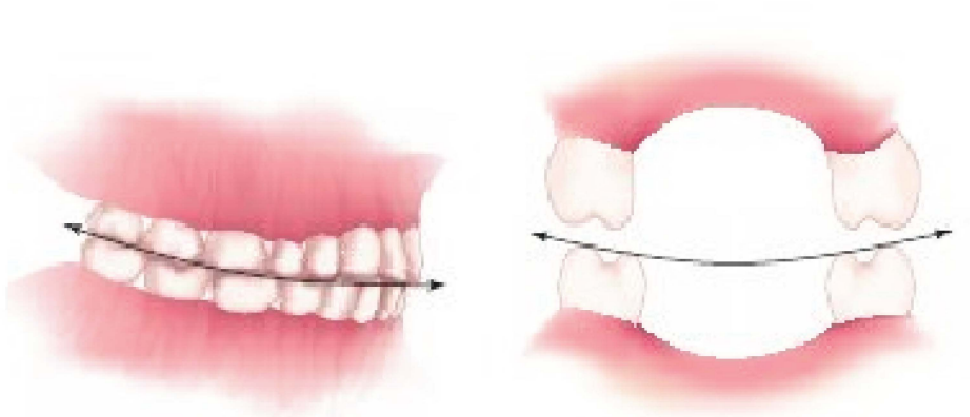

SUMMARY

Although many factors affect the form and function of the teeth, only three of these are examined here in order to provide a basic understanding of the importance of the appropriate positioning of each tooth in the arch. Those examined are proper proximal contact areas, which prevent food from packing between the teeth; embrasures, which act as a spillway so that food does not cling to the teeth; and interproximal spacing, which allows adequate space for the periodontal structures to support the teeth.

Complete the following questions about contact areas

1. Tooth surfaces that are adjacent to or facing each other are called proximal surfaces. The proximal surfaces are the _____ and _____ surfaces of each tooth.
2. The contact area is that area of the proximal surface that touches the adjacent area. Each tooth contacts its adjacent tooth on the proximal surface.
3. Each tooth has two contact areas except the last molar, which has no contacting tooth on the distal.
   Mesial surfaces contact distal surfaces with the exception of the central incisors, where two mesial surfaces meet.
   Place a line on the following figure to represent the location of the contact areas.

Answer the following multiple-choice questions

1. Which of the following is not a boundary of the interproximal space?
   a. the side of the tooth
   b. the lingual ridge
   c. the contact area
   d. the alveolar crest
2. Which of the following helps stabilize the teeth in the arch?
   a. the contact area
   b. an embrasure
   c. a curve of Spee
   d. a gingival crest
3. Which of the following helps to keep food away from the tooth?
   a. an embrasure
   b. an interproximal space
   c. a compensating plane
   d. a curve of Spee

4. Which of the following is necessary to enable the teeth to function?

a. shape of the tooth

b. position in the arch

c. angulation of the tooth

d. all of the above

5. Compensation curves of the arch account for:

a. strength during mastication

b. efficiency of mastication

c. stability of the teeth

d. all of the above

SECTION V

Head and Neck Anatomy

Chapter 17 Osteology of the Skull

Chapter 18 Muscles of the Head and Neck

Chapter 19 Nerves of the Head and Neck

Chapter 20 Arteries of the Head and Neck

Chapter 21 Salivary Glands

Chapter 22 Temporomandibular Joint

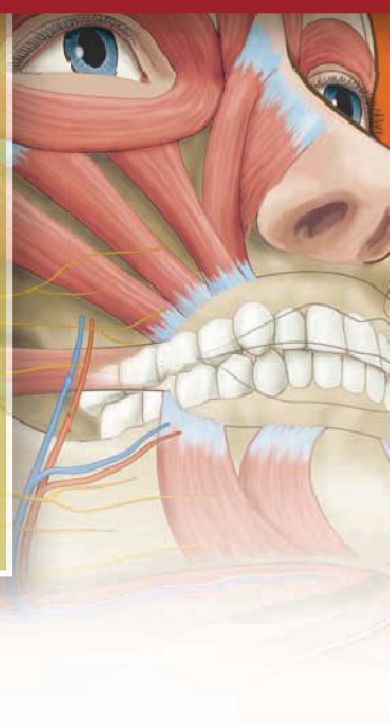

CHAPTER 17

Osteology of the Skull

Neurocranium

Viscerocranium

Maxilla

Mandible

Hyoid bone

Objectives

At the completion of this chapter, you will be able to:

- Name the bones of the neurocranium.
- Name the bones of the viscerocranium.
- Identify the location of the cranial and facial bones on a picture or diagram.
- Identify the location of the anatomic landmarks on the cranial and facial bones on a picture or diagram.
- Identify the following foramina or canals on a picture or diagram: hypoglossal canal, supraorbital, stylomastoid, carotid canal, jugular, rotundum, ovale, foramen magnum, spinosum, lacerum, greater and lesser palatine, and incisive.
- Identify the location of the anatomic landmarks on the mandible and maxilla on a picture or diagram.
- Complete the worksheet at the end of the chapter.

Key Terms

Alveolar process
Articular eminence
Canal
Canine eminence
Carotid canal
Condyle
Coronoid notch
Coronoid process
Cribriform plate
Ethmoid bone
External auditory meatus
External oblique line
Foramen
Foramen lacerum
Foramen magnum
Foramen ovale
Foramen rotundum
Foramen spinosum
Genial tubercles
Greater palatine foramen
Incisive (nasopalatine) foramen
Inferior nasal concha
Inferior orbital fissure
Infraorbital foramen
Internal oblique line
Jugular foramen
Lacrimal bones
Lateral plate
Lesser palatine foramen
Lingula
Mandibular foramen
Mandibular fossa
Mandibular notch
Mastoid process
Maxilla
Maxillary sinus
Maxillary tuberosity
Medial plate
Median palatine suture
Mental foramen
Mental protuberance
Mylohyoid groove
Nasal bones
Neurocranium
Occipital bone
Optic foramen
Palatine bones
Parietal bones
Pterygoid fossa
Pterygoid fovea
Pterygoid hamulus
Pterygoid process
Ramus
Retromolar fossa
Sella turcica
Sphenoid bone
Stylomastoid foramen

continues

Key Terms *continued*

Submandibular fossa
Superciliary ridge
Superior orbital fissure
Supraorbital foramen
Suture
Temporal bones
Transverse palatine suture
Viscerocranium
Vomer
Zygomatic process

NEUROCRANIUM

There are 22 bones that comprise the skull. The **neurocranium** is the portion of the cranium that houses and protects the brain. It is comprised of the following 8 bones (**Figure 17–1** through **Figure 17–5**).

This chapter introduces several new terms. A **suture** is a jagged line where bones join. A **foramen** is a short opening through bone, and a **canal** is a long opening through bone. Nerves and blood vessels travel through canals and foramina.

Occipital Bone

The **occipital bone** forms the posterior aspect of the skull. It articulates or joins with the atlas, or first cervical vertebra, by way of the occipital condyles. These condyles are located on either side of the **foramen magnum**, the large opening through which the spinal cord passes (see **Figure 17–4**).

From an internal view, the occipital bone is divided into four fossae, which house lobes of the brain. The ***hypoglossal canals*** are located on either side of the foramen magnum. The hypoglossal nerve, an important nerve in dentistry, passes through the hypoglossal canal (see **Figure 17–5**).

Frontal Bone

This bone forms the forehead and anterior aspect of the skull (see **Figure 17–1** through **Figure 17–3**). There are four sutures that outline or delineate this bone.

1. *Coronal suture*—joins the frontal and parietal bones
2. *Sagittal suture*—connects the parietal bones
3. *Lambdoidal suture*—joins the occipital and parietal bones
4. *Squamous suture*—connects the parietal and temporal bones

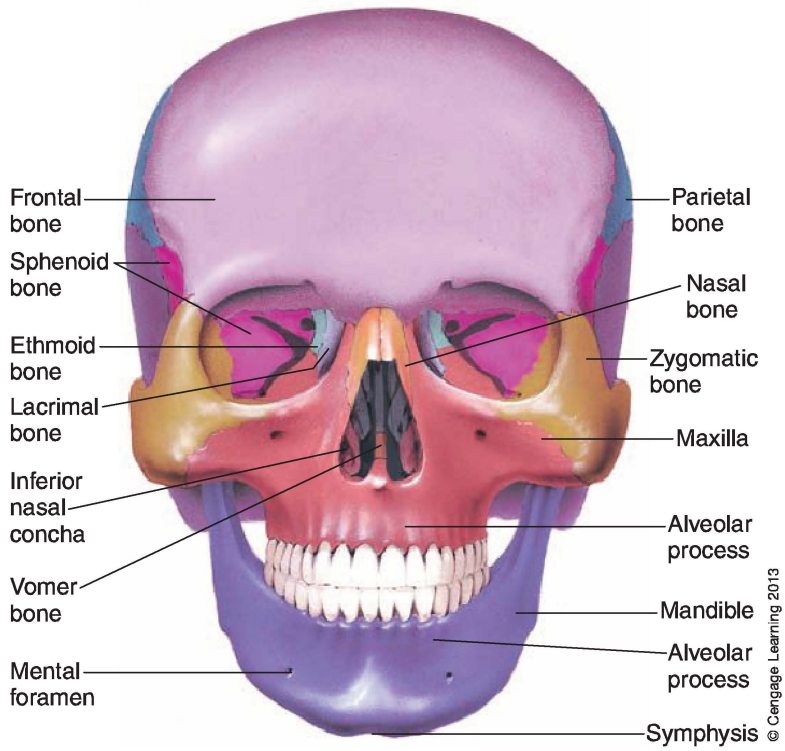

Figure 17–1. Skull—anterior aspect.

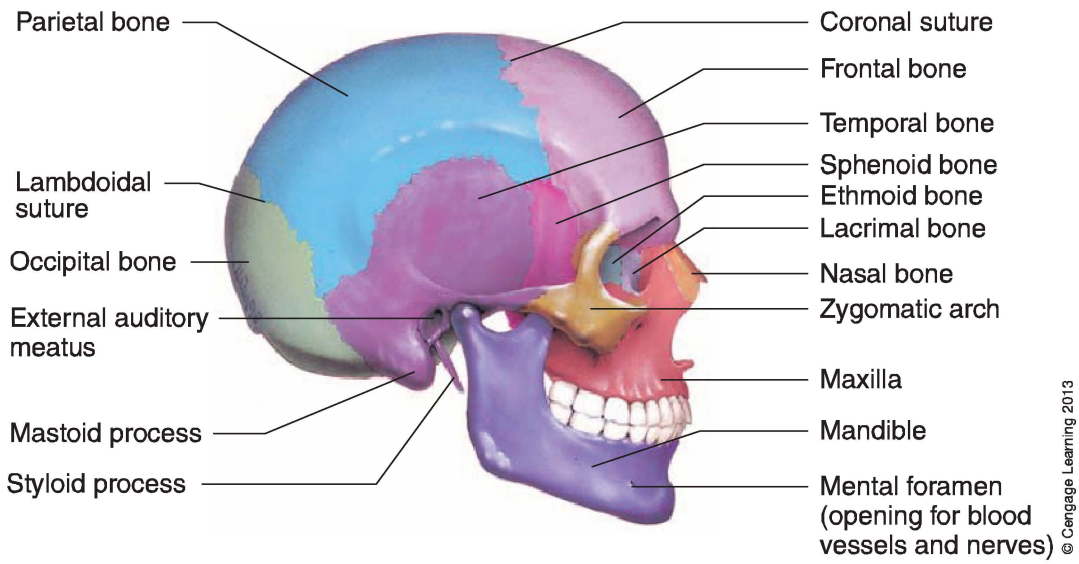

Figure 17–2. Skull—lateral aspect.

The prominent area of the forehead is known as the *frontal eminence*. The *glabella* is the flattened area between the eyebrows. A **superciliary ridge** is located above each eyebrow. On the superior margin of the orbit (eye) is the **supraorbital foramen** through which passes the supraorbital nerve and artery.

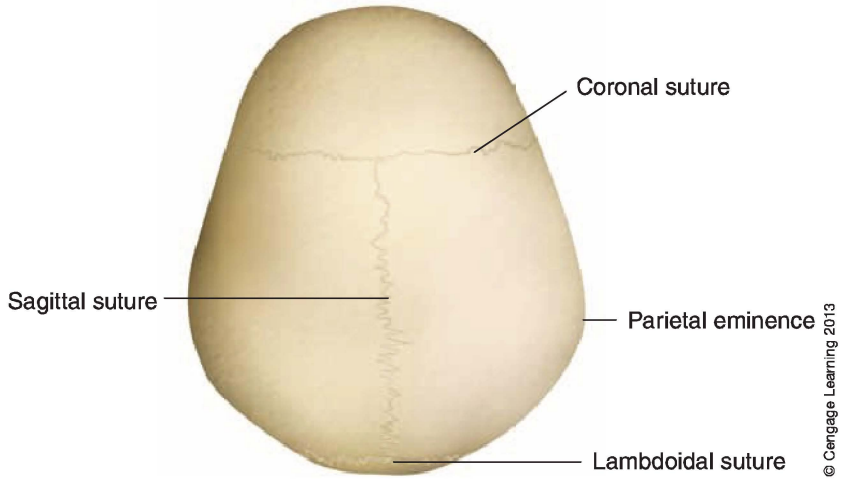

Figure 17–3. Sutures of the skull.

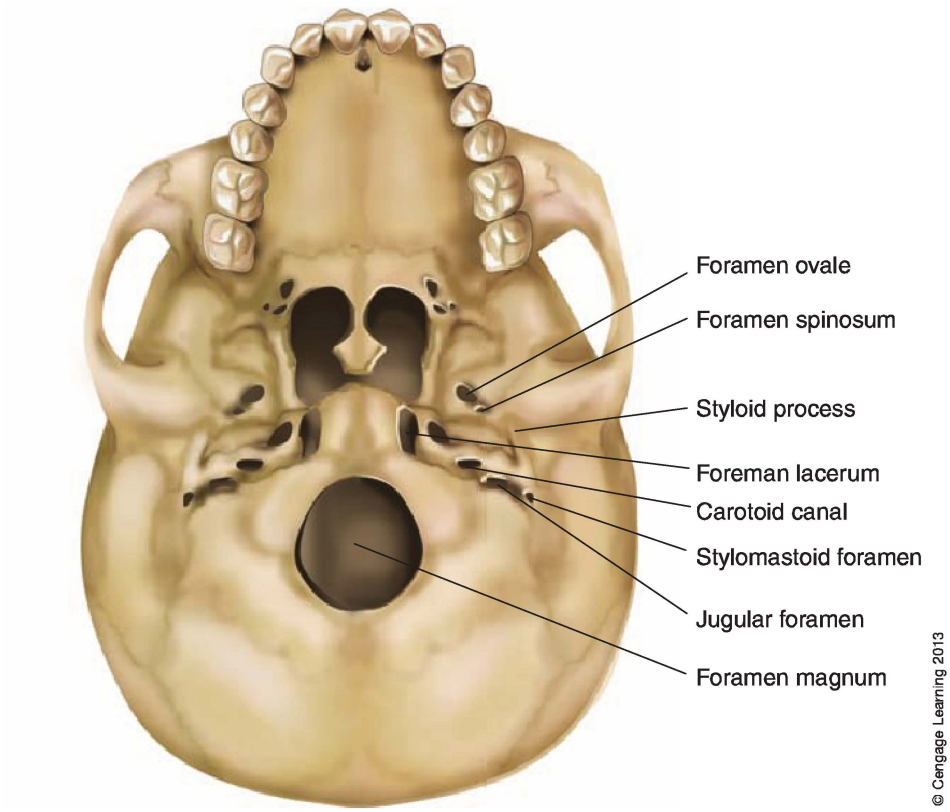

Figure 17–4. Skull—inferior aspect.

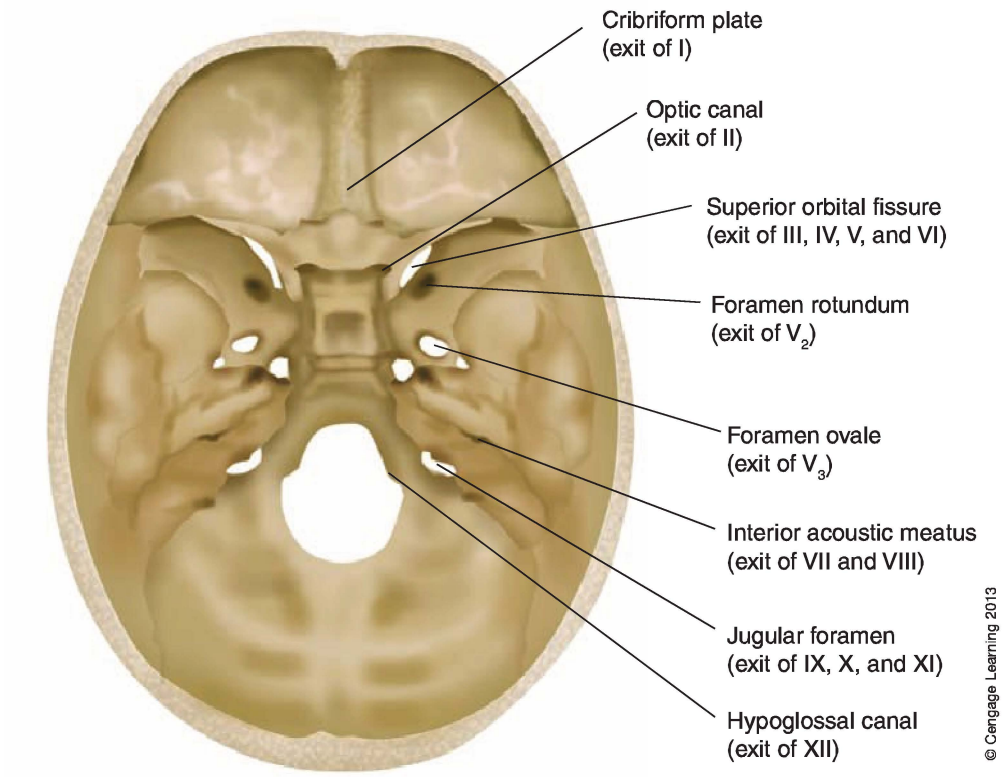

Figure 17–5. Skull—internal aspect, showing exit sites of the cranial nerves.

Bones of the Orbit

Six bones comprise each orbit: sphenoid, ethmoid, lacrimal, frontal, zygomatic, and maxilla (**Figure 17–1** and **Figure 17–6**). The **optic foramen** is the opening for the optic nerve and ophthalmic artery. Through the **superior orbital fissure**, the oculomotor (III), trochlear (IV), ophthalmic branch of the trigeminal (V_1), and the abducent (VI) nerves enter the orbit. The **inferior orbital fissure** is the entrance to the orbit for the infraorbital nerve. See Table 17–1.

TABLE 17–1. Bones of the Cranium

SINGLE BONES	PAIRED (RIGHT AND LEFT) BONES
Occipital	Parietal
Sphenoid	Temporal
Ethmoid	
Frontal	

© Cengage Learning 2013

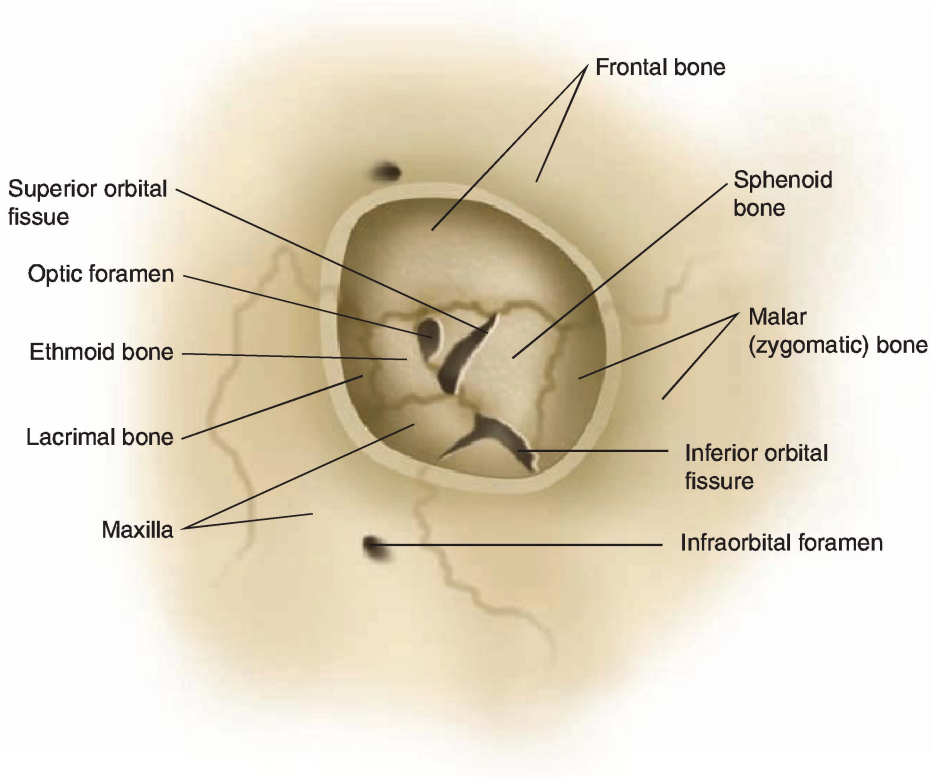

Figure 17–6. Bones of the left orbit.

Parietal Bones

The **parietal bones** have two curving lines, the superior and inferior temporal lines (see **Figure 17–1**, **Figure 17–2**, and **Figure 17–3**). These lines serve as the attachment for the temporalis muscle, a muscle of mastication.

Temporal Bones

The **temporal bones** consist of three parts: the squamous, which is the flattened, fan-shaped portion; the petrous; and the tympanic, which encloses the essential hearing organs (see **Figure 17–2**). The temporal bones have several portions:

- The **zygomatic process**, which extends out to form the zygomatic arch
- The **mandibular (glenoid) fossa**, into which the mandible articulates
- The **articular eminence** or **tubercle**, a "V"-shaped projection located in front of the glenoid fossa (**Figure 17–7**)

The **external auditory (acoustic) meatus**, located in the tympanic portion, is the opening for the outer ear. Posterior to this meatus is a rounded prominence known as the **mastoid process** (see **Figure 17–2**). This

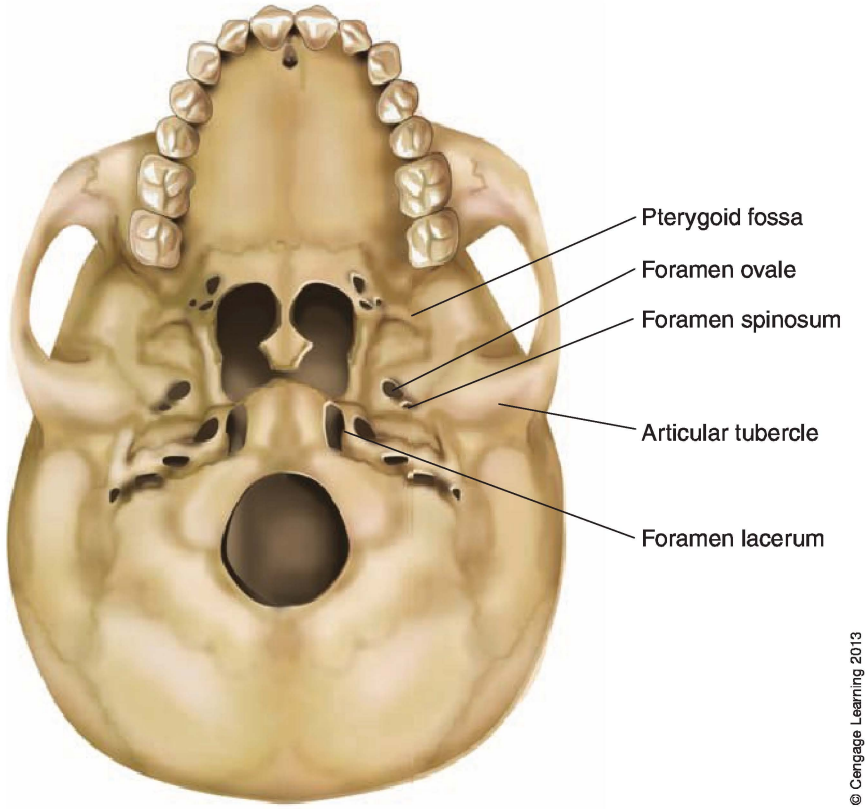

Figure 17–7. Skull—inferior aspect, showing foramina.

structure is hollowed out by air cells that communicate with the middle ear. A pointed spicule of bone, the ***styloid process***, serves as a muscle and ligament attachment. A small foramen, the **stylomastoid foramen**, is located between the styloid and mastoid processes. This is the opening through which the facial nerve (VII) exits the skull (see **Figure 17–4**).

Just lateral to the occipital condyles and between the petrous portions of the temporal bone is the **jugular foramen**, a large opening through which the internal jugular vein, glossopharyngeal (IX), vagus (X), and (spinal) accessory (XI) nerves exit the skull. The **carotid canal** opening for the internal carotid artery is located in front of the jugular foramen (see **Figure 17–4**).

Ethmoid Bone

The **ethmoid bone** forms a part of the nasal cavity, nasal septum, and orbit. It is located anteriorly at the base of the cranium and is comprised of a perpendicular or **cribriform plate**. The cribriform plate is perforated to allow olfactory nerves (relating to the sense of smell) to pass between the brain and nose. The ethmoid bone can be considered a part of either the neurocranium or viscerocranium. For our purposes, we will consider it a portion of the neurocranium.

Sphenoid Bone

The **sphenoid bone** looks like a bat with a body, two greater wings and two lesser wings (**Figure 17–8**). It articulates with *all* the bones that form the cranium. From each greater wing (resembling a butterfly wing), a **pterygoid process** descends. Each pterygoid process (see **Figure 17–8**) is comprised of the following:

- A flattened, **lateral plate** (outside)
- A thinner, **medial plate** (inside)
- A **pterygoid (scaphoid) fossa**—depression between the medial and lateral plates
- A **pterygoid hamulus**—a pointed process that curves outward from the lower (free) end of the medial plate

A depression seen on the surface of the sphenoid bone houses the pituitary gland. This depression is known as the **sella turcica** (**Figure 17–9**).

Three foramina can be seen on the sphenoid bone from the internal aspect. The **foramen rotundum** transmits the maxillary division of the trigeminal nerve (V_2). Through the **foramen ovale**, the mandibular division of the trigeminal nerve (V_3) passes (see **Figure 17–7**). The **foramen spinosum** (see **Figure 17–6**) transmits the middle meningeal artery to the brain. Next to the foramen ovale is the **foramen lacerum** (see **Figure 17–7**), a channel through which the internal carotid artery travels. In a living human being, the foramen lacerum is covered by a layer of cartilage (see **Figure 17–7**).

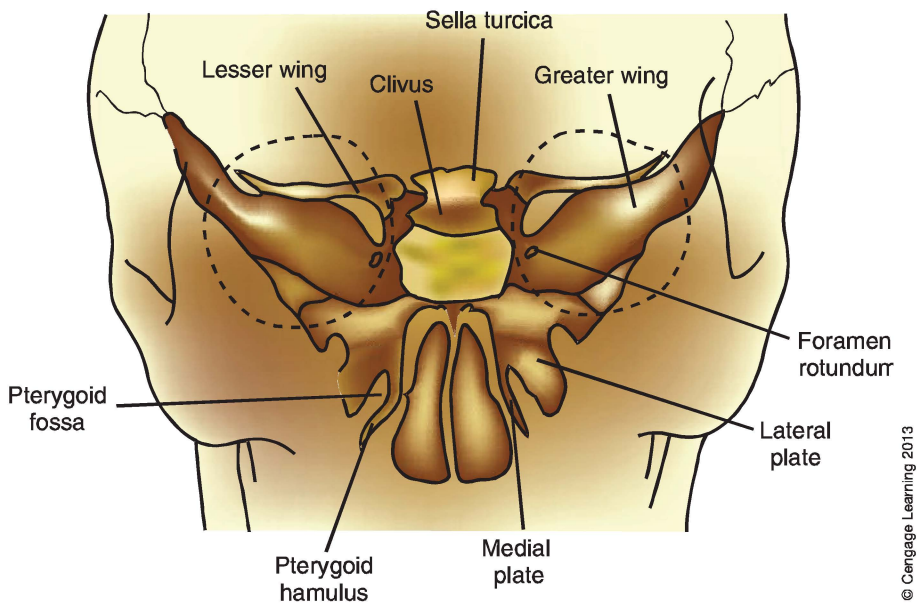

Figure 17–8. Sphenoid bone.

VISCEROCRANIUM

There are fourteen bones that comprise the **viscerocranium** of the facial skeleton, which gives us our appearance.

Single Bones	Paired (Right and Left) Bones
Mandible	Zygomatic
Vomer	Maxillae
	Nasal
	Lacrimal
	Palatine
	Inferior nasal concha

Zygomatic Bones (Cheek Bones)

The *zygomatic* (singular: *zygoma*) *bones* form the cheeks.

Vomer

The **vomer** forms the posterior and inferior part of the nasal septum (see **Figure 17–9**). (The ethmoid bone forms the anterior portion of the nasal septum).

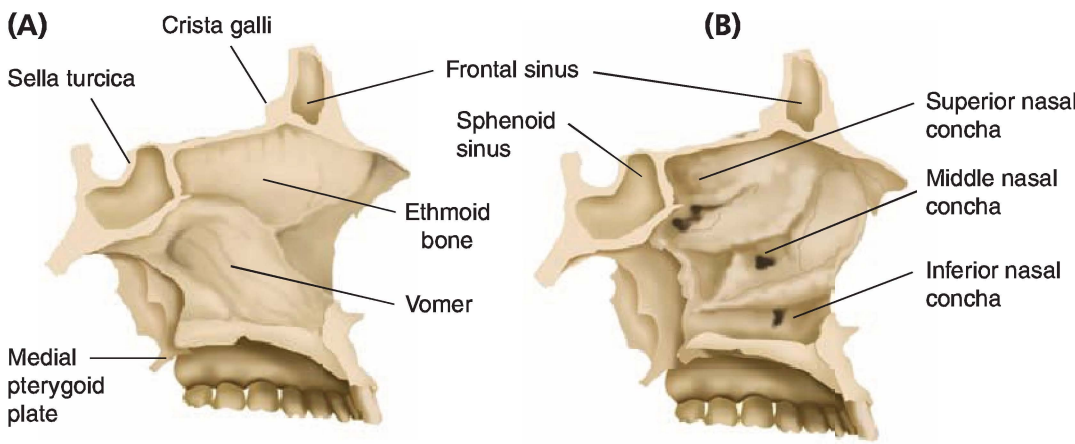

© Cengage Learning 2013

Figure 17–9. Bony nasal septum and cavity: (A) sagittal section showing the bony nasal septum, (B) nasal cavity with nasal septum removed.

Nasal Bones

The **nasal** bones are oblong bones that form the bridge of the nose (see **Figure 17–1** and **Figure 17–2**).

Lacrimal Bones

The **lacrimal bones** are small and fragile (see **Figure 17–6**). They are located at the anterior portion of the medial orbital wall.

Inferior Nasal Concha

The **inferior nasal concha** lies in the nasal cavity and articulates with the maxilla. The superior and middle nasal conchae are processes of the ethmoid bone; however, the inferior nasal concha is formed as a separate bone (see **Figure 17–9**).

Palatine Bones

Each **palatine bone** is comprised of a horizontal plate, which forms the hard palate, and a vertical plate. Two foramina are located in the hard palate. The **greater palatine foramen** is a large opening for the greater palatine nerve and artery. The **lesser palatine foramen** is a small foramen located posterior to the greater palatine foramen. It transmits the lesser palatine nerve and artery (**Figure 17–10**).

MAXILLA

The **maxilla** is comprised of two portions joined by a median suture. It consists of a body and four processes. The frontal process and zygomatic (malar) process join the frontal and zygomatic bones. The **alveolar process** surrounds and supports the maxillary teeth, and the palatine process forms the major portion of the hard palate.

The body of the maxilla contains the **canine eminence**, an elevation of bone over the canine root. The infraorbital nerve exits onto the face through the **infraorbital foramen** just below the inferior margin of the

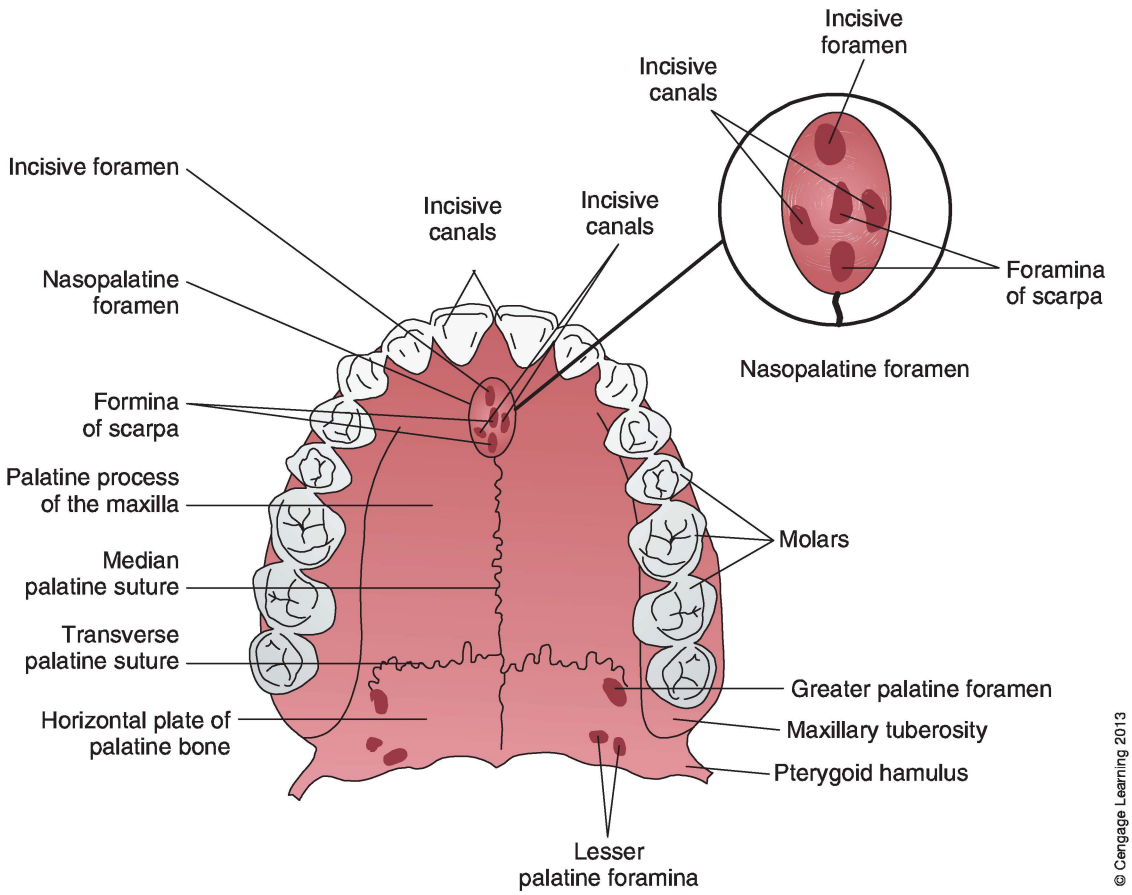

Figure 17–10. Maxilla and palatine bones.

orbit (see **Figure 17–1**). The **maxillary sinus** is the largest of the paranasal sinuses and is located within the maxilla above the roots of the maxillary posterior teeth. Posterior to the maxillary third molars is a bulging of bone known as the **maxillary tuberosity** (**Figure 17–10**).

From an interior view, the **incisive (nasopalatine) foramen** can be seen. It is located on the midline, just behind the maxillary central incisors. It is the opening for the nasopalatine nerve to innervate the hard palate in the maxillary anterior region. It is covered by the incisive papillae (see **Figure 17–10**). The **median palatine suture** marks the articulation of the right and left palatine process. The **transverse palatine suture** is the articulation between the palatine process and the horizontal plates of the palatine bones (see **Figure 17–10**).

MANDIBLE

The mandible is a horseshoe-shaped bone that is comprised of a horizontal body with right and left vertical rami (singular: **ramus**). There is one body and two rami. Each ramus has the following:

- A **condyle**—a rounded knob that joins with the mandibular (glenoid) fossa
- A **coronoid process**—a pointed, flat projection onto which the temporalis muscle inserts
- A **mandibular notch**—the curved notch between the condyle and coronoid process (**Figure 17–11** and **Figure 17–12**)

The condyle is attached to the ramus by a thin neck. A triangular depression below the condyle is known as the **pterygoid fovea** to which the lateral pterygoid muscle attaches (see **Figure 17–11**). The **mental protuberance** is the tip of the chin. The **mental foramen** is located on the external surface of the mandible near the apex of the mandibular second premolar. It is the exit point where the mental nerve and vessels branch from the inferior alveolar nerve. A line that extends from the mental foramen along the external surface of the body is known as the **external oblique line** (see **Figure 17–11**). The **coronoid notch** is a concave curve near the posterior teeth. This coronoid notch is a landmark for the inferior alveolar nerve block.

On the internal surface of the mandible, the **internal oblique line** can be seen. It runs from the molar region to the midline. It is also known as

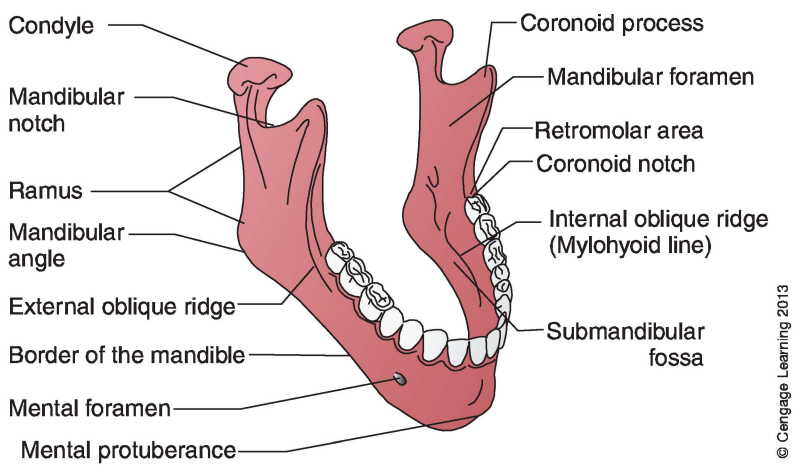

Figure 17–11. Mandible—external view.

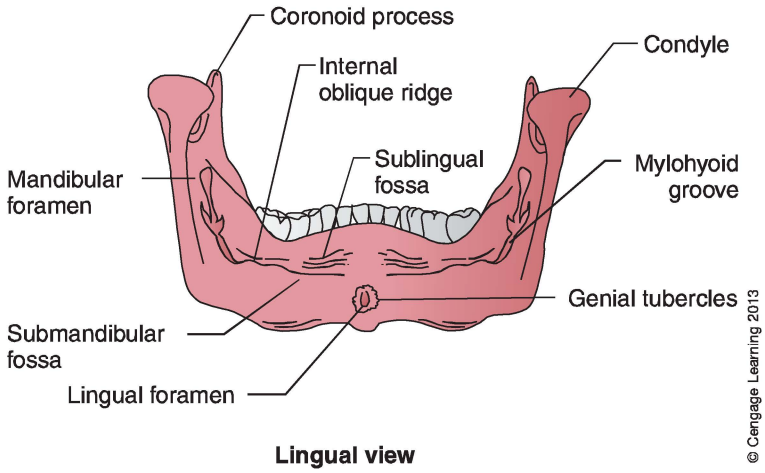

Figure 17–12. Mandible—internal view.

the *mylohyoid ridge or line* and is the attachment for the mylohyoid muscle. **Genial tubercles** or **spines**, small projections of bone located on either side of the midline (see **Figure 17–12**), are the site of attachment for the genioglossus and geniohyoid muscles.

The **submandibular fossa** contains the submandibular gland and is located in the premolar and molar region below the mylohyoid line. The sublingual fossa is located on either side of the genial tubercles. The sublingual glands are housed here (see **Figure 17–12**).

The **retromolar fossa** is a triangular area of bone distal to the mandibular third molar (see **Figure 17–11**). The **mandibular foramen** is a large opening located in the center of the ramus. It is the opening into the mandibular canal through which passes the inferior alveolar nerve and artery (see **Figure 17–10** , **Figure 17–11** , and **Figure 17–12**). Superior to the mandibular foramen is the **lingula**, a small bony projection that protects the foramen. The **mylohyoid groove** is visible leading away from the mandibular foramen (see **Figure 17–12**).

HYOID BONE

The hyoid bone is suspended in the neck below the mandible and is an attachment point for neck and tongue muscles. It is comprised of a body and two pairs of horns, the greater cornu and lesser cornu (**Figure 17–13**). It is horseshoe-shaped and does not articulate with other bones.

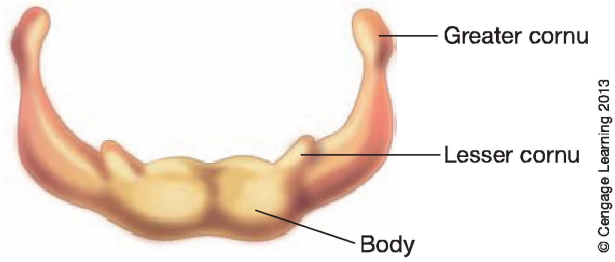

Figure 17–13. Hyoid bone—anterior view.

SUMMARY

The skull contains 22 bones and is divided into two groups: (1) the neurocranium containing 8 bones that protect the brain and (2) the viscerocranium containing 14 bones that comprise the face.

Included in the neurocranium are (1) the occipital bone, which forms the posterior aspect of the skull; (2) the frontal bone, which forms the forehead and anterior aspect of the skull; (3) the ethmoid bone, which forms the nasal cavity, nasal septum, and orbit; (4) the sphenoid, ethmoid, lacrimal, frontal, zygomatic, and maxilla, which comprise the bones of the orbit; (5) the parietal bones, which form the sides of the skull; and (6) the temporal bones, which house the hearing organs and help to comprise the temporomandibular joint.

Included in the viscerocranium are (1) the zygomatic bones, which form the cheek; (2) the nasal bones, which form the bridge of the nose; (3) the lacrimal bones; (4) the inferior nasal concha, which lies in the nasal cavity and articulates with the maxilla; (5) the palatine bones, which form the hard palate; (6) the maxilla, which forms the upper jaw; (7) the mandible, which forms the lower jaw; and (8) the vomer, which forms the posterior and inferior part of the nasal septum.

In addition, the hyoid bone, which does not articulate with other bones, is located under the mandible. It serves as an attachment for the tongue and neck muscles.

Define the following terms

foramen
canal
suture

Using a picture (diagram) of a human skull, answer the following questions

1. Locate the following bones:
   occipital
   frontal
   parietal
   temporal
   sphenoid
   ethmoid
   zygomatic
   nasal
   lacrimal
   inferior nasal concha
   palatine

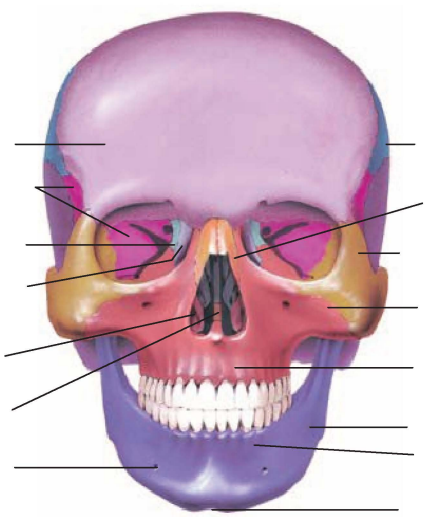

© Cengage Learning 2013

2. Locate the following structures on a diagram (picture) of the sphenoid bone:
   lateral plate
   medial plate
   pterygoid fossa
   pterygoid hamulus

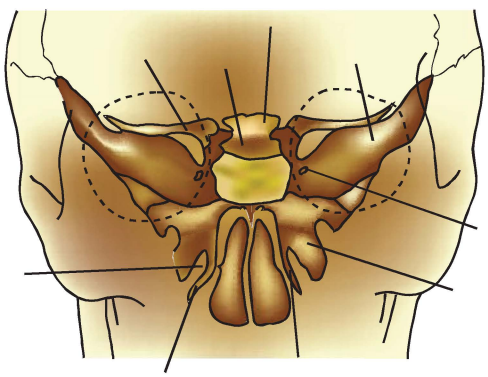

© Cengage Learning 2013

3. Locate the following structures on a diagram (picture) of the maxilla:
   canine eminence
   infraorbital foramen
   maxillary tuberosity
   incisive foramen
   median palatine suture
   transverse palatine suture
   greater palatine foramen
   lesser palatine foramen

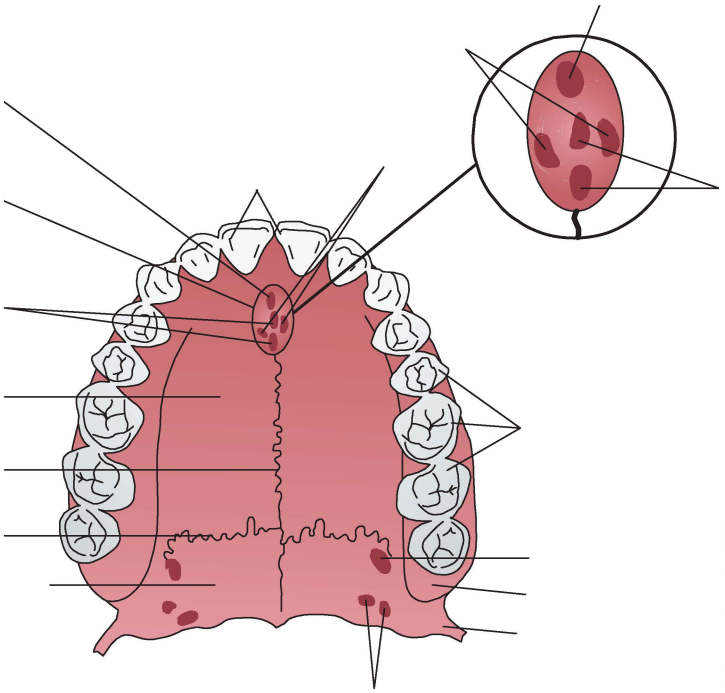

4. Locate the following structures on a diagram (picture) of the mandible:

alveolar process
mandible angle
ramus
condyle
coronoid process
coronoid notch
pterygoid fovea
mental protuberance
mental foramen
external oblique line
internal oblique line
mandibular notch
genial tubercles
submandibular fossa
sublingual fossa
retromolar fossa
mandibular foramen
mylohyoid groove
lingula

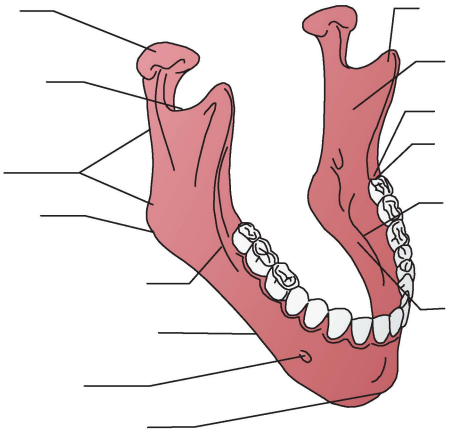

© Cengage Learning 2013

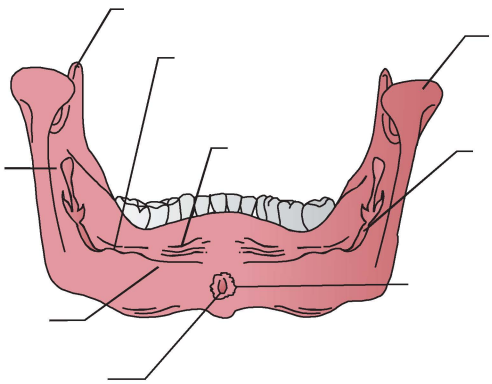

© Cengage Learning 2013

Answer the following multiple-choice questions

1. Which of the following is NOT a bone of the neurocranium?

a. frontal
b. ethmoid
c. parietal
d. sphenoid
e. they are all bones of the neurocranium.

2. Which of the following is NOT a bone of the facial skeleton?

a. sphenoid
b. maxilla
c. vomer
d. nasal
e. they are all part of the facial skeleton.

3. The hamulus is located on the _____?

a. styloid process
b. medial pterygoid plate
c. zygomatic process of the mandible
d. posterior palatine process
e. ethmoid bone

4. The mandibular foramen is located on the _____?

a. medial aspect of the ramus
b. medial angle of mandible
c. floor of mandible
d. external surface of the mandible
e. inside the retromolar fossa

5. Another name for the chin is the mental spine. The mental foramen is located posteriorly to the chin bilaterally.

a. Both statements are true.
b. The first statement is true; the second is false.
c. The first statement is false; the second is true.
d. Both statements are false.

CHAPTER 18

Muscles of the Head and Neck

- General Information
- Muscles of Mastication
- Suprahyoid Muscles
- Infrahyoid Muscles
- Muscles of the Tongue
- Muscles of Facial Expression
- Muscles of the Neck
- Muscles of the Soft Palate
- Muscles of the Pharynx

Objectives

At the completion of this chapter, you will be able to:

- Describe the origin, insertion, and function of the muscles of mastication.
- Name the muscles of mastication, muscles of the tongue, muscles of facial expression, muscles of the neck, and muscles of the soft palate and pharynx.
- Classify each muscle of the head and neck according to the group in which it belongs.

- Describe the location and function of the muscles of facial expression, suprahyoid and infrahyoid muscles, and muscles of the tongue, neck, soft palate, and pharynx.
- Describe nerve innervation to the various muscle groups.
- Describe the three stages of swallowing.
- Complete the worksheet at the end of the chapter.

Key Terms

Deglutition
Extrinsic tongue muscles
Infrahyoid muscles
Insertion
Instrinsic tongue muscles
Lateral pterygoid
Masseter
Mastication
Medial pterygoid
Muscles of facial expression
Muscles of mastication
Muscles of the ears
Muscles of the mouth
Muscles of the neck
Muscles of the nose
Muscles of the pharynx
Muscles of the scalp
Muscles of the soft palate
Muscles of the tongue
Origin
Suprahyoid muscles
Temporalis

GENERAL INFORMATION

Muscles make movements possible by their contraction. Generally, they are suspended between an **origin**, a fixed structure or end, and an **insertion,** the movable end. Names of the muscles may give information about their origin and insertion. Muscles move in the direction of their origin, a fact that helps explain their motion. The muscles of the head and neck are divided into eight groups:

- Muscles of mastication
- Suprahyoid muscles
- Infrahyoid muscles

- Muscles of the tongue
- Muscles of facial expression
- Muscles of the neck
- Muscles of the soft palate
- Muscles of the pharynx

MUSCLES OF MASTICATION

The **muscles of mastication** elevate, protrude, retrude, or cause lateral movement of the mandible. They work during chewing, or **mastication**—hence their name. They are innervated by the mandibular branch of the trigeminal nerve (V_3). The maxillary artery provides blood supply.

Temporalis

The **temporalis** muscle elevates the jaw (**Figure 18–1**). This fan-shaped muscle starts from the temporal fossa of the temporal bone. The fibers

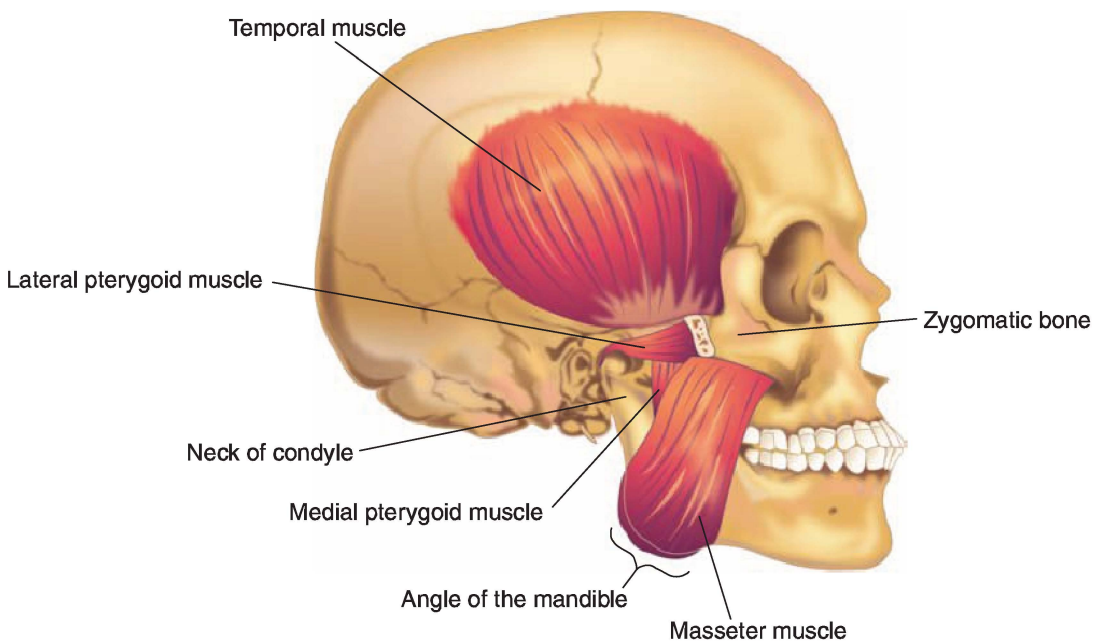

Figure 18–1. Muscles of mastication: masseter and temporalis.

form an anterior and a posterior portion. The anterior fibers are vertical; the posterior fibers are somewhat horizontal. The muscle inserts onto the coronoid process of the mandible and may also insert in the mandible distal to the mandibular third molar. Elevation of the mandible is accomplished when the entire muscle contracts. The mandible is retruded if any of the posterior fibers contract. It can be palpated above the zygomatic arch.

Masseter

The **masseter** is a powerful muscle that has both a superficial and a deep origin (**Figure 18–1** and **Figure 18–2**). The superficial fibers begin on the anterior two-thirds of the inferior border of the zygomatic arch. The deep fibers start from the posterior one-third of the zygomatic arch. The insertion of the deeper fibers is at the outside surface of the mandible and coronoid

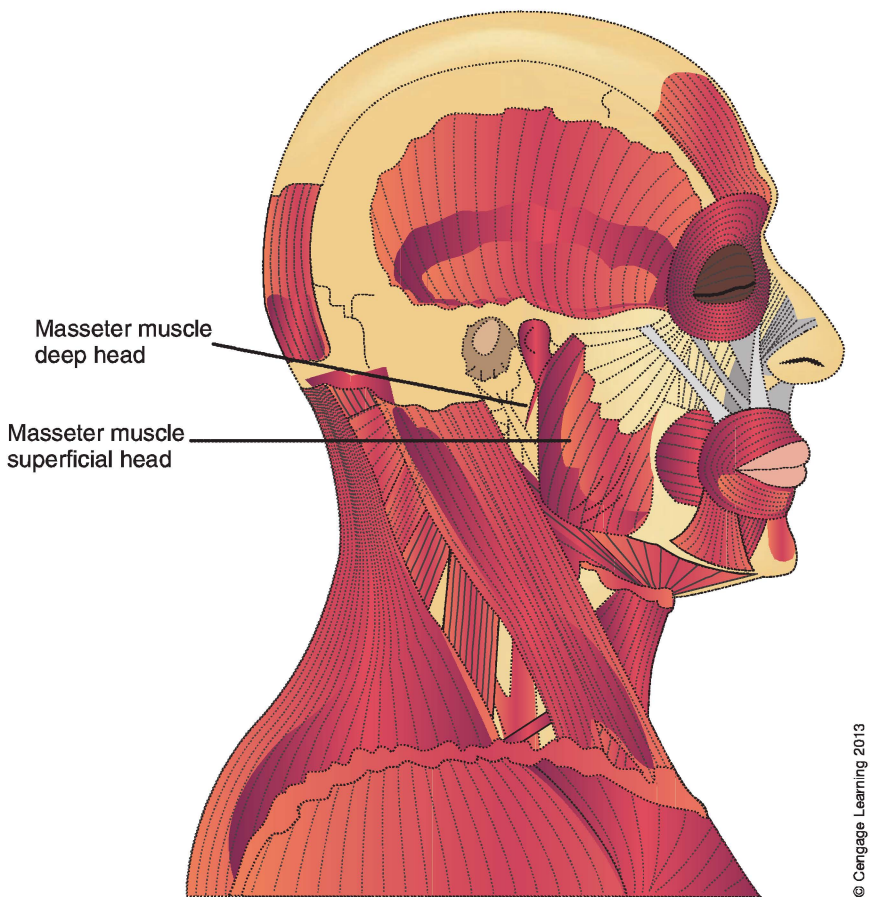

Figure 18–2. Masseter muscle, showing deep and superficial heads.

process of the mandible. The superficial fibers insert in the outer surface of the angle of the mandible. Contraction of this muscle causes the mandible to elevate. It is easily observed when the jaws are clenched.

Medial Pterygoid

The **medial pterygoid** muscle also has both a superficial and a deep origin. The superficial fibers begin at the maxillary tuberosity, while the deep fibers arise from the medial side of the lateral pterygoid plate (**Figure 18–3** and **Figure 18–4**). The muscle inserts on the medial surface of the angle of the mandible. Its function is to elevate the mandible.

Lateral Pterygoid

The smaller, superior head of the **lateral pterygoid** muscle starts from the infratemporal surface of the sphenoid bone and inserts into the articular disc of the temporomandibular joint (see **Figure 18–3** and **Figure 18–4**). The larger, inferior head arises from the lateral surface of the lateral pterygoid plate and inserts in the pterygoid fovea of the mandible. Remember that the origin of the medial pterygoid is the medial surface of the lateral pterygoid plate. If both pterygoid muscles contact, the jaw protrudes. If only one lateral pterygoid muscle contracts, there is a lateral shift of the mandible to the opposite side.

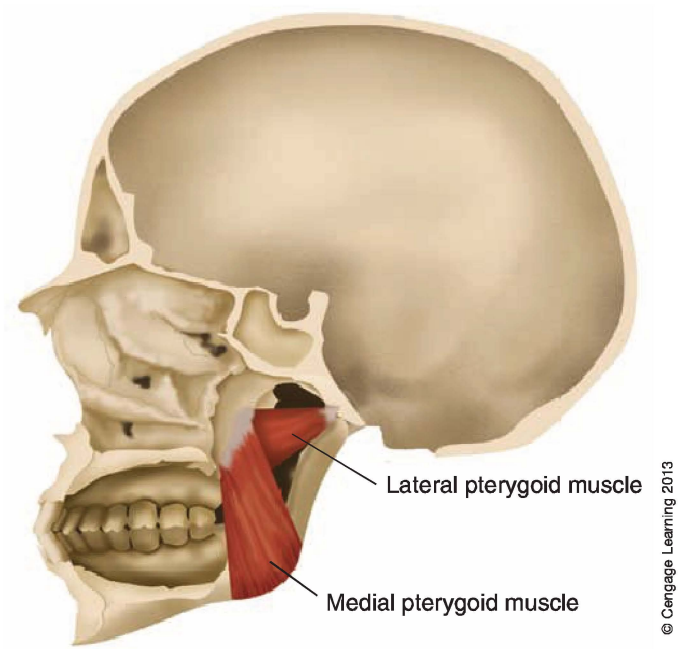

Figure 18–3. Medial and lateral pterygoid muscles—internal aspect.

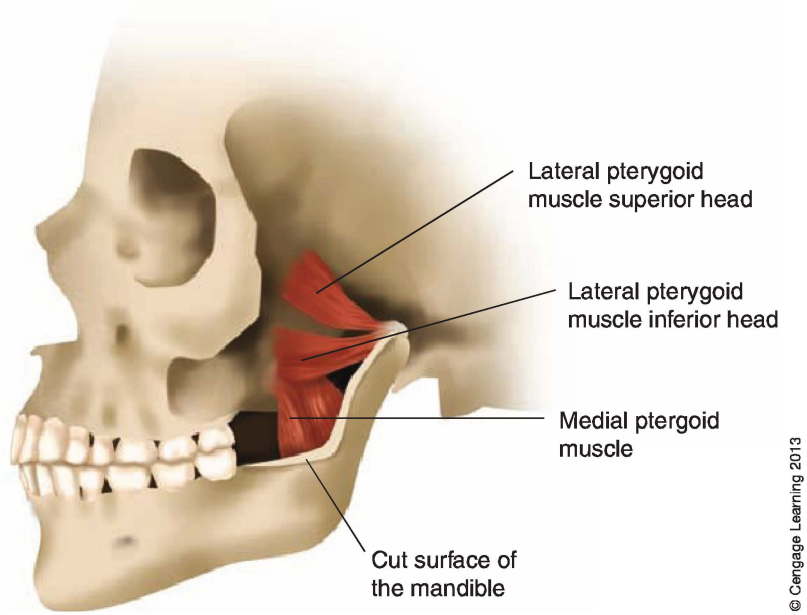

Figure 18–4. Pterygoid muscles—lateral aspect (coronoid process and anterior half of ramus of mandible removed).

SUPRAHYOID MUSCLES

The **suprahyoid muscles** are located above the hyoid bone. They are found between the mandible and the hyoid bone and function to lower the mandible or raise the hyoid bone.

Digastric

This slinglike muscle has fibers at either end and is connected in the center by an intermediate tendon or sling (**Figure 18–5** through **Figure 18–7**). The anterior belly begins on the digastric fossa of the mandible (the inferior surface of the mandible at the midline) and inserts into the intermediate tendon. The posterior belly starts from the intermediate tendon and inserts on the digastric notch (medial to the mastoid process). The anterior belly is innervated by the mandibular branch of the trigeminal nerve (V_3). The posterior belly is innervated by the facial nerve (VII).

Mylohyoid

This muscle creates the floor of the mouth (see **Figure 18–5 A** and **B** through **Figure 18–7**). It begins on the mylohyoid line of the mandible and inserts

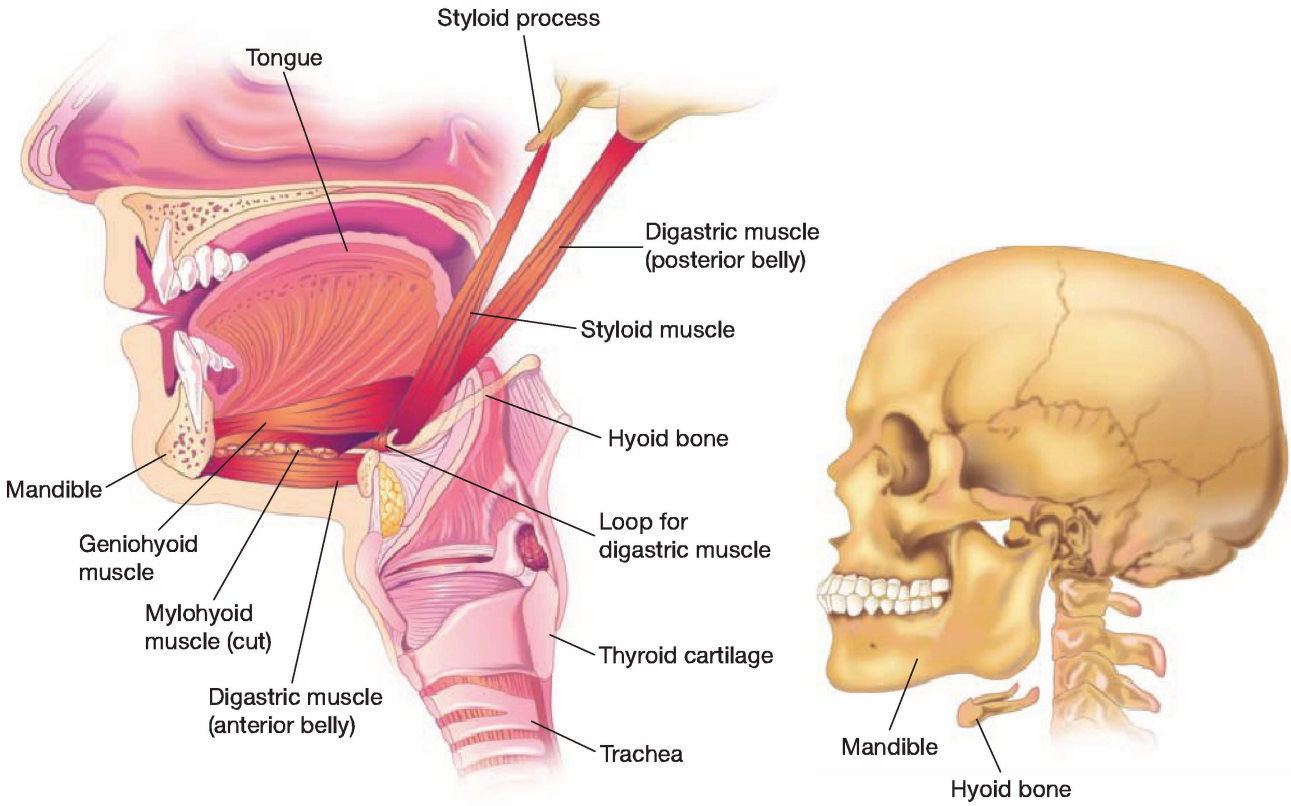

Figure 18–5. Mylohoid muscles and the hyoid bone.

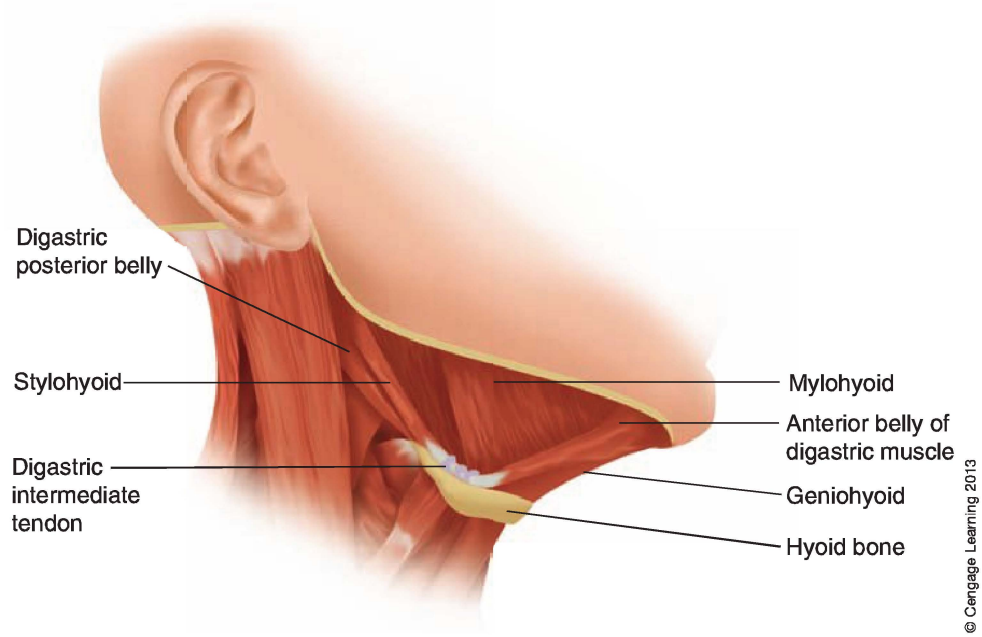

Figure 18–6. Suprahyoid muscles.

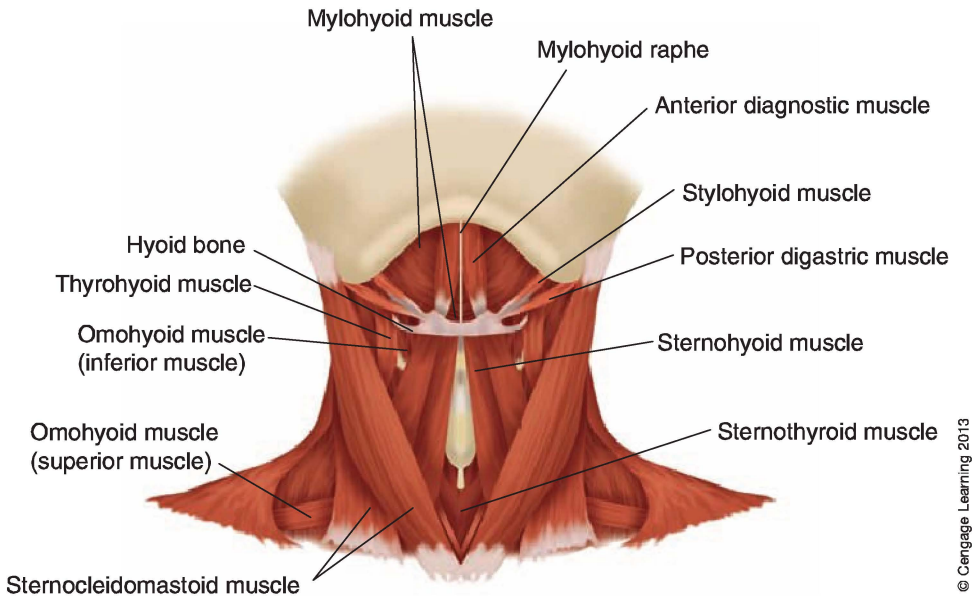

Figure 18–7. Anterior view of the neck.

into a raphe at its midline. It is innervated by the mandibular branch of the trigeminal nerve (V_3).

Geniohyoid

This muscle arises from the genial tubercles of the mandible and inserts on the hyoid bone (see **Figure 18–6**). It is innervated by the hypoglossal nerve (XII) and is located above the mylohyoid muscle.

Stylohyoid

The origin of this muscle is the styloid process, and its insertion is the hyoid bone. It lies near the posterior belly of the digastric (**Figure 18–6** through **Figure 18–9**). It is innervated by the same branch of the facial nerve that supplies the posterior belly of the digastric.

INFRAHYOID MUSCLES

The **infrahyoid muscles** are located below the hyoid bone, in front of the neck. They function to depress the hyoid or fix it in place so the suprahyoid can work. They are innervated by the first, second, and third cervical nerves.

Omohyoid

This muscle has two bellies that are joined by an intermediate tendon (see **Figure 18–7** and **Figure 18–8**). The inferior belly comes from the scapula and ends on the intermediate tendon, while the superior belly originates on the intermediate tendon and inserts on the hyoid bone.

Sternohyoid

The origin of this muscle is the sternum, and its insertion is the hyoid bone (see **Figure 18–7** and **Figure 18–8**).

Sternothyroid

This muscle arises from the sternum and inserts on the thyroid cartilage (see **Figure 18–7**). It is located below the sternohyoid.

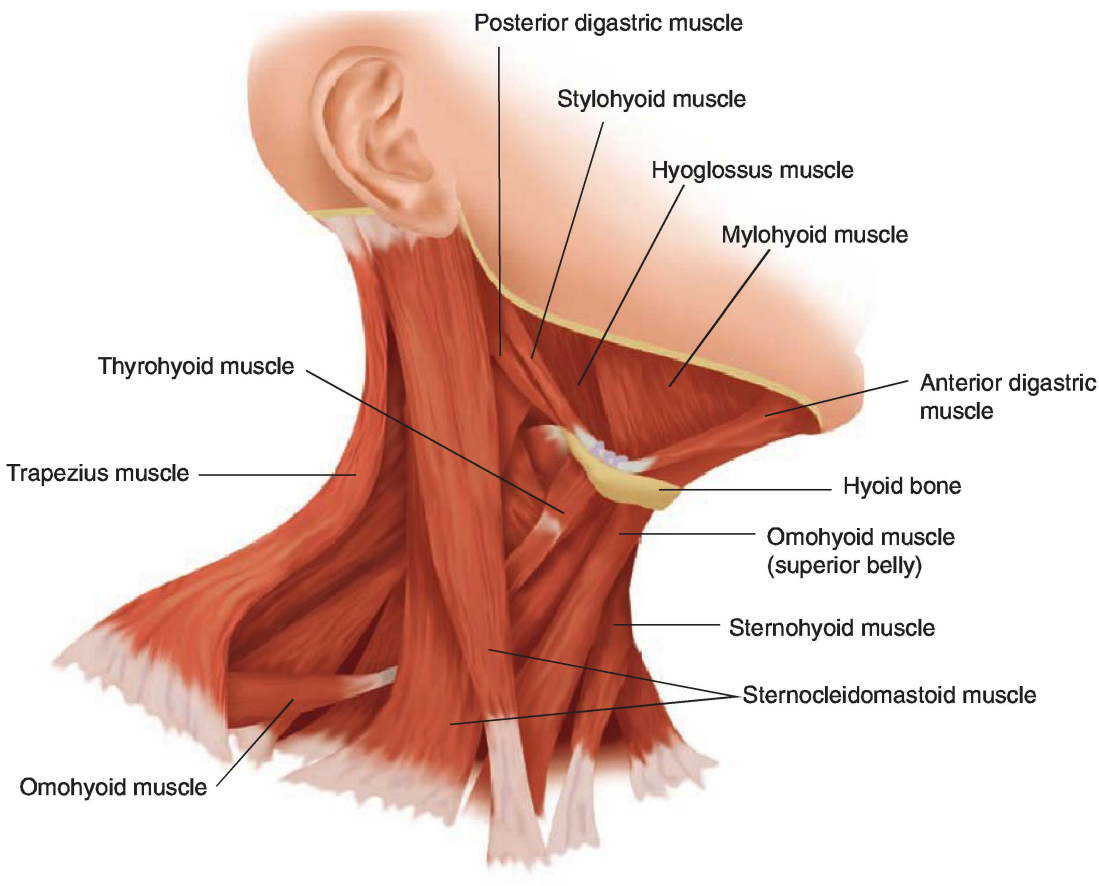

Figure 18–8. Lateral view of the neck.

Thyrohyoid

This muscle originates on the thyroid cartilage and inserts on the hyoid bone (see Figure 18–8).

MUSCLES OF THE TONGUE

The **muscles of the tongue** are divided into two groups, intrinsic and extrinsic. These muscles help the tongue to change its shape and position. Tongue muscles are innervated by the hypoglossal nerve (XII).

Intrinsic Muscles

The **intrinsic tongue muscles** lie in and are contained entirely within the tongue. They are responsible for changes in the shape of the tongue and are named for the direction in which they run. These muscles are confluent, so they are not viewed as individual muscles.

SUPERIOR LONGITUDINAL

This muscle runs the length of the tongue from anterior to posterior. Located near the top of the tongue, it functions to widen the tongue and turn the tip up.

INFERIOR LONGITUDINAL

This muscle also runs the length of the tongue from anterior to posterior; however, it lies near the bottom of the tongue. It also widens the tongue, but turns the tip down.

TRANSVERSE

This muscle is found on the lateral edges of the tongue. Its function is to make the tongue narrow.

VERTICAL

This muscle runs from the upper surface to the lower surface of the tongue. It aids in widening the tongue tip.

Extrinsic Muscles

The **extrinsic tongue muscles** originate from close structures and insert on or intermingle with intrinsic muscles. They aid in positioning the tongue.

GENIOGLOSSUS

The origin of this muscle is the genial tubercles, and its insertion is on the tongue and hyoid bone (see Figure 18–9). Anterior fibers retract the tongue,

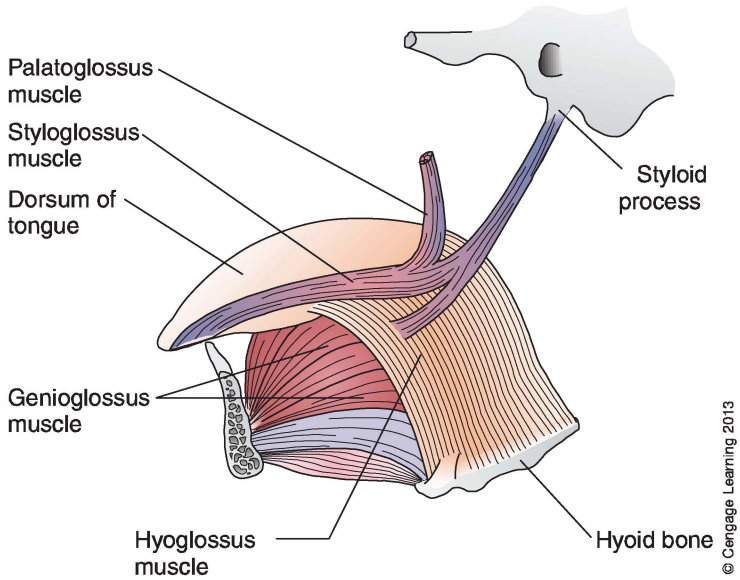

Figure 18–9. Extrinic muscles of the tongue.

and posterior fibers push it forward. This muscle does a majority of work for the tongue.

HYOGLOSSUS

This muscle originates on the hyoid bone and inserts on the side of the tongue. It depresses the tongue and draws the sides down (see **Figure 18–9**).

STYLOGLOSSUS

This muscle is from the styloid process and has two insertions on the tongue. One head intermingles with the inferior longitudinal and the other joins with the hyoglossus. The styloglossus draws the tongue up and backward.

MUSCLES OF FACIAL EXPRESSION

Contraction of the **muscles of facial expression** results in a wide variety of facial expressions. The facial nerve (VII) provides innervation to these muscles. These muscles are symmetric and work in groups.

Muscles of the Scalp

The **muscles of the scalp** (or *occipitofrontalis* [*epicranius*]) is comprised of two groups, the *frontalis* and *occipitalis* (**Figure 18–10**). This muscle pulls the scalp forward and backward and raises the eyebrows.

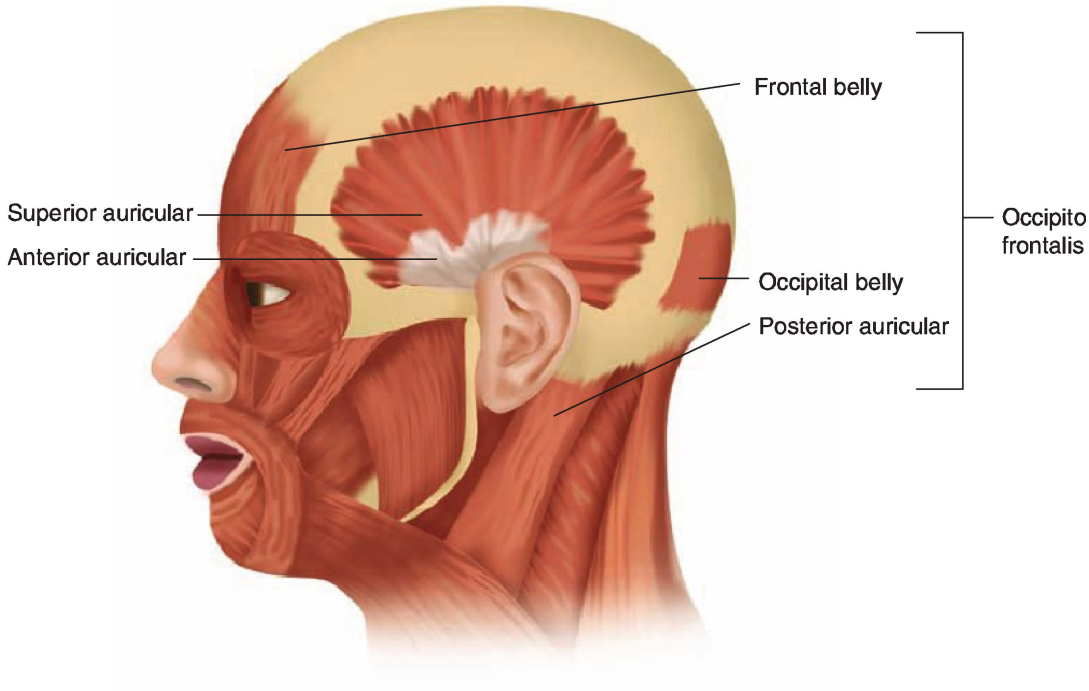

Figure 18–10. Muscles of the scalp and ears.

Muscles of the Ears

There are three groups of **muscles of the ears**: *anterior auricular*, *posterior auricular*, and *superior auricular* (see **Figure 18–10**). They are respectively located in front of, behind, and above the ear. These muscles may draw the ear forward and backward or elevate the ear.

Orbicularis Oculi

This muscle encircles the eye. It is divided into orbital and palpebral (eyelid) sections, and it functions to close the eyes.

Procerus

This muscle runs from the bridge of the nose to the eyebrow (**Figure 18–11**). It pulls the eyebrows downward.

Corrugator

The *corrugator* muscle runs along the eyebrow and inserts on the medial end of the eyebrow (see **Figure 18–11**). It pulls the eyebrow down and in.

Muscles of the Nose

The **muscles of the nose** include the *nasalis*, which is divided into two parts: the *compressor nares* and the *dilator nares* (see **Figure 18–11**). The compressor nares close the nostrils. The dilator nares cause flaring of the nostrils.

Muscles of the Mouth

ORBICULARIS ORIS

The *orbicularis oris*, which is one of the **muscles of the mouth**, has no skeletal attachment. It encircles the mouth and composes the lips (**Figure 18–12**). Its function is to close the lips or protrude them. Its fibers interface with other perioral muscles.

LEVATOR LABII SUPERIORIS ALAEQUE NASI

This tiny muscle inserts on the ala of the nose and runs to the upper lip (**Figure 18–13**). It raises the upper lip and ala of the nose producing a sneer.

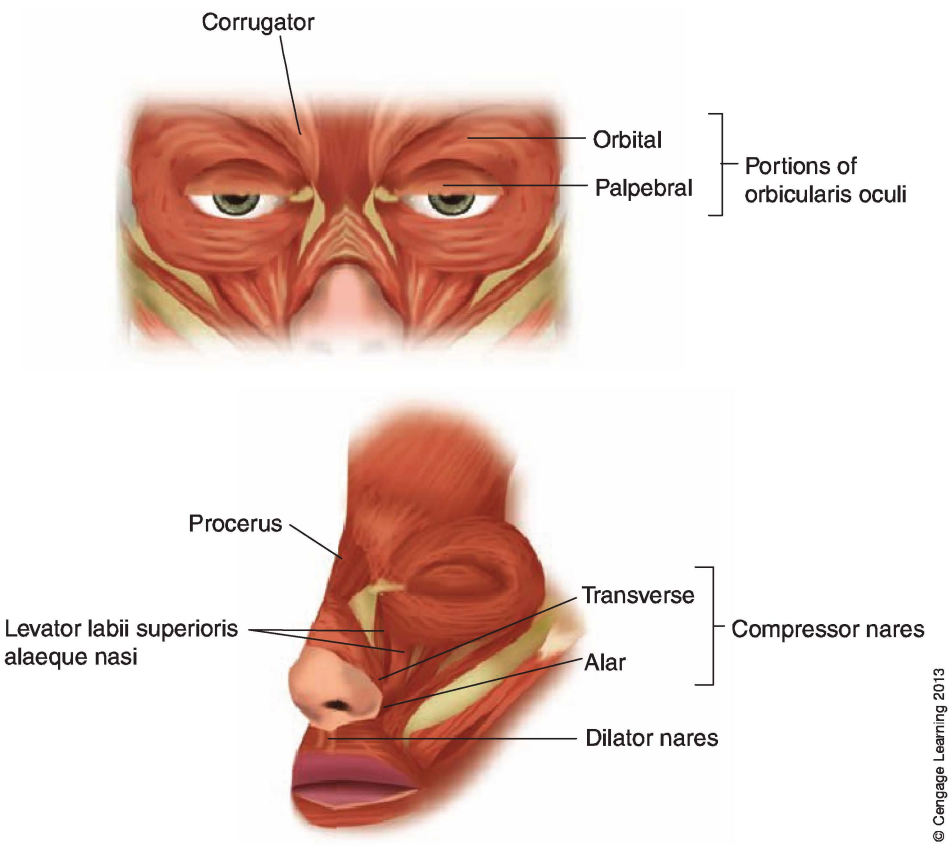

Figure 18–11. Muscles of the (A) eye and (B) nose.

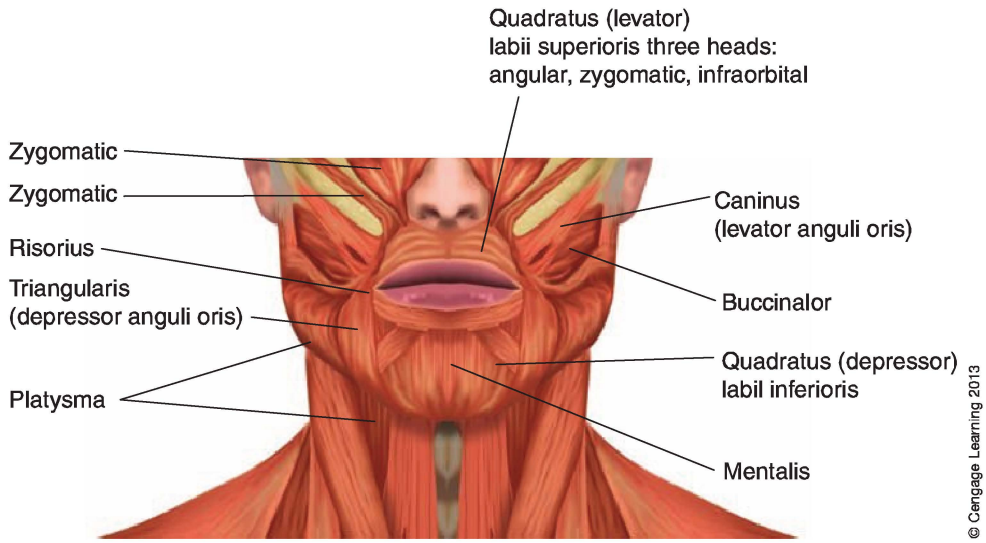

Figure 18–12. Muscles of facial expression in the lower face.

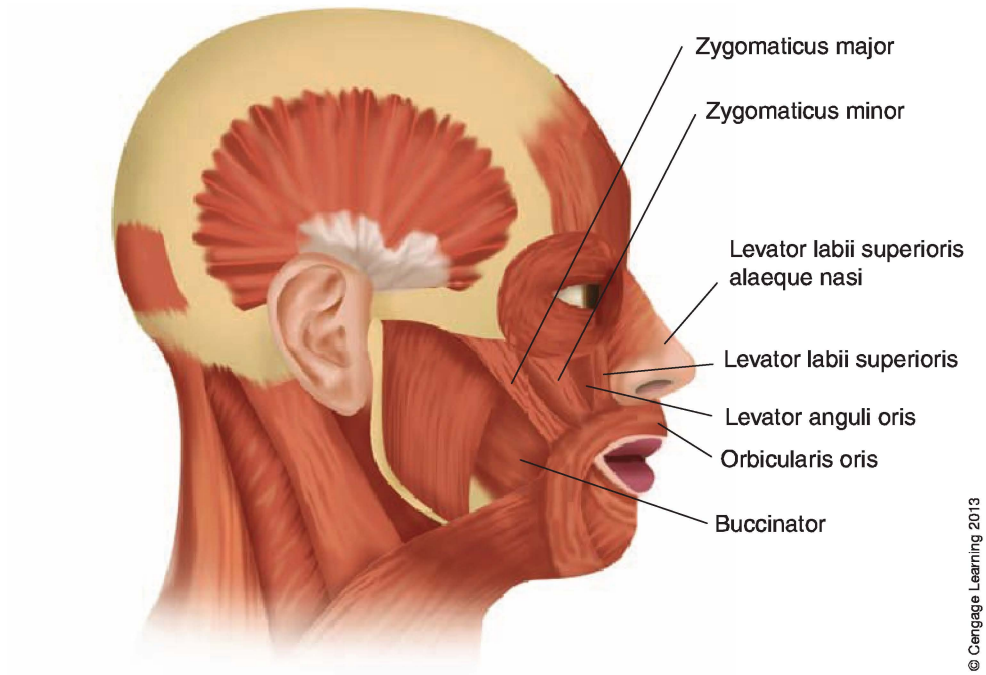

Figure 18–13. Muscles that elevate the upper lip and angle of the mouth.

LEVATOR LABII SUPERIORIS OR QUADRATUS LABII SUPERIORIS

This muscle runs above the mouth and has the following three heads:

1. *Angular*—near the nose
2. *Infraorbital*—lower edge of orbit
3. *Zygomatic*—zygomatic bone

All three heads insert onto the upper lip and help elevate the upper lip (see **Figure 18–13**).

ZYGOMATIC

The origin of this muscle is the zygomatic bone, and it inserts into the corner of the mouth or the *modiolus*, an area of intertwining muscles. It elevates the angle of the mouth up and laterally, producing a smile. It may be divided into zygomatic major and minor muscles (see **Figure 18–12** and **Figure 18–13**).

LEVATOR ANGULI ORIS OR CANINUS

The origin of this muscle is the canine fossa, a depression near the canine roots below the infraorbital foramen. It inserts into the *modiolus* and aids in elevating the corner of the mouth (see **Figure 18–12** through **Figure 18–14**), producing a smile.

BUCCINATOR

This muscle forms the cheek (**Figure 18–15**). It originates from the alveolar process of the mandible, the maxilla, and the pterygomandibular raphe, a fibrous band that runs from the pterygoid hamulus to the mylohyoid line. It blends with the orbicularis oris at the modiolus. The *buccinator* holds the cheek against the teeth and keeps food on the occlusal surfaces during mastication. Because of this function, it is considered an accessory muscle to the muscles of mastication.

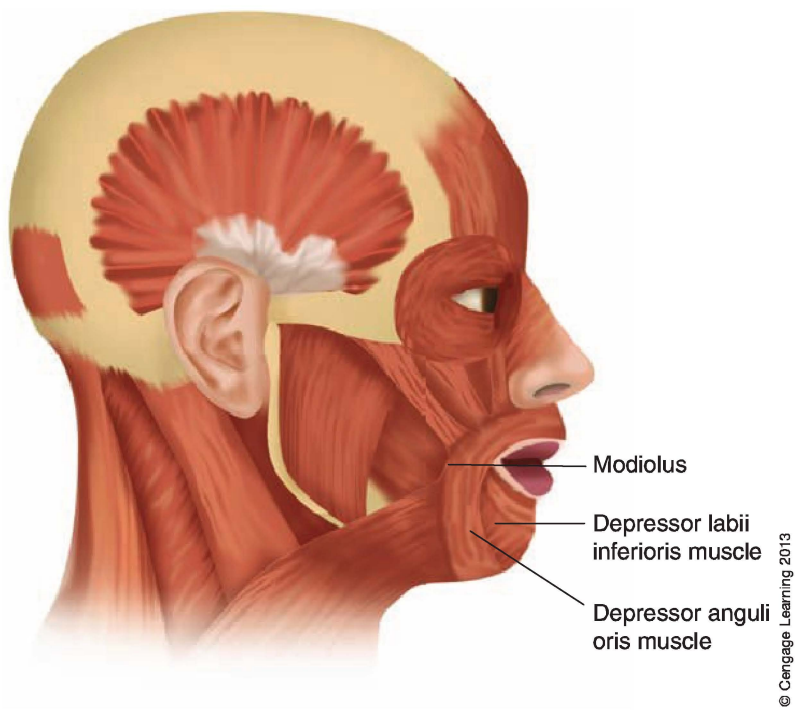

Figure 18–14. Muscles the depress the lower lip and angle of the mouth.

RISORIUS

This muscle originates on the anterior border of the masseter muscle and inserts into the modiolus (see **Figure 18–12** and **Figure 18–13**). It pulls the angle of the mouth laterally and produces a wide smile.

DEPRESSOR ANGULI ORIS OR TRIANGULARIS

This muscle arises from the external oblique line of the mandible and inserts into the modiolus (see **Figure 18–12**). It pulls the corner of the mouth downward and inward, producing a frown.

DEPRESSOR LABII INFERIORIS OR QUADRATUS LABII INFERIORIS

This muscle also arises from the external oblique line; however, it inserts into the skin of the lower lip (see **Figure 18–12** and **Figure 18–14**). It functions to pull the lower lip down and laterally, showing the mandibular anterior teeth.

MENTALIS

This is the only muscle whose fibers run away from the lips (see **Figure 18–12**). Its origin is a fossa or depression beneath the mandibular anterior teeth, and it inserts into the skin of the chin. It can raise the skin of the chin and protrude the lower lip. It often interferes with treatment of mandibular anterior labial surfaces when contracted.

MUSCLES OF THE NECK

Platysma

The *platysma*, one of the **muscles of the neck**, is a thin sheet of muscle located just below the skin of the neck (**Figure 18–15** and **Figure 18–16**). Its origin is the clavicle and shoulder; it travels upward to insert on the lower border of the mandible as well as on the skin and muscle of the lower face and mouth. Contraction of this muscle wrinkles the skin of the chin and neck, and draws the outer part of the lower lip down and back, producing a grimace. It is innervated by the facial nerve (VII).

Trapezius

This is a large muscle covering the back of the neck, shoulder, and clavicle (**Figure 18–8** and **Figure 18–16**). It originates from the external occipital protuberance and inserts into the clavicle and shoulder. This muscle produces a shoulder shrug. The spinal accessory nerve (XI) provides innervation to this muscle.

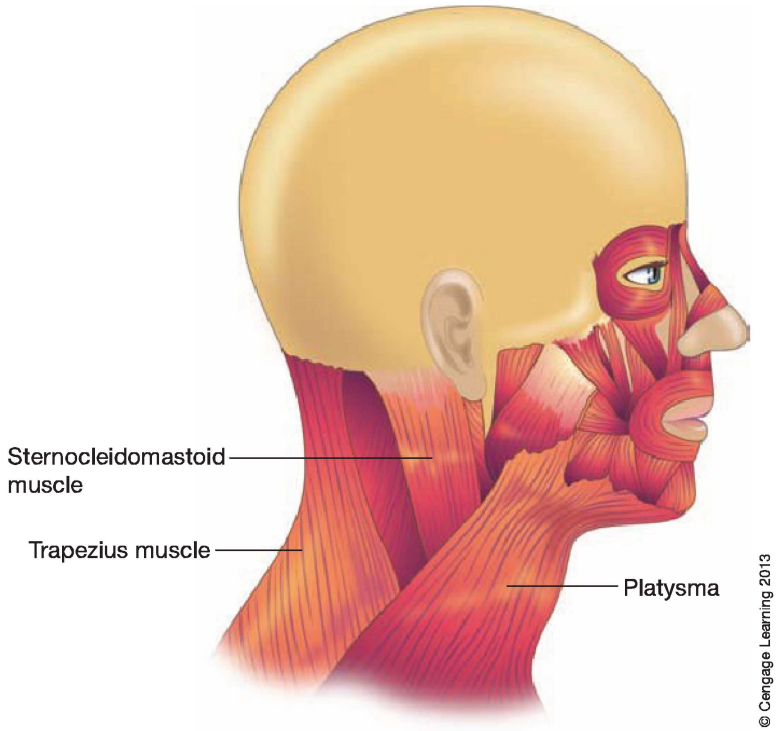

Figure 18–15. Muscles of the Neck—lateral aspect.

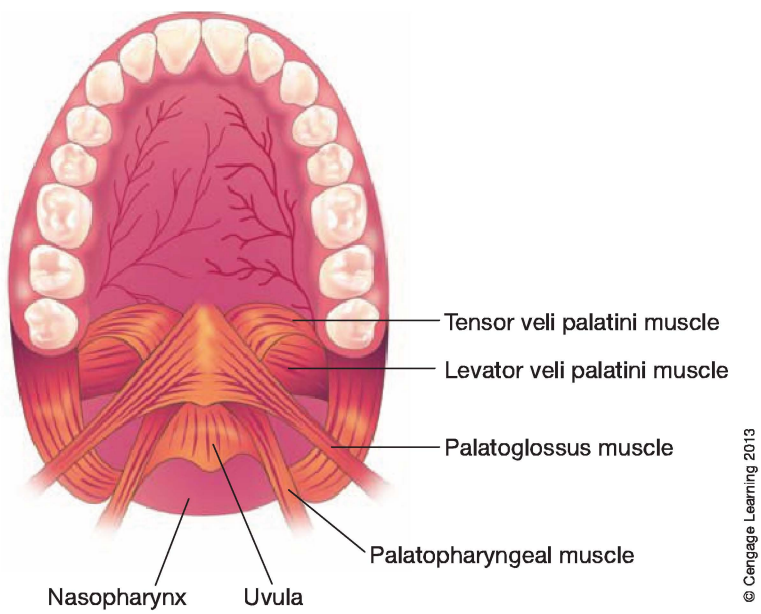

Figure 18–16. Muscles of the soft palate.

Sternocleidomastoid

This prominent muscle arises by two heads, from the top of the sternum and clavicle (see **Figure 18–7** , **Figure 18–8** , **Figure 18–15** , and **Figure 18–16**). The two heads blend together and insert on the mastoid process and the superior nuchal line of the occipital bone. This muscle turns the chin upward to the opposite side when the head is turned laterally. Innervation is provided by the spinal accessory nerve (XI).

MUSCLES OF THE SOFT PALATE

The **muscles of the soft palate** raise the soft palate during **deglutition**, or swallowing.

Palatoglossal or Palatoglossus

This muscle forms the anterior tonsillar arch (in front of the tonsils). Its origin is the underside of the soft palate and its insertion is the posterior side of the tongue. It is innervated by the pharyngeal plexus, a group of branches from the glossopharyngeal (IX), vagus (X), and spinal accessory (XI) nerves. Its contraction pulls the sides of the tongue up and back, and the soft palate down. It also constricts the pillars.

Palatopharyngeal or Palatopharyngeus

This muscle forms the posterior tonsillar pillar (**Figure 18–17** and **Figure 18–18**). Contraction of this muscle causes the pharynx to elevate. It is innervated by the pharyngeal plexus.

Uvula

This small mass of tissue hangs down in the throat from the soft palate (see **Figure 18–17**). Upon contraction, the *uvula* will shorten. Innervation is through the pharyngeal plexus.

Levator Veli Palatini

This muscle originates from the petrous portion of the temporal bone, and it inserts in the soft palate (see **Figure 18–17** and **Figure 18–18**). It pulls the soft palate upward and back, and is innervated by the pharyngeal plexus.

Tensor Veli Palatini

This muscle arises from the medial pterygoid plate and auditory tube (see **Figure 18–17** and **Figure 18–18**). It turns upward, curves around the pterygoid hamulus, and then inserts into the soft palate. It tenses (hence the name) the soft palate by pulling on the lateral sides. It is innervated by the mandibular branch of the trigeminal nerve (V_3).

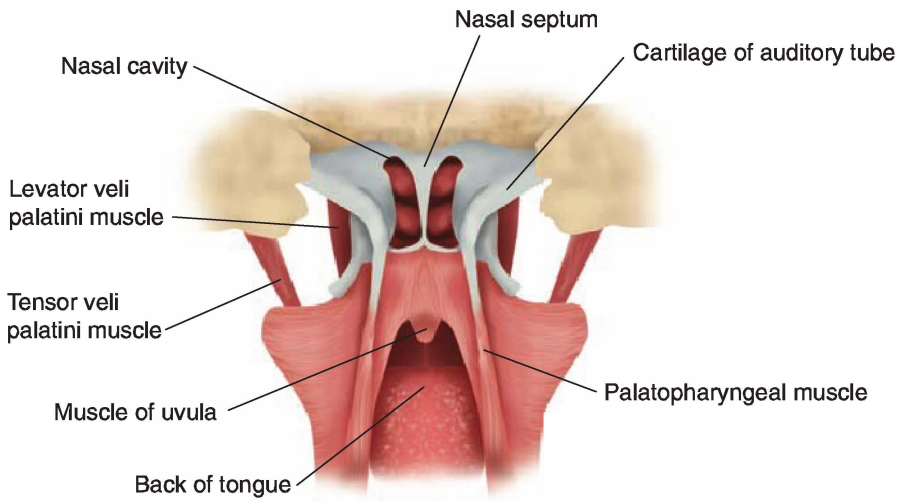

Figure 18–17. Posterior view of the muscles of the soft palate.

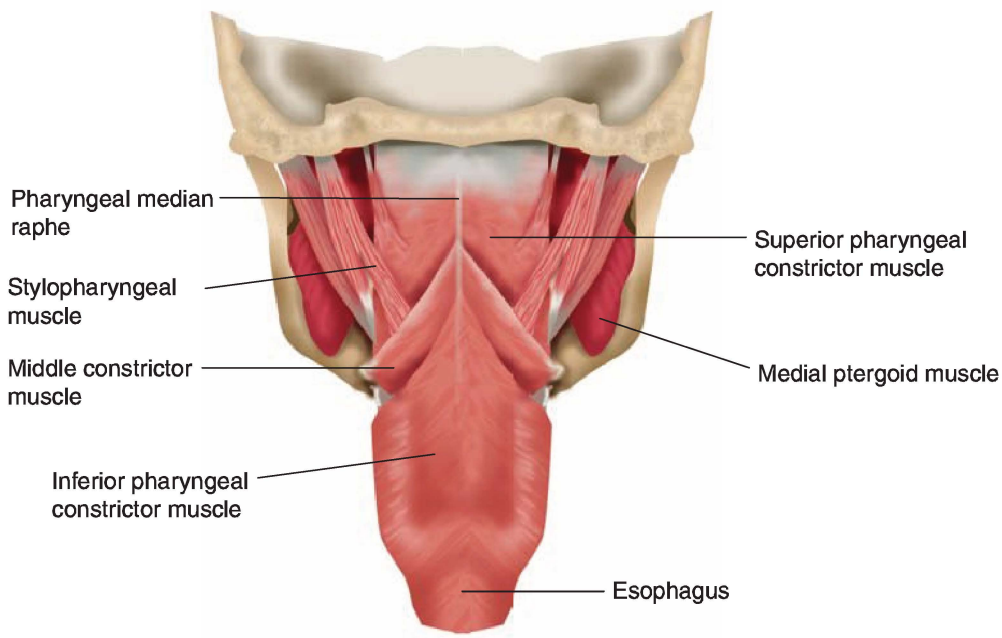

Figure 18–18. Posterior view of the pharyngeal wall.

MUSCLES OF THE PHARYNX

The *pharynx* is a muscular tube. The **muscles of the pharynx** consist of three constrictor muscles and three smaller muscles. All the muscles function in deglutition, or swallowing. All constrictors are innervated by the pharyngeal plexus.

Superior Constrictor

The origin of this muscle is the pterygoid hamulus, medial pterygoid plate, pterygomandibular raphe, and the mylohyoid line (see **Figure 18–18**). All three constrictors insert and unite on the *median raphe*.

Middle Constrictor

The origins for this muscle are greater and lesser horns of the hyoid bone and the stylohyoid ligament (see **Figure 18–18**). It unites with the superior constrictor at the median raphe.

Inferior Constrictor

This muscle originates from the thyroid cartilage of the larynx (see **Figure 18–19**). Its fibers join at the median raphe. Fibers of all three constrictors overlap each other.

Palatopharyngeal

This muscle forms the posterior tonsillar pillar. Previously, this muscle was discussed as a muscle of the soft palate. Its function is to elevate the pharynx, so it is also listed here under muscles of the pharynx.

Elevators and Dilators of the Pharynx

SALPINGOPHARYNGEAL

The origin of this muscle is the auditory tube. Its fibers blend with the palatopharyngeal muscle. It helps to elevate the pharynx, and it is innervated by the pharyngeal plexus.

STYLOPHARYNGEAL

This muscle arises from the styloid process and inserts on the thyroid cartilage (see **Figure 18–18**). It helps to elevate and dilate the pharynx. Innervation is supplied by the glossopharyngeal nerve (IX).

Deglutition

Swallowing is divided into three stages: *oral*, *pharyngeal*, and *esophageal*.

ORAL STAGE

During the oral stage of swallowing, the bolus—a ball of chewed food mixed with saliva—is centered on the tongue. The tongue is then raised up and back and a seal is made between the hard palate and the tongue. The sides of the tongue seal against the teeth and the mucosa of the hard palate. The bolus is moved backward by the intrinsic and extrinsic muscles of the tongue, as well as by the suprahyoid muscles. The muscles of mastication hold the teeth together. The bolus is now positioned onto the posterior tongue. The upward and backward movement of the tongue causes the muscles of the soft palate to elevate the soft palate.

PHARYNGEAL STAGE

The fauces are narrowed by the palatoglossal muscle. The soft palate contacts the posterior pharyngeal wall. The stylopharyngeal and salpingopharyngeal muscles elevate and dilate the pharynx to make room for the bolus that has just entered the pharynx. The superior, middle, and inferior constrictors squeeze the pharynx, propelling the bolus into the lower end of the pharynx.

The thyroid cartilage of the larynx is raised and brought forward by the thyrohyoid muscle and other muscles. The epiglottis protects the larynx from the bolus. The food is then propelled into the upper part of the esophagus.

ESOPHAGEAL STAGE

The bolus is propelled by peristaltic contractions into the stomach.

SUMMARY

The muscles of the head and neck are divided into eight groups: (1) the *muscles of mastication*, including the temporalis, masseter, and medial and lateral pterygoid, which cause the movement of the mandible; (2) the *suprahyoid* muscles, including the digastric, mylohyoid, geniohyoid, and stylohyoid, which cause movement of the lower mandible and raise the hyoid bone; (3) *infrahyoid* muscles, including omohyoid, sternohyoid, sternothyroid, and thyrohyoid, which depress the hyoid bone or hold it in place so the suprahyoids can work; (4) the *muscles of the tongue*, including the various intrinsic muscles, which change the shape of the tongue, and the various extrinsic

muscles, which position the tongue; (5) the *muscles of facial expression*, including the various muscles of the scalp, ear, eye, nose, and neck, which control facial expression; (6) the *muscles of the neck*, including the platysma, trapezius, and sternocleidomastoid, which control the movement of the head, chin, neck, and lips; (7) the *muscles of the soft palate*, including the palatoglossal, palatopharyngeal, uvula, and the levator and tensor veli palatini, which raise the soft palate during swallowing; and (8) the *muscles of the pharynx*, including the superior, middle, and inferior constrictors, palatopharyngeal, salpingopharyngeal, and stylopharyngeal, which control swallowing, allowing the elevation and dilation of the pharynx.

Define the following terms

origin
insertion
modiolus
deglutition

Complete the chart on the muscles of mastication

Muscle	Origin	Insertion	Function
Masseter			
Temporalis			
Lateral pterygoid			
Medial pterygoid			

List the steps that occur during each phase of swallowing

Label the muscles indicated by the lines

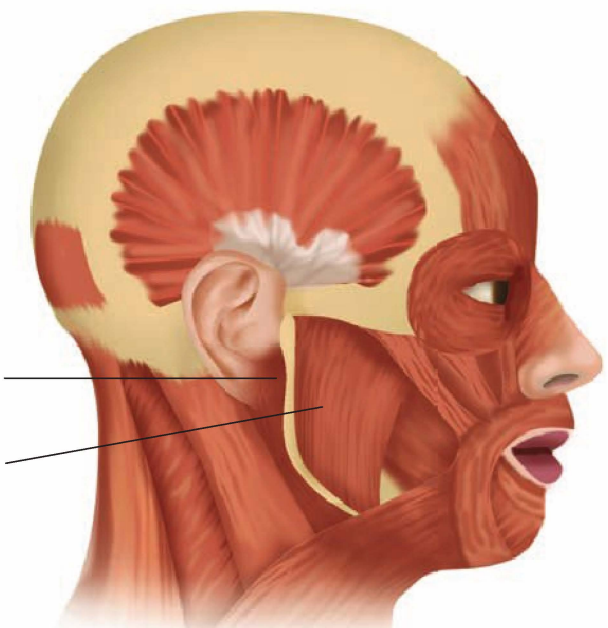

© Cengage Learning 2013

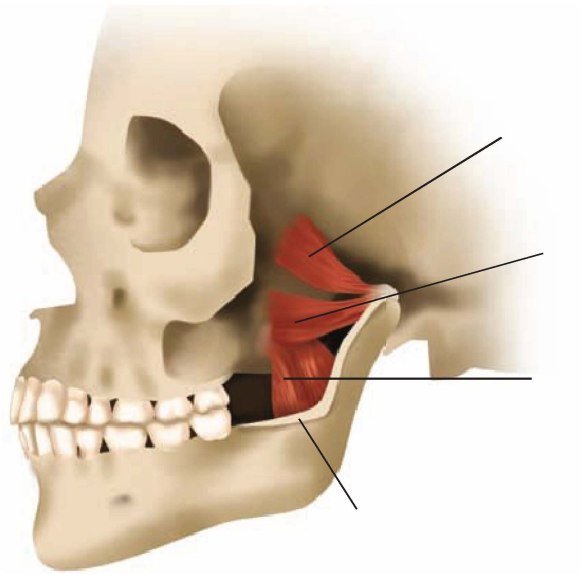

© Cengage Learning 2013

Answer the following multiple-choice questions

1. Which of these muscles does NOT elevate the mandible to close the mouth?

- **a.** masseter
- **b.** temporalis
- **c.** medial pterygoid
- **d.** lateral pterygoid
- **e.** all of the above elevate the mandible.

2. Which of these muscles has fibers that primarily run horizontally?

- **a.** masseter
- **b.** temporalis
- **c.** medial pterygoid
- **d.** lateral pterygoid
- **e.** none of the above

3. Which of these is NOT a suprahyoid muscle?

- **a.** geniohyoid
- **b.** stylohyoid
- **c.** thyrohyoid
- **d.** digastric
- **e.** all of the above are suprahyoid muscles

4. Which muscle forms the floor of the mouth?

a. mylohyoid
b. geniohyoid
c. digastric
d. stylohyoid
e. risorius

5. The facial muscles greatly influence all of the following except:

a. speech
b. appearance
c. swallowing
d. mastication

CHAPTER 19

Nerves of the Head and Neck

General Information

The Cranial Nerves

The Trigeminal Nerve

The Facial Nerve (VII)

The Glossopharyngeal Nerve (IX)

The Hypoglossal Nerve (XII)

Objectives

At the completion of this chapter, you will be able to:

- Identify the three parts of a neuron.
- Identify the names and numbers of the cranial nerves.
- Define the following terms: neuron, dendrite, axon, efferent, afferent, somatic, and visceral.
- Describe the central, peripheral, and autonomic nervous systems.
- Differentiate between sympathetic and parasympathetic nerve supply.
- Describe the trigeminal, facial, glossopharyngeal, and hypoglossal nerves according to the following: nerve supply (sensory, motor, or both), structures supplied, teeth supplied, and exit site.

- Describe the nerve supply to each maxillary and mandibular tooth.
- Complete the worksheet at the end of the chapter.

Key Terms

Anterior superior alveolar (ASA) nerve
Autonomic nervous system (ANS)
Axon
Cell body
Central nervous system (CNS)
Cranial nerves
Dendrite
Facial nerve
Glossopharyngeal nerve
Hypoglossal nerve
Inferior alveolar nerve
Lingual nerve
Mandibular nerve
Maxillary nerve
Middle superior alveolar (MSA) nerve
Motor-efferent
Neuron
Ophthalmic nerve
Parasympathetic
Peripheral nervous system (PNS)
Posterior superior alveolar (PSA) nerve
Sensory-afferent
Somatic
Sympathetic
Trigeminal nerve
Visceral

GENERAL INFORMATION

Our nervous system has two parts: the **central nervous system (CNS)** and the **peripheral nervous system (PNS)**. The central nervous system is further classified into two parts: the *brain*, which is housed in the cranium, and the *spinal cord*, which is contained within the vertebral column. The peripheral nervous system is comprised of the nerves that travel away from the central nervous system. There are 12 pairs of *cranial* nerves and 31 pairs of *spinal nerves* in the peripheral nervous system. Through the peripheral nervous system, all parts of the body are connected to the central nervous system.

A nerve cell is also known as a **neuron**. A neuron has three parts (**Figure 19–1**):

1. **Cell body**
2. **Dendrite**—a process that conducts impulses toward the cell body. A neuron may have one or many dendrites.
3. **Axon**—a process that carries impulses away from the cell body. A neuron has only one axon.

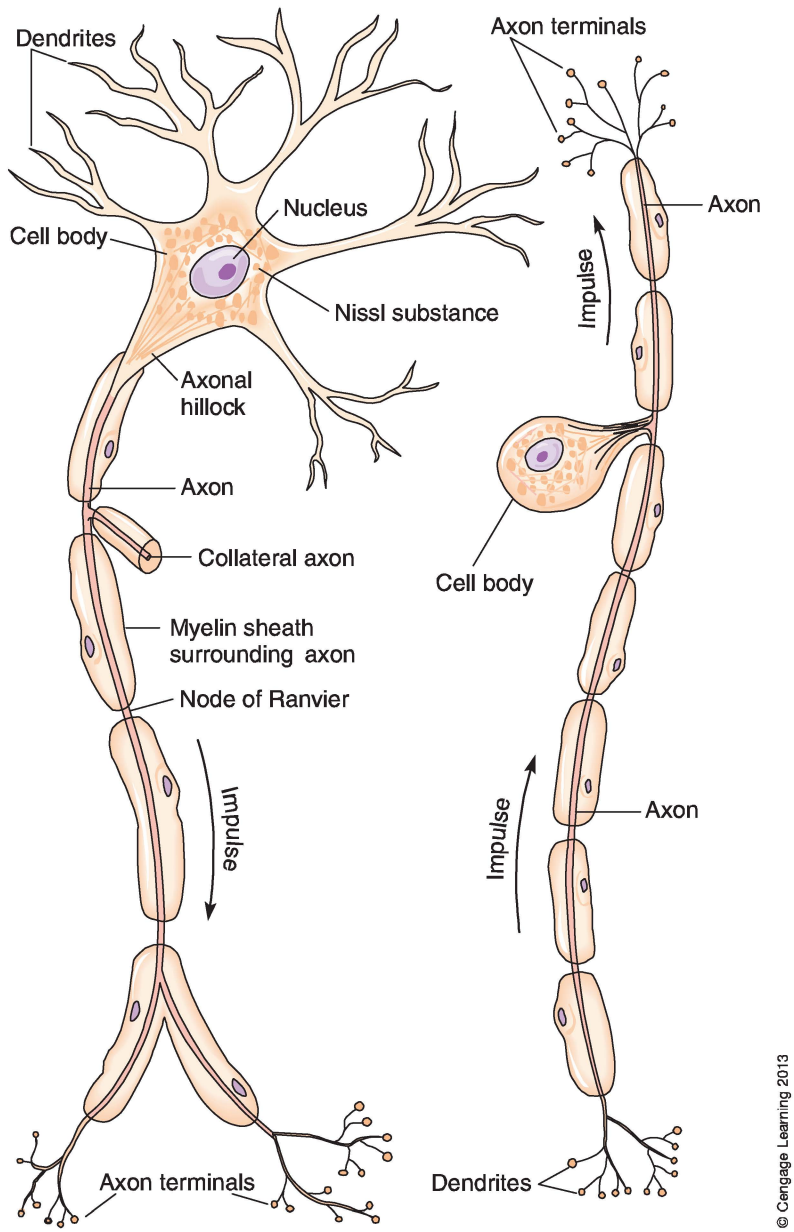

Figure 19–1. Shapes of neurons.

Nerves that carry impulses or messages toward the brain are known as **sensory** or **afferent**. Those nerves that carry impulses away from the brain are termed **motor** or **efferent**. **Somatic** nerves supply muscles, while **visceral** nerves provide innervation to the internal organs (viscera).

The **autonomic nervous system (ANS)** regulates those functions over which we have no conscious control, such as heart rate and respiratory rate. This nervous system is divided into two parts: **sympathetic** and **parasympathetic**.

Usually each organ has sympathetic and parasympathetic nerves supplying it. These systems tend to produce opposite actions.

The sympathetic system functions in response to emergencies. Sympathetic nerves increase respiration, heart rate, and blood flow to muscles. They decrease salivary flow and blood supply to the digestive tract in order that additional blood can be supplied to other muscles. This is often referred to as the "fight or flight" reaction.

The parasympathetic system slows down the heart and respiration; parasympathetic nerves increase blood to the digestive system and salivary glands.

THE CRANIAL NERVES

As mentioned before, there are 12 sets of ("paired") **cranial nerves**. They provide innervation to the right and left sides of the body, and are designated by Roman numerals. They may be entirely sensory, entirely motor, or a combination of both sensory and motor (mixed). This text concentrates on four cranial nerves that are important for dental auxiliaries: the trigeminal (V), facial (VII), glossopharyngeal (IX), and hypoglossal (XII). The remaining cranial nerves appear in **Table 19–1**.

THE TRIGEMINAL NERVE (V) (MIXED)

The **trigeminal nerve** is the largest cranial nerve and the most important to dental assistants because it provides sensory innervation from the face, scalp, teeth, nose, and mouth. It also distributes motor innervation to the muscles

TABLE 19–1. Other Cranial Nerves

CRANIAL NERVE	SENSORY (S) MOTOR (M) BOTH (B)	FUNCTION	EXIT SITE
Olfactory I	S	Sense of smell	Cribriform plate
Optic II	S	Sight	Optic foramen (canal)
Oculomotor III	M	Motor to extrinsic eye muscles (superior and inferior rectus muscles and inferior oblique)	Superior orbital fissure
Trochlear IV	M	Motor to superior oblique eye muscle	Superior orbital fissure
Abducent VI	M	Motor to lateral rectus eye muscle	Superior orbital fissure
Acoustic VIII	S	Hearing and balance	Internal acoustic (auditory) meatus
Vagus X	B	Longest cranial nerve. Sensory innervation to ear, pharynx, larynx, bronchi, lungs, heart, esophagus, stomach, intestines, and kidney. Parasympathetic control of heart rate. Contributes to pharyngeal plexus.	Jugular foramen
(Spinal) Accessory XI	M	Has a cranial and spinal part. Associated with vagus (X) nerve. Contributes to pharyngeal plexus. Motor to trapezius and sternocleidomastoid muscles.	Jugular foramen

© Cengage Learning 2013

of mastication and provides parasympathetic supply to the salivary and lacrimal glands. Sensory cells are located in the semilunar (gasserian) ganglion found in the petrous portion of the temporal bone. The motor root originates in the pons and joins the mandibular division. The trigeminal nerve has three divisions or branches (**Figure 19–2**):

1. **Ophthalmic nerve** (V_1)—entirely afferent
2. **Maxillary nerve** (V_2)—entirely afferent
3. **Mandibular nerve** (V_3)—mixed, both afferent and efferent

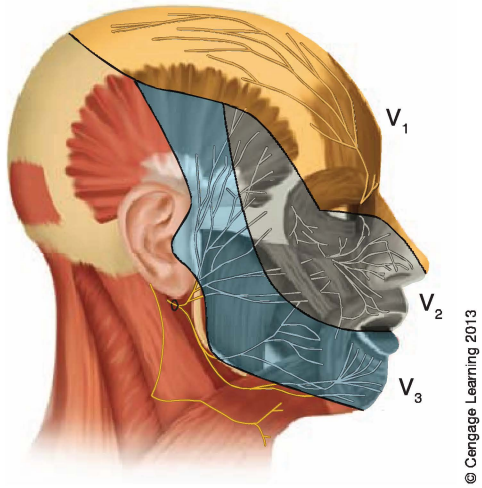

Figure 19–2. Area of distribution of the three divisions of the trigeminal nerve.

The Ophthalmic Nerve (V_1)

This nerve enters the eye through the *superior orbital fissure* and provides sensory innervation to the eye, nose, lacrimal gland, and skin of the eyelids, forehead, and nose. It has the following three branches (none of which lead to the oral cavity):

1. *Lacrimal nerve*—innervates the lacrimal glands for tear production and supplies the skin of the upper eyelid.
2. *Frontal nerve*—passes above the eye, dividing into the *supraorbital* and *supratrochlear* nerves. The supraorbital branch supplies the skin of the forehead, scalp, and upper eyelid. The supratrochlear branch supplies the skin of the forehead and upper eyelid (**Figure 19–3**).
3. *Nasociliary nerve*—runs within the orbit, passes through the ethmoid bone, and re-enters the cranium at the cribriform plate of the ethmoid bone. It then passes down into the nose and supplies the inside of the nose and skin on the side of the nose. Its branch, the *infratrochlear nerve*, supplies the medial side of the eyelids and side of the nose.

The Maxillary Nerve (V_2)

The second division of the trigeminal nerve exits the skull through the *foramen rotundum* and passes into the pterygopalatine fossa. In this fossa, the maxillary nerve divides into four branches: *zygomatic*, *infraorbital*, *posterior superior alveolar (PSA)*, and *pterygopalatine*.

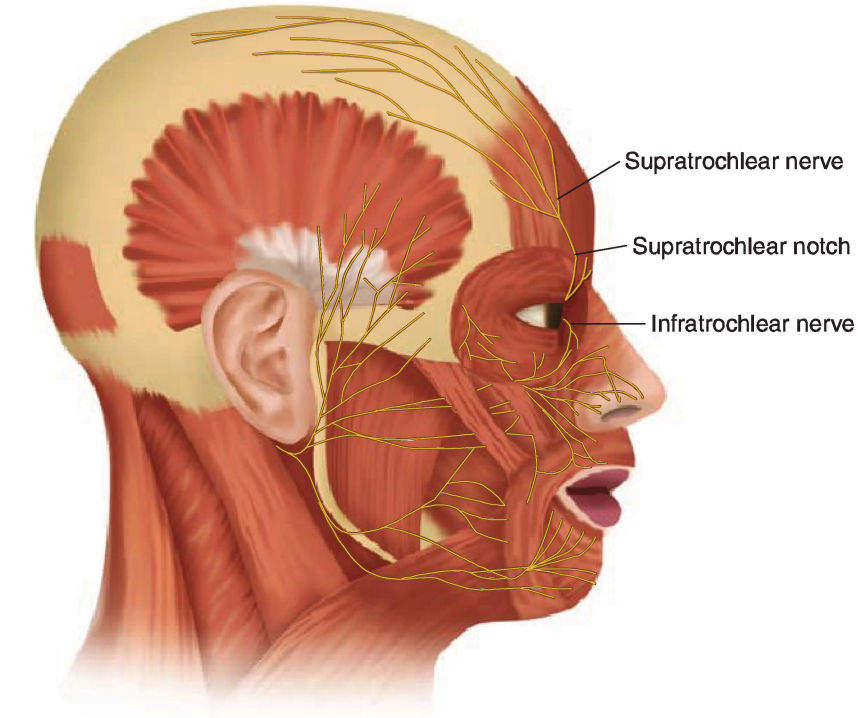

Figure 19–3. Branches of the frontal and nasociliary nerves.

THE ZYGOMATIC NERVE

This nerve enters the eye through the inferior orbital fissure. It has two branches (**Figure 19–4**):

1. *Zygomaticotemporal*—supplies the skin and side of the forehead
2. *Zygomaticofacial*—supplies the skin of the cheek

THE INFRAORBITAL NERVE

This nerve emerges onto the face through the *infraorbital foramen* on the maxilla, but before this nerve exits through the infraorbital foramen it gives off two descending branches (**Figure 19–5**).

1. The **middle superior alveolar (MSA) nerve** provides innervation to the mesiobuccal root of the maxillary first molar, the maxillary first and second premolars, the adjacent gingiva, and the maxillary sinus. The middle superior alveolar nerve is not always present. If it is not present, innervation to that area is provided by the anterior and posterior superior alveolar nerves (see **Figure 19–5**).
2. The **anterior superior alveolar (ASA) nerve** supplies the maxillary incisor and canine teeth and associated labial gingiva. It also innervates the maxillary sinus (see **Figure 19–5**).

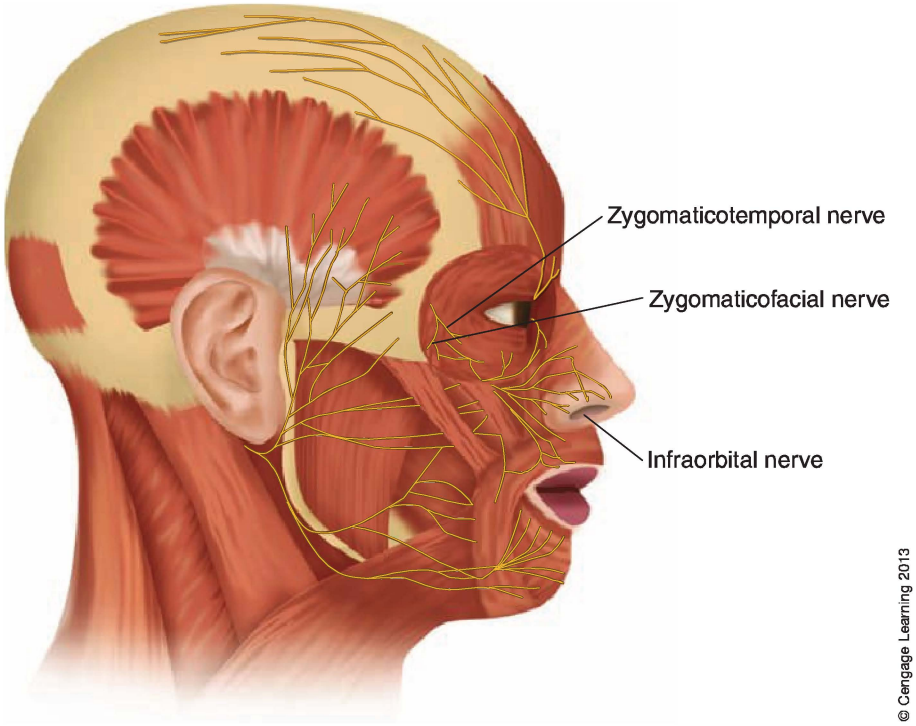

Figure 19–4. Branches of the zygomatic and infraorbital nerves.

After the infraorbital nerve emerges onto the face through the infraorbital foramen, it divides into the following three terminal branches:

1. *Palpebral*—supplies the skin of the lower eyelid
2. *External nasal*—innervates the skin and mucosa of the side of the nose
3. *Superior labial*—supplies the skin and mucosa of the upper lid and labial mucosa

POSTERIOR SUPERIOR ALVEOLAR (PSA) NERVE

Before the infraorbital nerve enters the intraorbital groove, it gives off the **posterior superior alveolar (PSA) nerve** (see **Figure 19–5**). This nerve crosses the maxillary tuberosity and supplies the maxillary molar teeth, with the exception of the mesiobuccal root of the maxillary first molar, which is innervated by the middle superior alveolar nerve (MSA). The adjacent buccal gingiva and maxillary sinus are also supplied by the posterior superior alveolar nerves.

PTERYGOPALATINE NERVES

Five branches of the maxillary nerve are given off in the pterygopalatine fossa (**Figure 19–6**).

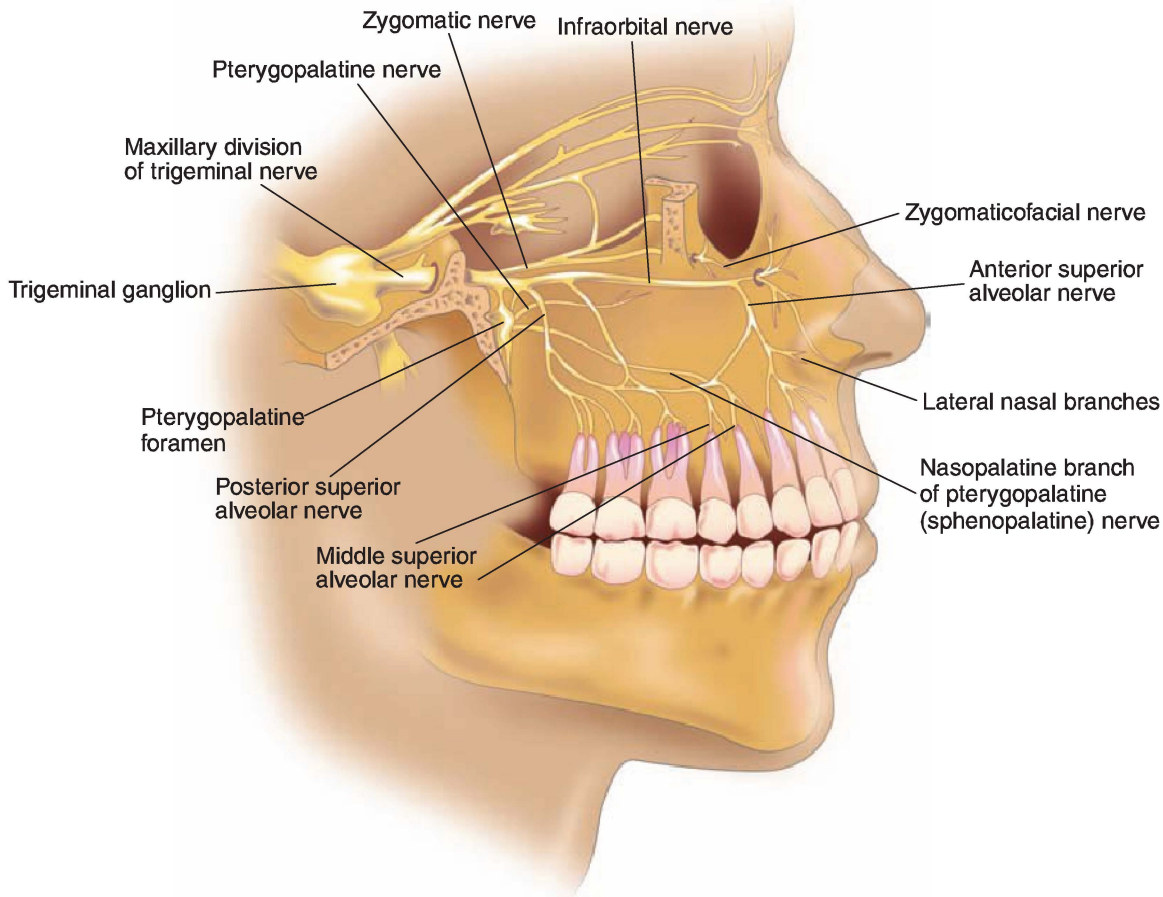

Figure 19–5. Branches of the maxillary nerve.

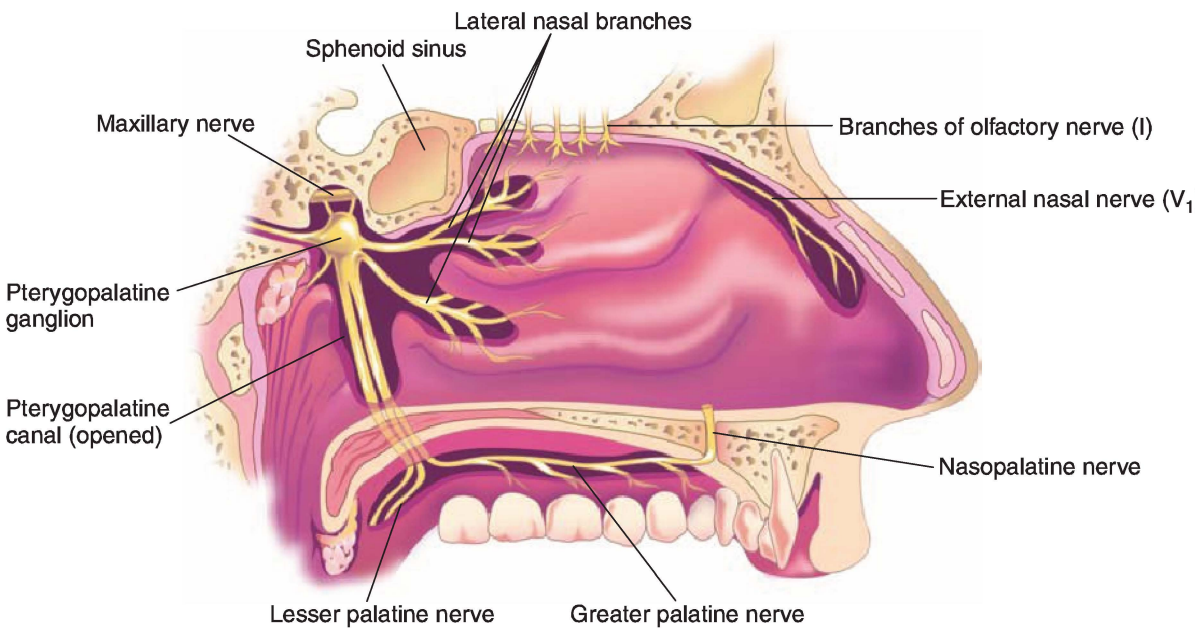

Figure 19–6. Pterygopalatine nerves.

1. *Pharyngeal*—supplies the pharynx and pharyngeal mucosa
2. *Greater palatine*—enters the greater palatine foramen (palatine bone) to supply the mucosa of the hard palate and lingual gingiva of the maxillary molars, premolars, and canine teeth
3. *Lesser palatine*—enters the lesser palatine foramen to supply the mucosa of the soft palate and tonsils
4. *Nasopalatine*—passes through the nasopalatine (incisive) foramen of the maxilla to supply the lingual gingiva of the maxillary incisor teeth
5. *Posterior superior lateral nasal*—supplies the middle and superior nasal conchae and the superior nasal septum

The Mandibular Nerve (V_3)

The mandibular nerve is the largest division of the trigeminal nerve and exits the skull through the *foramen ovale* in the sphenoid bone. It is both afferent and efferent.

After the foramen ovale, the sensory and motor roots of the mandibular nerve unite in a short trunk. The sensory branch gives off the *meningeal nerve*, which passes through the foramen spinosum to supply the meninges. The motor branch distributes nerves to the following muscles: *medial pterygoid*, *tensor tympani*, and *tensor veli palatini*. The mandibular nerve then branches into anterior and posterior divisions (**Figure 19–7**).

THE ANTERIOR DIVISION

This division has only one sensory branch; the remaining nerves are all motor to the muscles of mastication.

Sensory

The *buccal (long buccal) nerve* is the only sensory nerve in the anterior division. It crosses between the two heads of the lateral pterygoid muscle and emerges through the buccinator muscle. It innervates the buccal gingiva of the mandibular molars and premolars, the mucosa of the cheek, and the skin of the cheek.

Motor

- *Masseteric nerve*—supplies the masseter muscle
- *Anterior and posterior deep temporal nerves*—supply the temporalis muscle
- *Lateral pterygoid nerve*—supplies the lateral pterygoid muscle

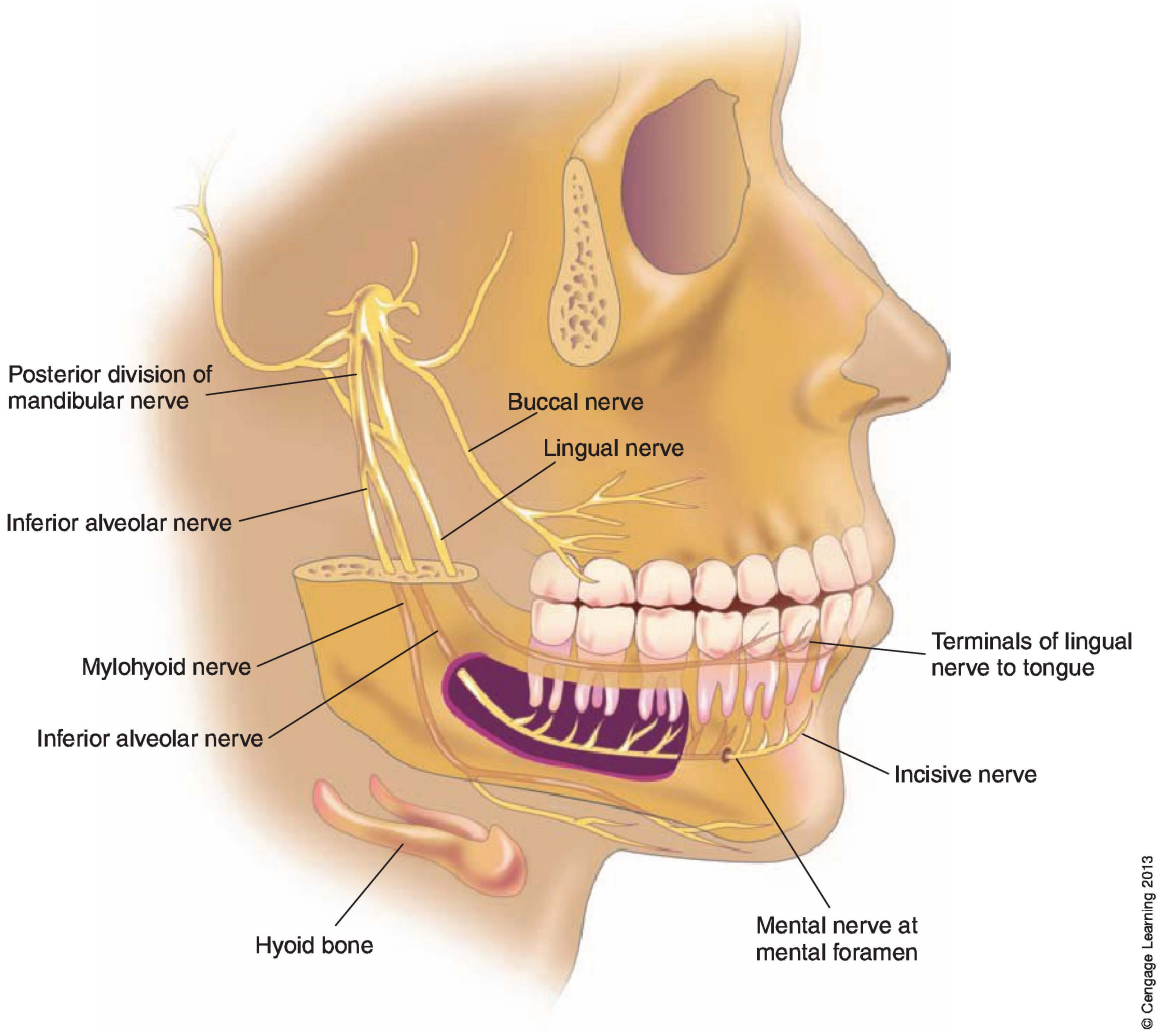

Figure 19–7. Anterior view of the mandibular nerve.

THE POSTERIOR DIVISION

This division has only one motor branch; the remaining branches are all sensory.

The *auriculotemporal nerve* supplies the skin of the temporal region in front of the ear, the external acoustic (auditory) meatus, and the temporomandibular joint. After giving off the auriculotemporal nerve, the mandibular nerve divides into two terminal branches.

The **lingual nerve** runs between the medial pterygoid muscle and the mandible. It is joined by the *chorda tympani*, a branch of the facial nerve (VII). Together the lingual and chorda tympani nerves enter the posterior aspect of the mouth and run forward. The *chorda tympani* supplies taste

sensation to the anterior two-thirds of the tongue. The lingual nerve enters the floor of the mouth and ventral surface of the tongue. It supplies afferent innervation to the tongue, floor of the mouth, and lingual gingiva of the entire mandibular arch (**Figure 19–8**).

INFERIOR ALVEOLAR NERVE

The **inferior alveolar nerve** runs parallel with the lingual nerve. It then enters the mandible through the mandibular foramen and continues in the mandibular canal. Before it enters the mandibular foramen, it gives off the *mylohyoid nerve*, the only motor branch in the posterior division. It supplies efferent sensation to the mylohyoid muscle and the anterior belly of the digastric muscle. After giving off the mylohyoid nerve, the inferior alveolar nerve is entirely sensory.

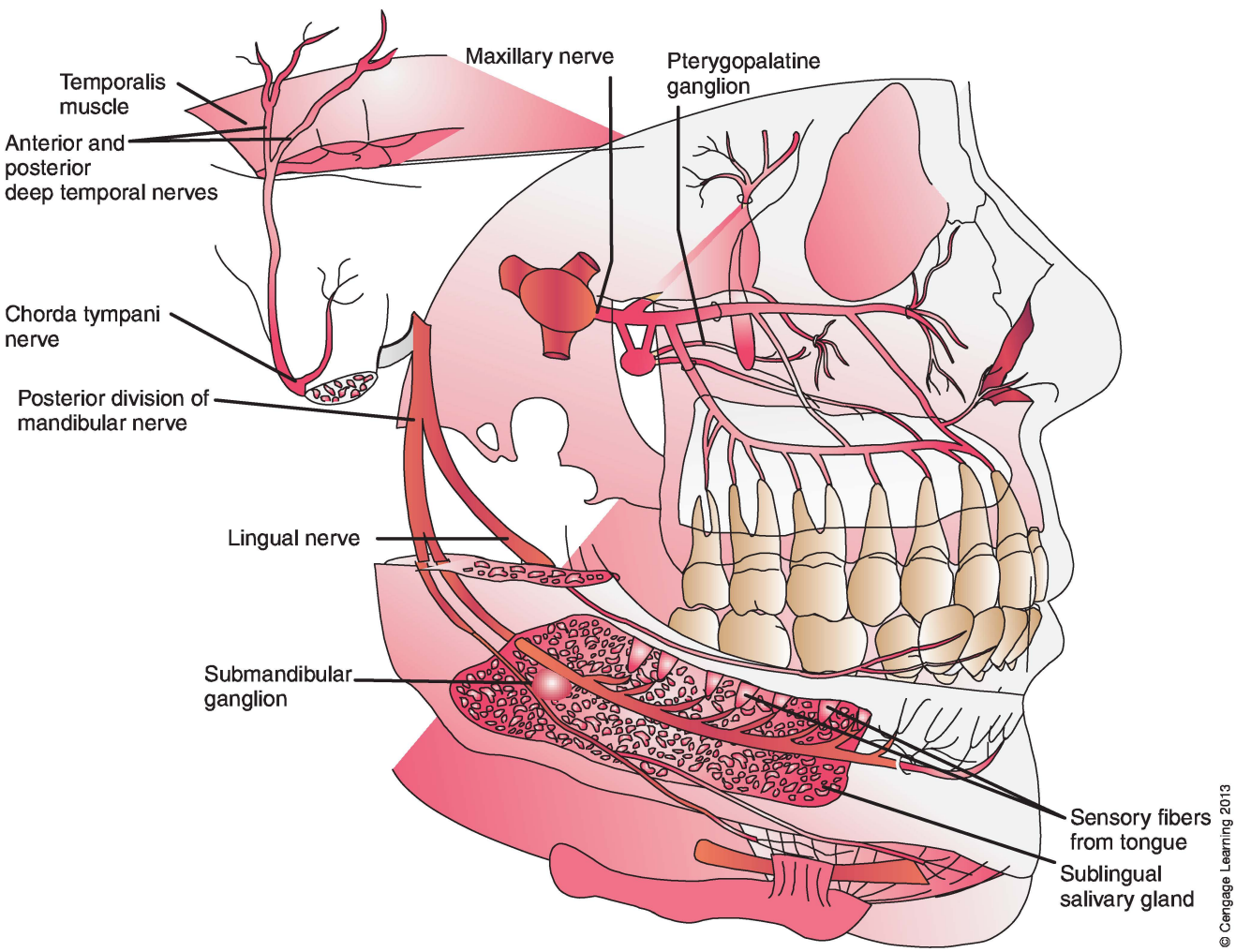

Figure 19–8. Branches of the facial nerve.

Within the mandibular canal, the inferior alveolar nerve gives off branches to the mandibular molars and premolars. At the *mental foramen*, it divides into the following nerves:

- *Mental nerve*, which supplies the chin and lower lip
- *Incisive nerve*, which supplies the mandibular anterior teeth and labial gingiva

Innervation for all the teeth appears in **Table 19–2**.

TABLE 19–2. Innervation of the Teeth and Tissues

NERVE	TEETH	TISSUES
Maxillary Arch		
Anterior superior alveolar	Centrals, laterals, canines	Facial gingiva and PDL of anterior teeth
Middle superior alveolar	First and second premolars Mesiobuccal root of first molar	Facial gingiva and PDL of premolar area
Posterior superior alveolar	First molar—distobuccal and lingual roots Second molar—all roots Third molar—all roots	Facial gingiva and PDL of molar area
Nasopalatine		Anterior palatal mucosa tissues Palatal mucoperiosteum from lateral incisor to lateral incisor
Greater palatine		Molar and premolar palatal mucosal tissues Palatal mucoperiosteum from posterior of molars to canine teeth
Mandibular Arch		
Inferior alveolar (the lingual nerve is usually involved)	All mandibular posterior teeth—premolars and molars	Labial mucosa around lower lip Anterior two-thirds of the tongue (lingual nerve) Floor of the mouth (lingual) Lingual mucosa of all teeth (lingual)
Incisive	Anterior teeth	Chin and lower lip anterior of mental foramen
Mental		Chin and lower lip anterior of mental foramen

continues

TABLE 19–2. Innervation of the Teeth and Tissues *continued*

NERVE	TEETH	TISSUES
Buccal		Buccal mucous membrane of the cheek and gingiva of premolars and molars
Lingual		Lingual mucosa of all teeth Anterior two-thirds surface of tongue Floor of the mouth

© Cengage Learning 2013

THE FACIAL NERVE (VII)

The **facial nerve** is both afferent and efferent. It provides molar innervation to all the muscles of facial expression, posterior belly of the digastric muscle, stylohyoid, and stapedius muscle of the middle ear. It also provides taste sensation to the anterior two-thirds of the tongue and sensory innervation to the nose and salivary glands.

This nerve enters the internal acoustic meatus and travels through the temporal bone. The facial nerve encounters its sensory ganglion, the *geniculate ganglion*, in the temporal bone. While in the temporal bone, the facial nerve gives off the following branches:

- *Greater petrosal nerve*—supplies efferent innervation to glands of the nose and mouth and the lacrimal gland (see **Figure 19–8**)
- *Nerve to the stapedius muscle*—supplies the stapedius muscle of the inner ear
- *Chorda tympani nerve*—joins with the lingual nerve and carries taste fibers to the anterior two-thirds of the tongue (**Figure 19–8**)

The facial nerve then exits the skull through the stylomastoid foramen and gives off the following branches:

- *Posterior auricular nerve*—supplies the posterior auricular and occipital muscles
- *Digastric nerve*—provides innervation to the posterior belly of the digastric muscle
- *Stylohyoid nerve*—innervates the stylohyoid muscle

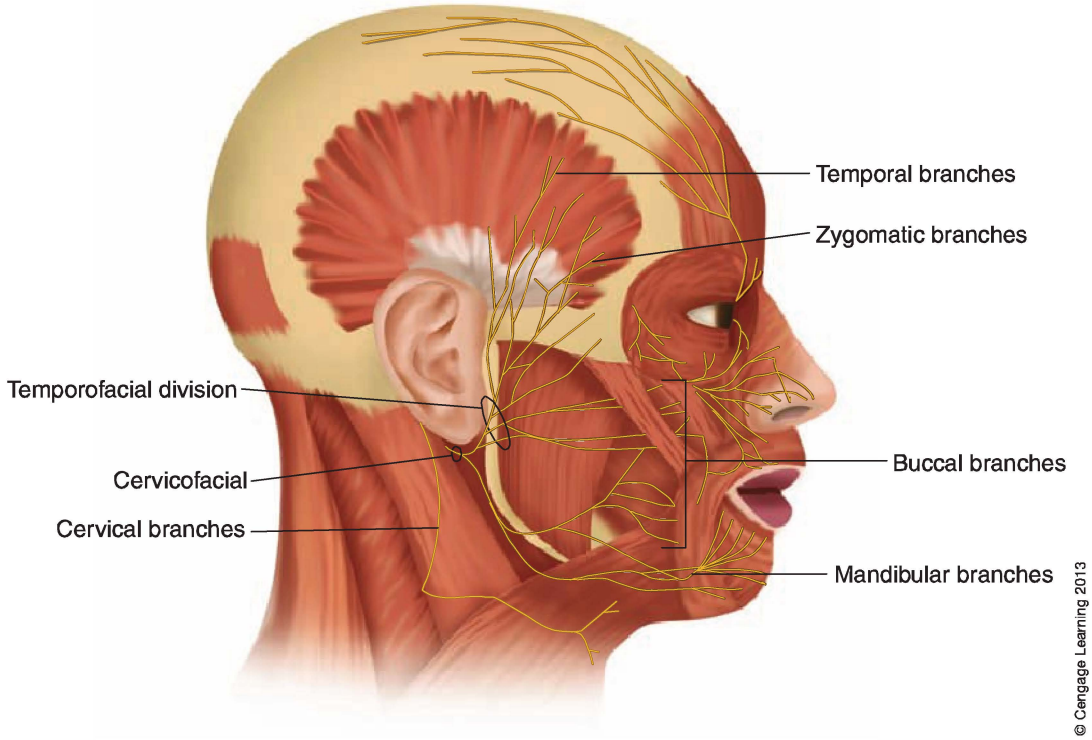

Figure 19–9. Temporofacial and cerviofacial divisions of the facial nerve.

The facial nerve then enters the parotid gland. It bifurcates into two divisions, a superior temporofacial and an inferior cervicofacial (**Figure 19–9**).

The temporofacial division gives rise to the following:

- *Temporal branches*—supply the anterior and superior auricular muscles, frontal muscle, corrugator muscle of the eyebrow, and the orbicularis oculi
- *Zygomatic branches*—also provide innervation to the orbicularis oculi
- *Buccal branches*—supply procerus, zygomatic, quadratus labii superioris, nasalis, buccinator, orbicularis oris, and risorius muscles

The *cervicofacial trunk* gives rise to the following:

- *Mandibular branch*—provides innervation to the muscles of the lower lip and chin
- *Cervical branch*—supplies the platysma muscle

THE GLOSSOPHARYNGEAL NERVE (IX)

The **glossopharyngeal nerve** is both afferent and efferent, and it exits the skull through the jugular foramen. Its branches are distributed to the tongue and pharynx. The branches of the glossopharyngeal nerve include the following:

- *Tympanic nerve*—provides parasympathetic innervation to the parotid gland and sensory innervation to the middle ear
- *Carotid sinus nerve*—supplies afferent innervation to the carotid sinus for its blood pressure regulators
- *Stylopharyngeal nerve*—supplies motor innervation to the stylopharyngeal muscle
- *Pharyngeal branches*—join with the spinal accessory (XI) and vagus (X) nerves to create the *pharyngeal plexus*. The plexus supplies the muscle of the soft palate and pharynx, except for the stylopharyngeal supplied by IX and the tensor veli palatini innervated by V. It also innervates the mucosa of the soft palate, pharynx, and tonsils. The glossopharyngeal nerve also supplies the posterior one-third of the tongue with taste sensation.

THE HYPOGLOSSAL NERVE (XII)

The **hypoglossal nerve** is the *motor supply of the tongue*. It exits the skull through the hypoglossal canal and is entirely efferent. It enters the mouth to supply the geniohyoid muscle and the intrinsic and extrinsic muscles of the tongue—with the exception of the palatoglossal muscle, which is innervated by the pharyngeal plexus. Damage to this nerve causes paralysis of the tongue. The tongue will deviate toward the affected side when protruded.

SUMMARY

The peripheral nervous system is comprised of the nerves that travel *away from* the central nervous system; it *connects* all parts of the body with the central nervous system. There are 12 pairs of cranial nerves and 31 pairs of spinal nerves in the peripheral nervous system.

The cranial nerves provide innervation to the right and left side of the body, and they are usually designated by Roman numerals. The major cranial nerves include (1) the *trigeminal nerve*, which innervates the face, scalp, teeth, nose, mouth, and muscles of mastication and includes three branches—the ophthalmic nerve, the maxillary nerve, and the mandibular nerve; (2) the *facial nerve*, which innervates the muscles of facial expression provides taste to anterior two-thirds of tongue, provides sensory innervation to the tongue, nose, and salivary glands, and divides into eight branches—greater petrosal, nerve to stapedius muscle, chorda tympani, posterior auricular, digastric, stylohyoid, temporofacial, and cervicofacial; (3) the *glossopharyngeal nerve*, which supplies the posterior third of the tongue with taste and includes four branches—the tympanic, carotid sinus, stylopharyngeal, and pharyngeal; and (4) the *hypoglossal nerve*, which innervates the geniohyoid and the intrinsic and extrinsic muscles of the tongue.

Define the following terms

sympathetic
parasympathetic
afferent
efferent

Complete the following chart

Nerve	Sensory (S) Motor (N) Both (B)	Exit Site	Site
Trigeminal			
Ophthalmic (V_1)			
Maxillary (V_2)			
Mandibular (V_3)			
Facial			
Glossopharyngeal			
Hypoglossal			

Describe the path a pain impulse travels from the foramen rotundum to the maxillary right first molar

Label the following figure of cranial nerve V

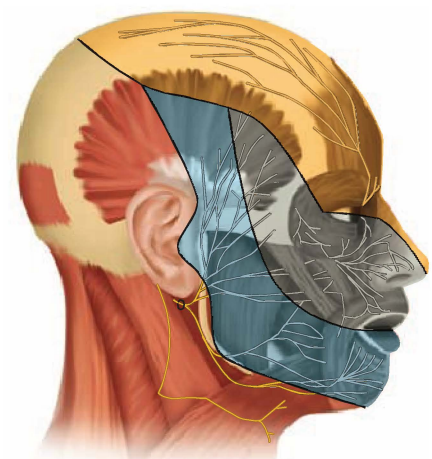

© Cengage Learning 2013

Answer the following multiple-choice questions

1. Following an injection, a portion of the tongue becomes numb. Which nerve was anesthetized?
   - **a.** posterior superior alveolar
   - **b.** middle superior alveolar
   - **c.** lingual
   - **d.** chorda tympani
   - **e.** incisive
2. The muscles of mastication are innervated by what cranial nerve?
   - **a.** V
   - **b.** VII
   - **c.** IX
   - **d.** X
   - **e.** V and VII
3. The maxillary division of the trigeminal nerve exits the skull through what bod part?
   - **a.** foramen ovale
   - **b.** superior orbital fissure
   - **c.** mandibular foramen
   - **d.** foramen rotundum
   - **e.** mental foramen
4. Which nerve supplies taste sensation to the posterior one-third of the tongue?
   - **a.** V
   - **b.** VII
   - **c.** IX
   - **d.** XI
   - **e.** XII
5. What nerve innervates the anterior mucosa of the hard palate?
   - **a.** posterior superior alveolar
   - **b.** middle superior alveolar
   - **c.** infraorbital
   - **d.** nasopalatine
   - **e.** incisive

CHAPTER 20

Arteries of the Head and Neck

- General Information
- Internal Carotid Artery
- External Carotid Artery
- Veins of the Face

Objectives

At the completion of this chapter, you will be able to:

- Identify the eight branches of the external carotid artery.
- Describe the structures supplied by the eight branches of the external carotid artery.
- Describe the structures supplied by the internal carotid artery.
- Describe the blood supply to the maxillary and mandibular teeth.
- Describe the structures drained by the superficial and deep veins.
- Complete the worksheet at the end of the chapter.

KEY TERMS

Arch of the aorta

Artery

Ascending pharyngeal artery

continues

Key Terms *continued*

Brachiocephalic artery
Common carotid artery
External carotid artery
Facial artery
Internal carotid artery
Internal jugular vein
Lingual artery
Maxillary artery
Occipital artery
Posterior auricular artery
Pterygoid plexus of veins
Superficial temporal artery
Superior thyroid artery
Vein

GENERAL INFORMATION

The head and neck are supplied almost entirely by the *common carotid arteries*. **Arteries** are tubes that carry oxygenated blood away from the heart. They expand and contract with the pumping beat of the heart. On the left side, the common carotid ascends from the **arch of the aorta**. On the right side, it arises from the **brachiocephalic artery**. The **common carotid arteries** are found on the lateral sides of the neck beneath the sternocleidomastoid muscle (**Figure 20–1**). At the thyroid cartilage, the common carotid artery bifurcates into the **internal and external carotid arteries** (**Figure 20–2**).

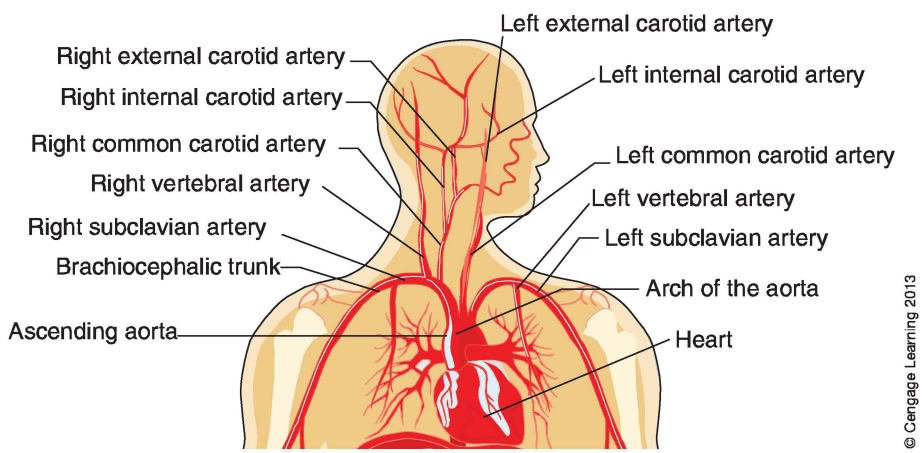

Figure 20–1. Origin of the cartoid and vertebral arteries.

INTERNAL CAROTID ARTERY

This artery does not supply the mouth. It enters the skull through the carotid canal and supplies the brain and eyes. There are no branches present in the neck (see **Figure 20–2**).

EXTERNAL CAROTID ARTERY

This artery ascends in the neck to the angle of the mandible. It ends as it is crossed by the posterior belly of the digastric and stylohyoid muscles. Its branches cross the face and scalp. The external carotid has eight branches (see **Figure 20–2**).

1. **Ascending pharyngeal artery**: This artery arises just above the bifurcation of the common carotid artery. It travels on the side of the pharynx on its way to the skull. It supplies the pharynx and its muscles.
2. **Superior thyroid artery**: This artery also arises from the bifurcation of the common carotid artery. It supplies the thyroid gland and associated muscles.
3. **Lingual artery**: The lingual artery arises at the level of the hyoid bone. It passes deep to the hyoglossus muscle and enters the base of the tongue. The lingual artery ends at the tip of the tongue. It has three branches.
   a. *Sublingual artery*—supplies the floor of the mouth, sublingual gland, mylohyoid muscle, and lingual gingiva
   b. *Dorsal lingual artery*—supplies the back of the tongue, tonsils, soft palate, and epiglottis
   c. *Deep lingual artery*—supplies the tip of the tongue along its inferior surface (**Figure 20–3**)
4. **Facial artery**: This arises just below the angle of the mandible. It passes close to the posterior belly of the digastric and stylohyoid muscles, and enters the submandibular gland. It travels lateral to the inferior border of the mandible, and then it turns and passes in front of the masseter muscle. After crossing the

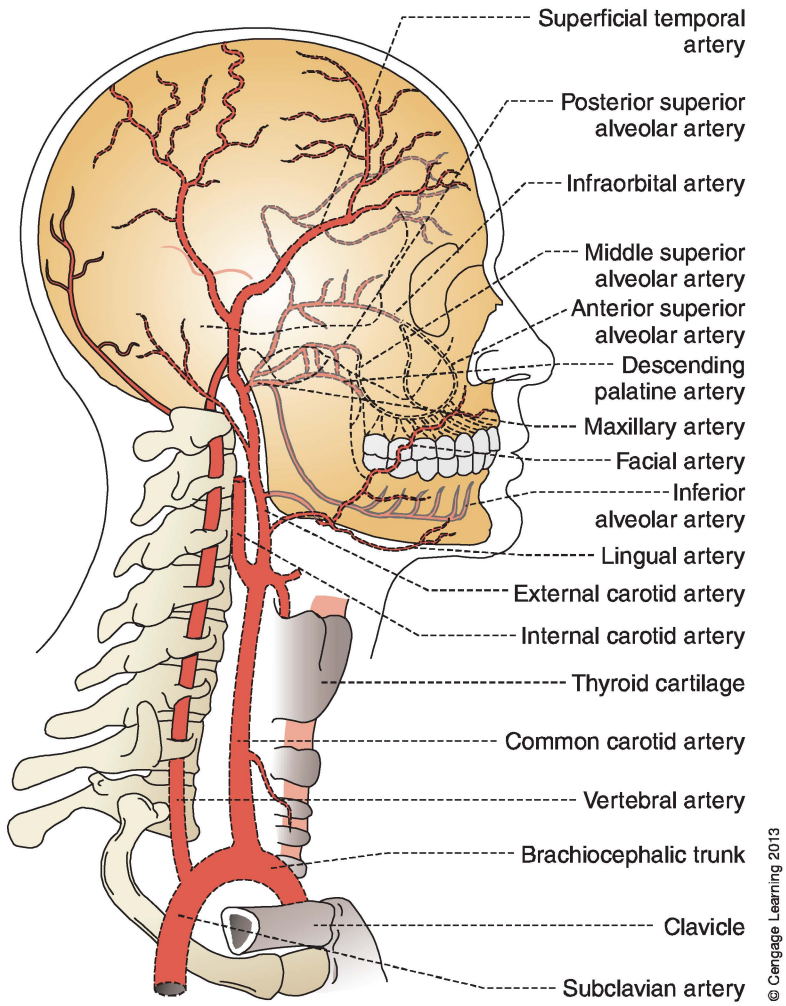

Figure 20–2. Course of the right common cartiod artery.

mandible, it travels obliquely across the face to the eye. It gives off six branches:

a. *Ascending palatine artery*—supplies the soft palate, pharynx, pharyngeal muscles, and the tonsils. It arises at the beginning of the facial artery.

b. *Submental artery*—arises below the mandible and runs toward the chin. It supplies the sublingual and submandibular glands, mylohyoid muscle, and the anterior belly of the digastric muscle (**Figure 20–4**).

c. *Inferior labial artery*—runs below the mouth, deep to the orbicularis oris, and supplies the lower lip and chin

d. *Superior labial artery*—runs above the mouth and supplies the upper lip. The inferior and superior labial arteries arise at the corners of the mouth (see **Figure 20–4**).

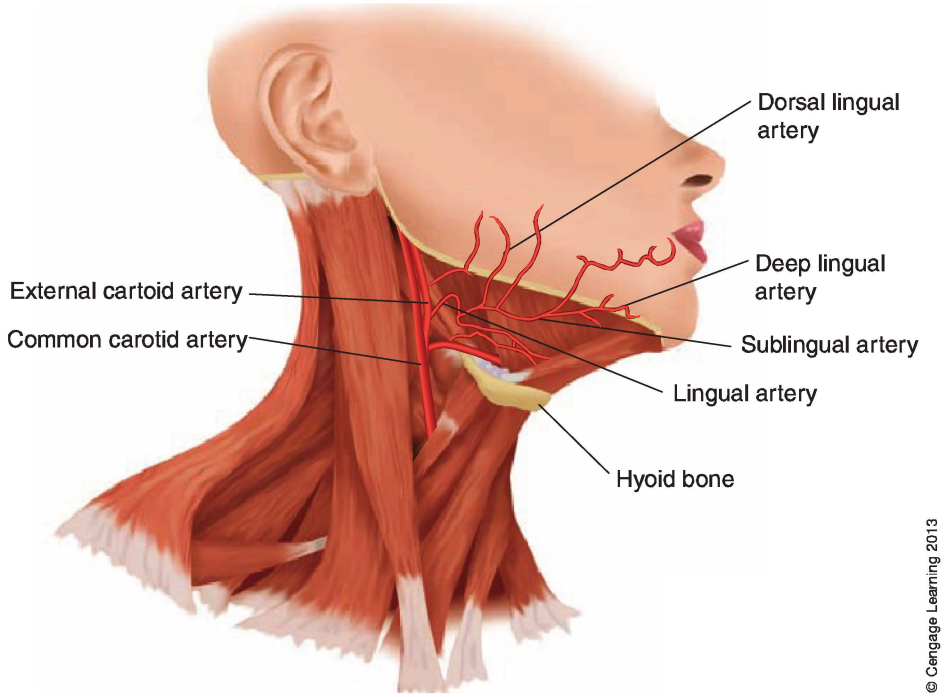

© Cengage Learning 2013

Figure 20–3. Branches of the lingual artery.

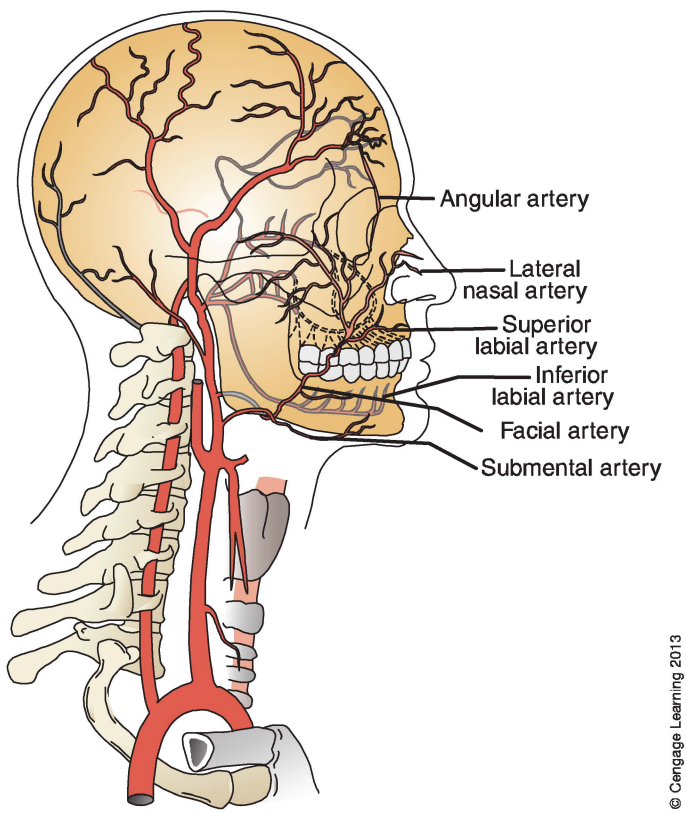

© Cengage Learning 2013

Figure 20–4. Branches of the facial artery.

e. *Lateral nasal artery*—runs along the side of the nose and supplies the skin and muscles of the nose
f. *Angular artery*—the terminal branch of the facial artery. It supplies the eyelids and skin of the nose (see **Figure 20–4**).

5. **Occipital artery**: This artery arises opposite the origin of the facial artery. It runs posteriorly toward the occipital area and supplies the scalp and associated muscles, the sternocleidomastoid, and the muscles of the neck.
6. **Posterior auricular artery**: The posterior auricular artery arises opposite the ear and travels behind the ear. It supplies the outer ear and associated scalp.
7. **Superficial temporal artery**: The superficial temporal artery and maxillary artery are the terminal branches of the external carotid artery. The superficial temporal artery travels through the parotid gland in front of the ear. Before the superficial artery emerges from the parotid gland, it gives off the *transverse facial artery*, which supplies the masseter muscle and parotid gland. *Auricular* branches travel to the ear, and a *middle temporal* branch supplies the temporalis muscle (**Figure 20–2**).
8. **Maxillary artery**: The maxillary artery is the larger of the two terminal branches of the external carotid. It arises from the external carotid artery at the neck of the mandible. It passes between the mandible and sphenomandibular ligament, close to the lateral pterygoid muscle, on its way to the pterygopalatine fossa. It supplies facial structures and is divided into three sections: *mandibular*, *pterygoid*, and *pterygopalatine* (**Figure 20–5**).

Mandibular Section

This section is located behind the neck of the mandible. There are five branches found here.

1. *Deep auricular artery*—supplies the temporomandibular joint, external acoustic meatus, and the tympanic membrane (**Figure 20–6**)
2. *Anterior tympanic artery*—supplies the inside of the tympanic membrane (see **Figure 20–6**)
3. *Inferior alveolar artery*—travels with the inferior alveolar nerve and enters the mandibular foramen. This artery supplies the mandibular molar and premolar teeth (see **Figure 20–6**).

Before the inferior alveolar artery enters the mandibular foramen, it gives off a branch, the *mylohyoid artery*, which travels in the

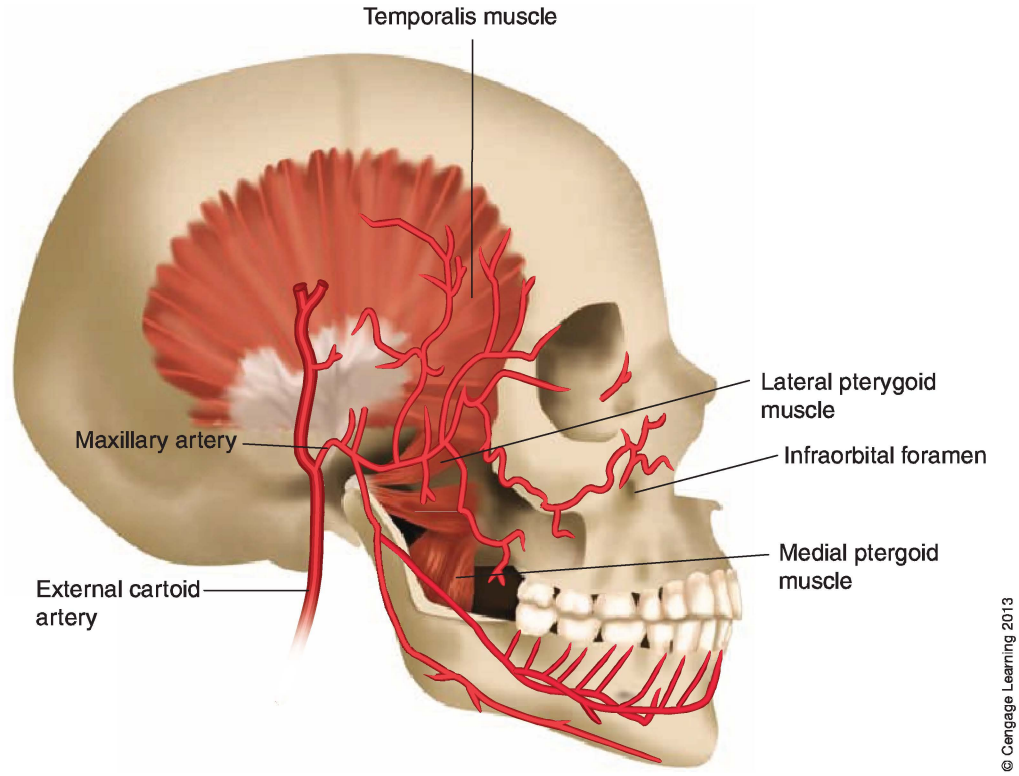

Figure 20–5. Three regions as the maxillary artery.

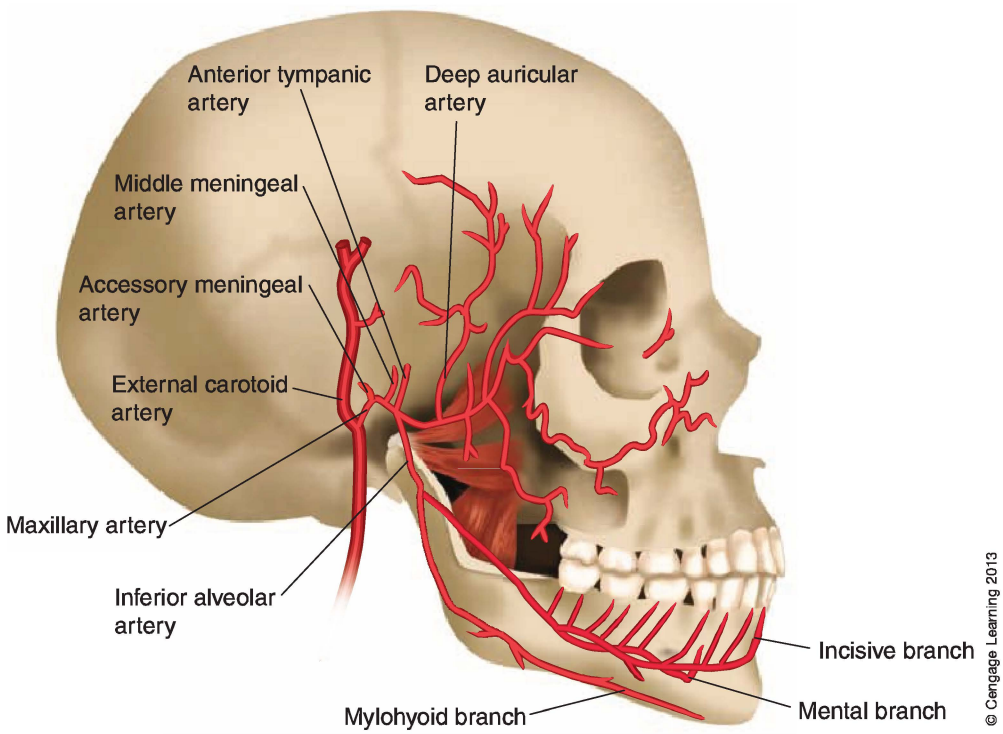

Figure 20–6. Branches of the mandibular section of the maxillary artery.

mylohyoid groove to supply the mylohyoid muscle. Also given off is a *lingual branch*, which aids in supplying the tongue. The inferior alveolar artery travels in the mandibular canal until it reaches the mental foramen, at which point it branches into the *mental artery* and *incisive artery*. The *mental artery* exits the mandibular canal through the mental foramen to supply the chin, while the *incisive artery* remains in the mandibular canal to supply the mandibular anterior teeth. Branches of the arteries enter the apical foramen to supply the pulp.

4. *Middle meningeal artery*—ascends between the lateral pterygoid muscle and the sphenomandibular ligament, and between the roots of the auriculotemporal nerve. It enters the cranium through the foramen spinosum to supply the dura mater and cranium (see **Figure 20–6**).
5. *Accessory meningeal artery*—travels through the foramen ovale to supply the dura mater and trigeminal ganglion (see **Figure 20–6**)

Pterygoid Section

This section is located in the infratemporal fossa (see **Figure 20–5**). It has six branches.

1. & 2. *Posterior and anterior deep temporal arteries*—supply the temporalis muscle
3. *Masseteric artery*—supplies the masseter muscle
4. & 5. *Medial and lateral pterygoid arteries*—supply the medial and lateral pterygoid muscles
6. *Buccal artery*—supplies the buccinator muscle and the cheek

Pterygopalatine Section

This section is located in the pterygopalatine fossa. The maxillary artery ends around the infraorbital area. There are six branches found here.

1. *Posterior superior alveolar artery*—travels across the maxilla with the posterior superior alveolar nerve. Branches supply the maxillary molar teeth, maxillary sinus, and associated gingiva (**Figure 20–7**).
2. *Infraorbital artery*—emerges onto the face through the infraorbital foramen. A *middle superior alveolar branch* supplies the maxillary premolar teeth. An *anterior superior branch* supplies the maxillary incisors and canine teeth. The lacrimal sacs and lower eyelids are supplied by the *palpebral branches*. *Labial branches* supply the upper lip, while *nasal branches* supply the nose (see **Figure 20–7**).

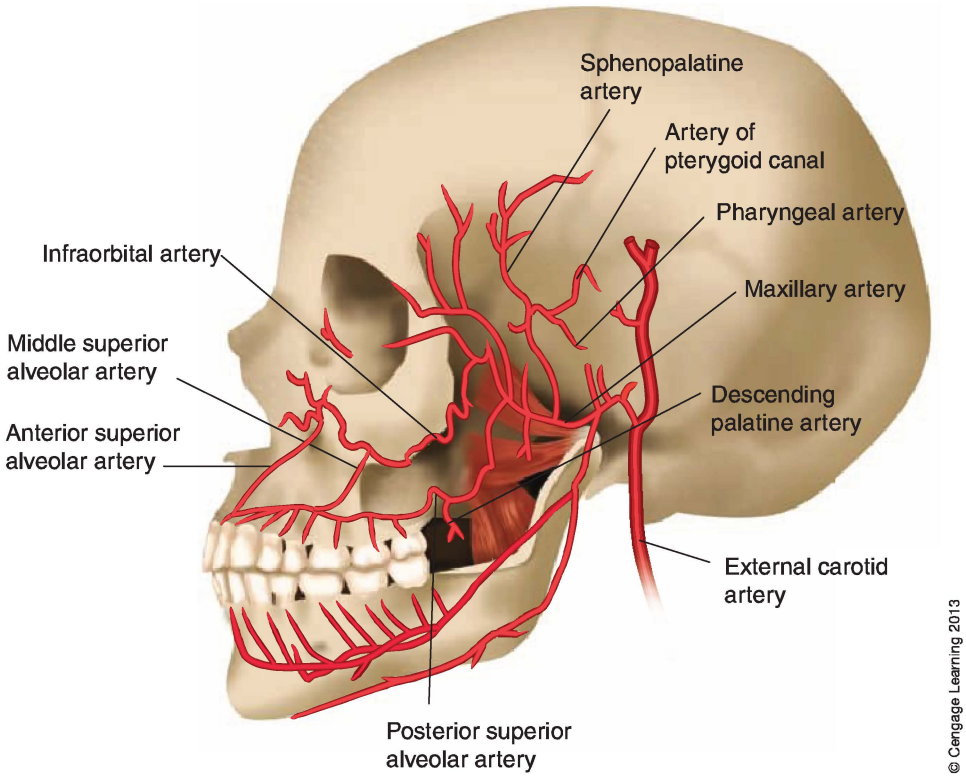

Figure 20–7. Branches of the pterygopalatine section of the maxillary artery.

3. *Greater palatine artery*—emerges from the greater palatine foramen to supply the gingiva, palatine glands, and the roof of the mouth. The *lesser palatine branch* emerges from the lesser palatine foramen to supply the tonsils and soft palate (**Figure 20–8**).
4. *Sphenopalatine artery*—exits through the sphenopalatine foramen and enters the nasal cavity. It supplies the lateral wall of the nasal cavity, nasal septum and nasal sinus.
5. *Nasopalatine artery*—travels to the incisive foramen and supplies the lingual gingiva of the maxillary anterior teeth

VEINS OF THE FACE

Veins return blood to the heart. Veins have valves that open in the direction of the flow of blood. The veins of the face usually travel with arteries and have similar names. Veins are commonly divided into a superficial and deep

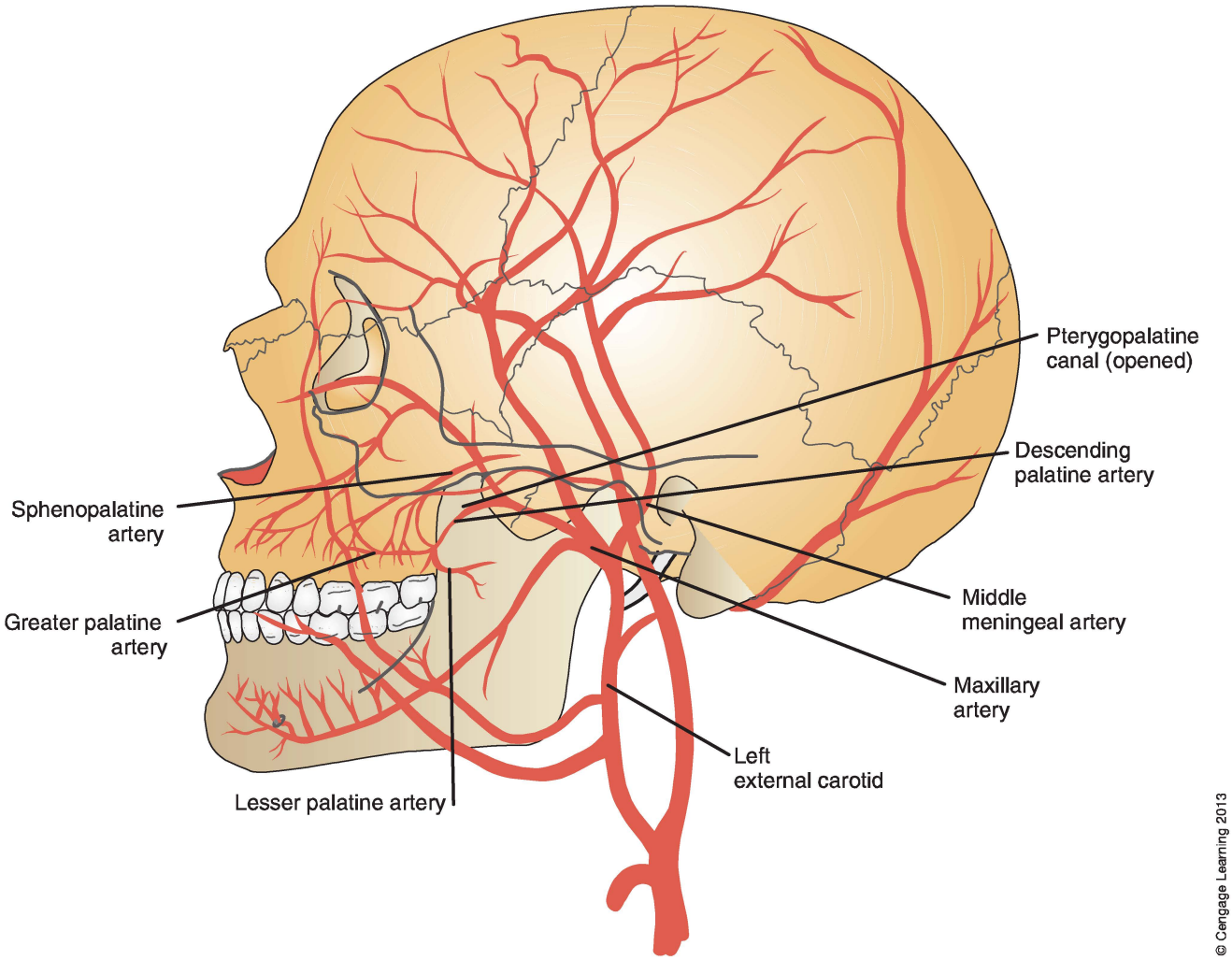

Figure 20–8. Greater palatine, lesser palatine, and sphenaopalatine arteries.

group. Variations in venous drainage are common. Facial veins do not have valves, so there is a potential danger of infection to the brain.

Superficial Veins

The *facial* and *superficial temporal* veins drain facial structures. The facial vein becomes the *angular* vein after it passes the upper lip. The facial vein has several branches from the nose, lips, eye, submental, and submandibular regions.

The *superficial temporal vein* joins the *maxillary* vein to form the *retromandibular* vein (see **Figure 20–8**). This vein drains the regions of the maxillary and superficial temporal arteries.

The *common facial* vein is the union of the facial and retromandibular veins. It then enters the **internal jugular vein** (**Figure 20–9**). The internal jugular vein empties into the *brachiocephalic* vein. The right and left *brachiocephalic* veins join and form the *superior vena cava*, which drains into the heart.

Deep Veins

The **pterygoid plexus of veins** is a collection of veins located between the temporalis and lateral pterygoid muscles and between the lateral and medial pterygoids. Structures that drain into the plexus include: muscles of mastication, buccinator, nose, palate, and the teeth. Injury to the pterygoid plexus during administration of local anesthesia can cause hematoma. The *maxillary* vein drains the pterygoid plexus (see **Figure 20–9**).

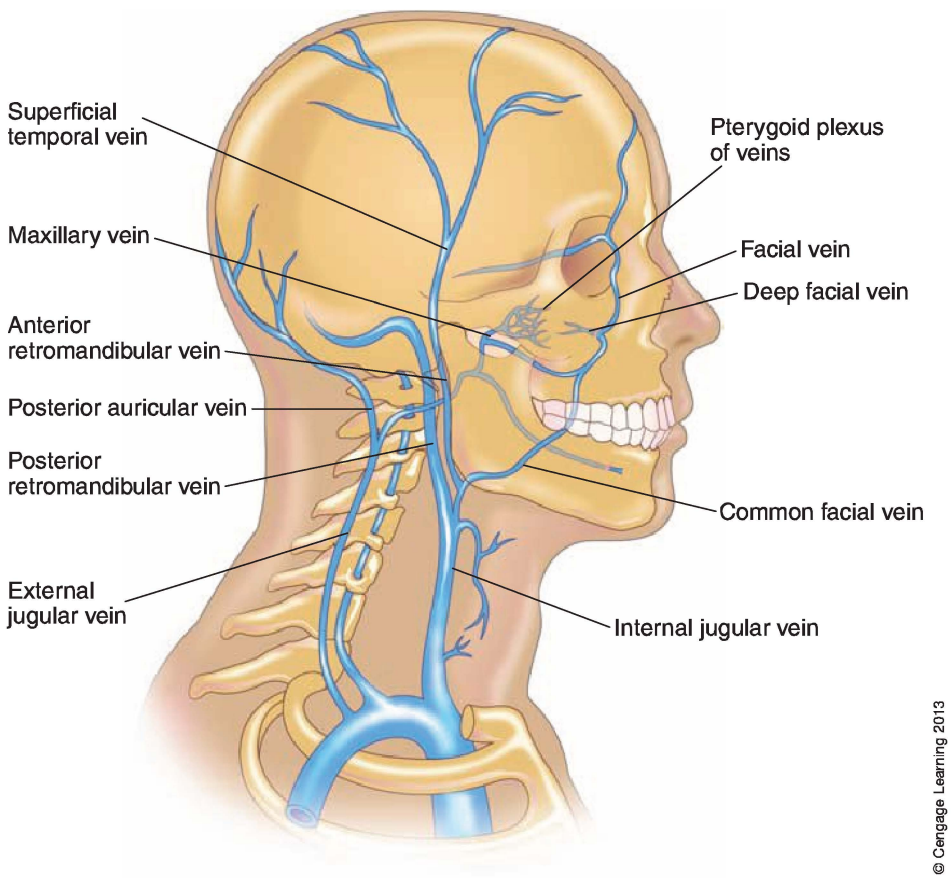

Figure 20–9. Internal and external jugular veins.

SUMMARY

The head and neck are supplied almost entirely by the common carotid arteries. These are divided into three groups in the head and neck: (1) the *internal carotid artery*, which supplies the brain and eye; (2) the *external carotid artery*, which supplies the mouth and head and includes eight branches—ascending pharyngeal, superior thyroid, lingual, facial, occipital, posterior auricular, superficial temporal, and maxillary; and (3) the *veins of the face*, which generally travel with the arteries and are divided into superficial and deep veins.

Label the following figures

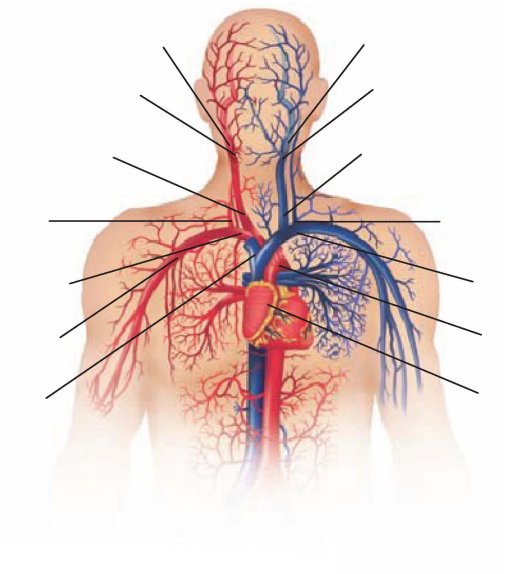

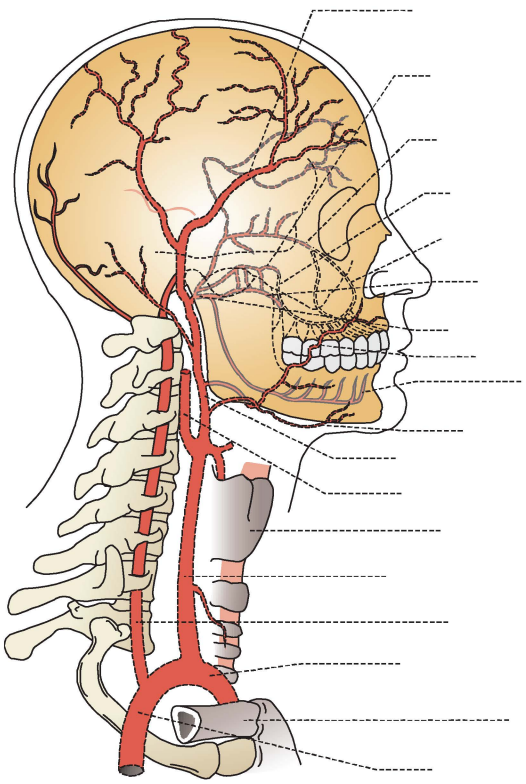

© Cengage Learning 2013

© Cengage Learning 2013

Answer the following multiple-choice questions

1. What artery supplies blood to the maxillary molars?
   - **a.** posterior superior alveolar
   - **b.** middle superior alveolar
   - **c.** anterior superior alveolar
   - **d.** inferior alveolar
   - **e.** incisive
2. What artery supplies the maxillary anterior teeth?
   - **a.** posterior superior alveolar
   - **b.** middle superior alveolar
   - **c.** anterior superior alveolar
   - **d.** inferior alveolar
   - **e.** incisive
3. What vein drains the majority of the head and face?
   - **a.** facial
   - **b.** superficial temporal
   - **c.** internal jugular
   - **d.** common facial
   - **e.** retromandibular
4. What carotid artery does NOT supply the mouth?
   - **a.** internal
   - **b.** external
5. What artery supplies tooth #19?
   - **a.** posterior superior alveolar
   - **b.** middle superior alveolar
   - **c.** anterior superior alveolar
   - **d.** inferior alveolar
   - **e.** incisive

CHAPTER 21

Salivary Glands

- General Information
- Major Salivary Glands
- Minor Salivary Glands

Objectives

At the completion of this chapter, you will be able to:

- Identify the major salivary glands on a picture or diagram.
- Identify the minor salivary glands on a picture or diagram.
- Identify the duct for each major salivary gland.
- Classify each of the major and minor salivary glands according to its secretion.
- Complete the worksheet at the end of the chapter.

Key Terms

Bartholin's duct
Buccal glands
Ducts of Rivinus
Labial glands
Lingual glands
Major salivary glands
Minor salivary glands
Mucous
Palatine glands
Parotid gland
Parotid papilla
Serous
Stensen's duct
Sublingual gland
Submandibular gland
Wharton's duct

GENERAL INFORMATION

In the oral cavity there are *major* and *minor* salivary glands. The three pairs of major salivary glands are the *parotid*, *submandibular*, and *sublingual*. Minor salivary glands may be located through the mouth.

MAJOR SALIVARY GLANDS

Parotid Gland

The **parotid gland** is the largest of the three **major salivary glands**. It is located on the side of the face, below and in front of the ear and behind the ramus. It terminates at the zygomatic arch in front of the ear and reaches down the masseter muscle. It extends inward to the pharyngeal wall. The duct for this gland is known as **Stensen's duct**, which crosses the masseter and buccinator muscles to enter the oral cavity opposite the maxillary second molar. Stensen's duct is covered by the **parotid papilla**, a small papilla extending from the cheek mucosa opposite the maxillary second molar (**Figure 21–1**).

The parotid gland is surrounded by a fibrous capsule. Several structures—such as the superficial temporal artery, the retromandibular vein, and the facial nerve—pierce the gland and travel within it. Saliva produced by the parotid gland is purely **serous**, a thin and watery secretion. The disease known as mumps is a viral infection of this gland.

Submandibular Gland

The **submandibular gland** is about the size of a walnut. It is located in the submandibular triangle, which is in front of and underneath the inferior border of the mandible (**Figures 21–1** and **Figure 21–2**). A small part extends to the mylohyoid muscle and lies deep to it. The remainder of the gland is located superficially to the mylohyoid muscle. The two divisions are connected. Its duct is known as **Wharton's duct**, which opens into the mouth at the sublingual caruncle.

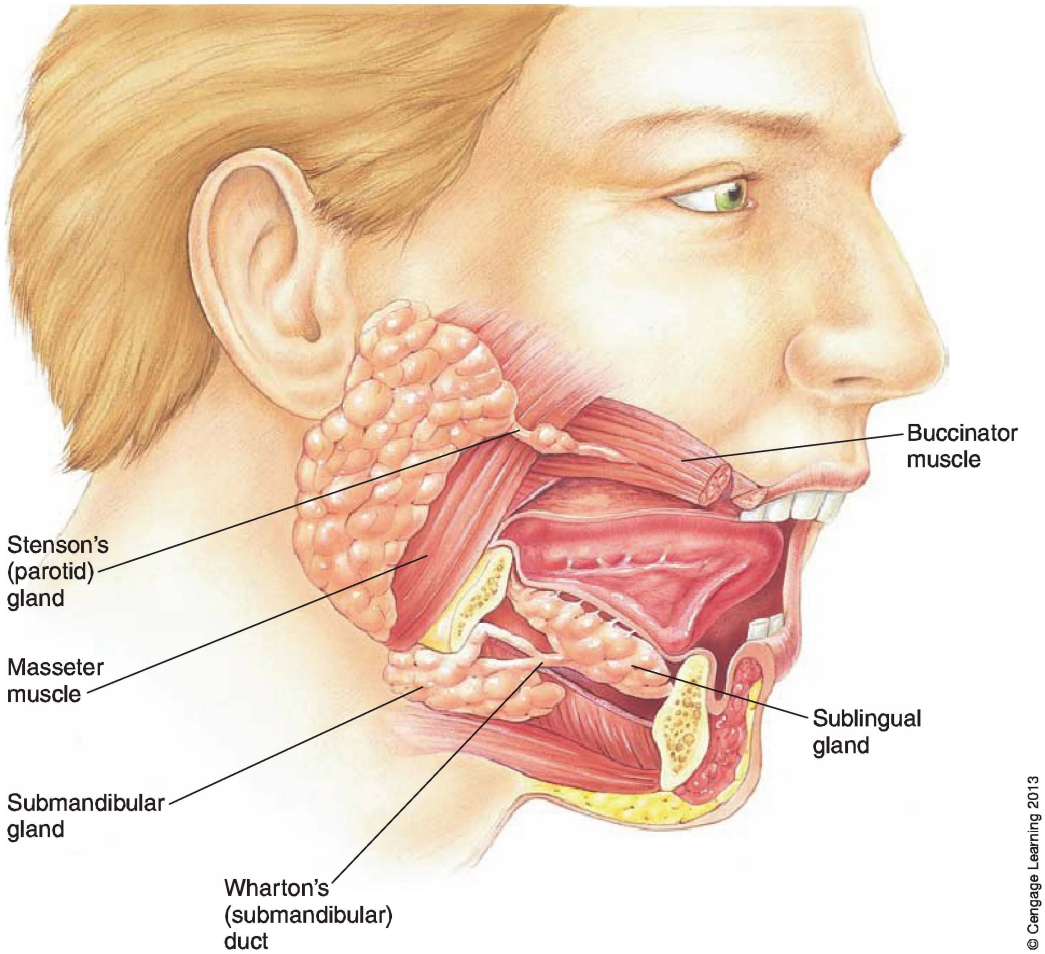

Figure 21–1. Locations and ducts of the major salivary glands.

A capsule encloses this gland. The facial artery is embedded in the submandibular gland. Saliva produced by this gland is mixed: 80% serous, 20% **mucous**. Mucous saliva secretion is thick and viscous.

Sublingual Gland

The **sublingual gland** is the smallest of the major salivary glands. It is located beneath the sublingual mucosa in the floor of the mouth. This gland rests on the mylohyoid muscle, and its projection forms the *sublingual fold* or *plica sublingualis* along the floor of the mouth. It has several small ducts, 8 to 20 in number, known as the **ducts of Rivinus**. These small ducts empty onto the sublingual fold. It has one major duct, **Bartholin's duct**, which opens along with Wharton's duct at the sublingual caruncle.

The sublingual gland is not encapsulated. It secretes a mixed saliva that is primarily a mucous secretion.

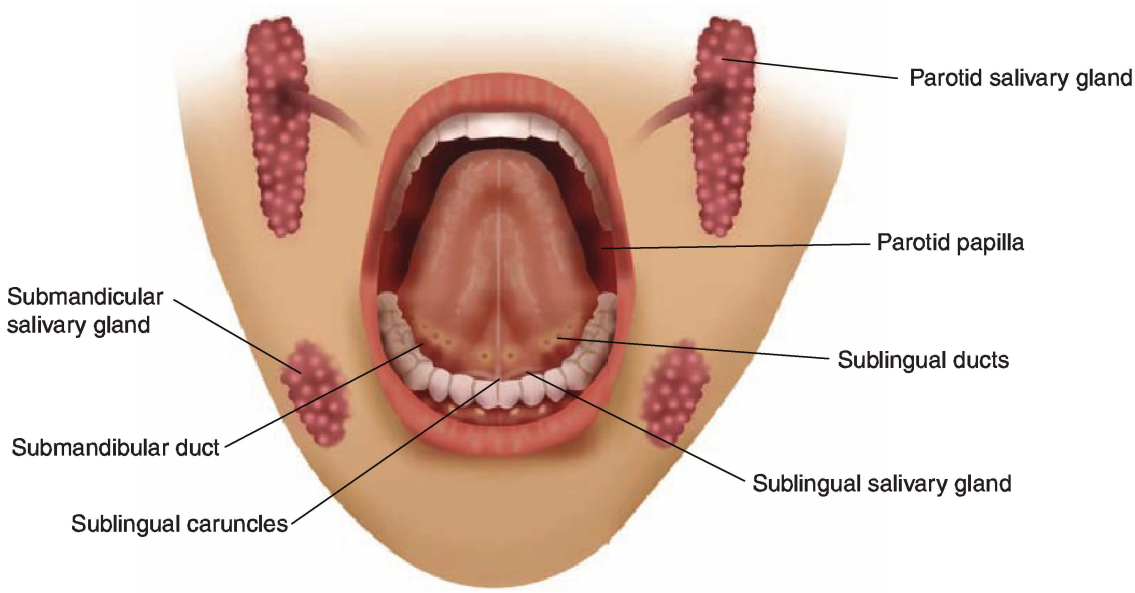

© Cengage Learning 2013

Figure 21–2. Major salivary glands and their ducts.

MINOR SALIVARY GLANDS

The **minor salivary glands** are small glands with short ducts that open directly into the mouth. Saliva secreted by these glands is usually mucous.

Labial Glands

The **labial glands** are found in the submucosa of the lips. They are numerous at the midline and have small ducts that open directly onto the lip mucosa. These are mixed glands, producing primarily mucous secretions.

Buccal Glands

The **buccal glands** are located in the cheek. They are very similar to the labial glands.

Palatine Glands

The **palatine glands** are found on the posterior third of the palate and on the soft palate. The opening of these ducts may be large and visible. They produce purely mucous secretions.

Lingual Glands

The **lingual glands** can be divided into three groups:

The *anterior lingual glands*, glands of the Blandin and Nuhn, are located at the apex of the tongue. The ducts empty onto the ventral surface of the tongue. They produce mainly mucous secretions. See **Figure 21–2**.

The *lingual glands of Von Ebner* are found beneath the circumvallate papillae. Their ducts open into the trough of the papillae. They produce purely serous secretions.

The *posterior lingual glands* can be found near the lingual tonsils on the posterior third of the tongue. They produce purely mucous secretions.

SUMMARY

The oral cavity is supplied by major and minor salivary glands. The major salivary glands include (1) the *parotid*, which is located in front of the ear and supplies the mouth with serous saliva; (2) the *submandibular*, which is located in front of and underneath the mandible and supplies the mouth with mixed saliva, primarily serous; and (3) the *sublingual*, which is located beneath the sublingual mucosa in the floor of the mouth and supplies the mouth with mixed saliva, primarily mucous.

The minor salivary glands include (1) the *labial*, which are located in the lip submucosa and supply the mouth with primarily mucous saliva; (2) the *buccal*, which is located in the buccal mucosa and supplies the mouth with primarily mucous saliva; (3) the *palatine*, which is located in the posterior third of the palate and the soft palate and supplies the mouth with purely mucous saliva; and (4) the *lingual*, which are divided into three groups—the anterior lingual glands (Blandin and Nuhn), the lingual glands of Von Ebner, and the posterior lingual glands.

WORKSHEET

Place a check under the correct response

Salivary Gland	Serous	Mucous	Mixed
Parotid			
Submandibular			
Sublingual			
Labial			
Buccal			
Palatine			
Anterior Lingual			
Lingual Glands of Von Ebner			
Posterior Lingual			

Answer the following multiple-choice questions

1. Stensen's duct is the opening for which salivary gland?

- **a.** sublingual
- **b.** submandibular
- **c.** parotid

2. Which major salivary gland secretes saliva that is primarily mucous?

- **a.** sublingual
- **b.** submandibular
- **c.** parotid

3. All the minor salivary glands have a mucous secretion except which gland?

- **a.** labial
- **b.** buccal
- **c.** palatine
- **d.** lingual gland of Von Ebner
- **e.** sublingual

4. What salivary gland has Wharton's duct as its opening?

a. sublingual

b. submandibular

c. parotid

5. Von Ebner's salivary glands open onto which papillae?

a. fungiform

b. filiform

c. foliate

d. circumvallate or vallate

CHAPTER 22

Temporomandibular Joint

Anatomy

Nerve and Blood Supply

Movement

Objectives

At the completion of this chapter, you will be able to:

- Describe and locate the following structures on a picture or diagram: condyle, mandibular fossa, articular eminence, articular disc, capsule, and retrodiscal pad.
- Describe the nerve and the blood supply to the temporomandibular joint (TMJ).
- Describe the two types of movement within the TMJ.
- Describe the clinical concerns associated with the TMJ.
- Complete the worksheet at the end of the chapter.

Key Terms

Arthritis
Articular disc (meniscus)
Articular eminence (tubercle)
Bruxism
Capsule
Crepitus
Joint
Mandibular (glenoid fossa)
Retrodiscal pad
Subluxation
Synovial fluid
Temporomandibular joint (TMJ)
TMJ disorder (TMD)

ANATOMY

A **joint** is a joining together of two bones. The **temporomandibular joint (TMJ)** is the articulation between the temporal bone and the mandible. It is bilateral, and movement of the right and left sides are interrelated and function as a single unit.

The osteology of the temporomandibular joint was studied in Chapter 17. The anatomy of this joint is depicted in **Figure 22–1** and **Figure 22–2**. The *condyle* of the mandible articulates with the **mandibular (glenoid) fossa** of the temporal bone. The specific location is the posterior slope of the **articular eminence (tubercle)** and the anterior portion of the mandibular (glenoid) fossa. The condyle does not fit into the center of the mandibular fossa but rests closer to the articular tubercle. The condyle and articular eminence do not actually touch; the **articular disc (meniscus)** rests between

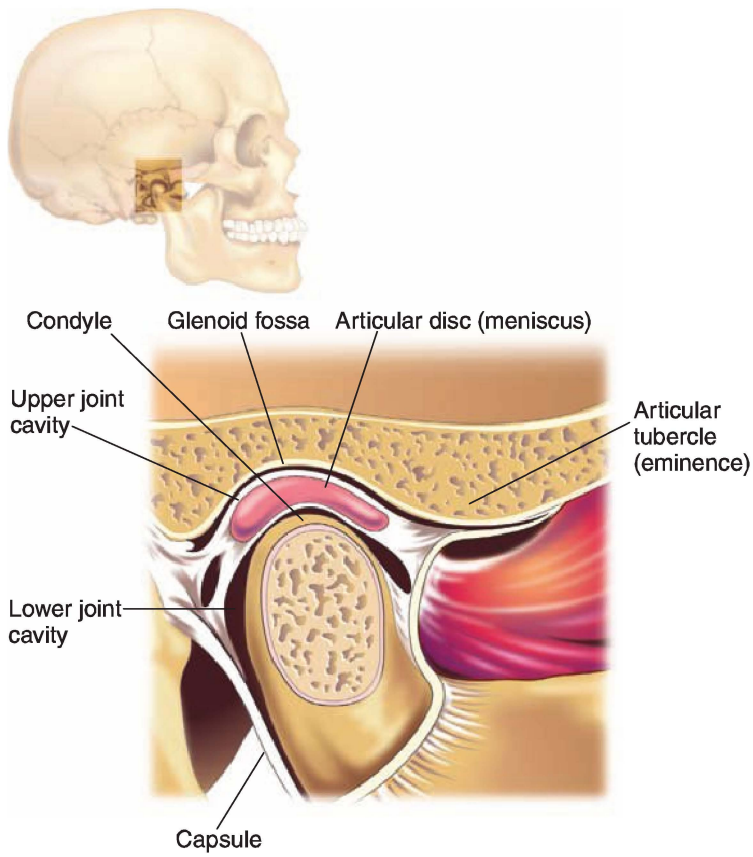

Figure 22–1. Temporomandibular joint.

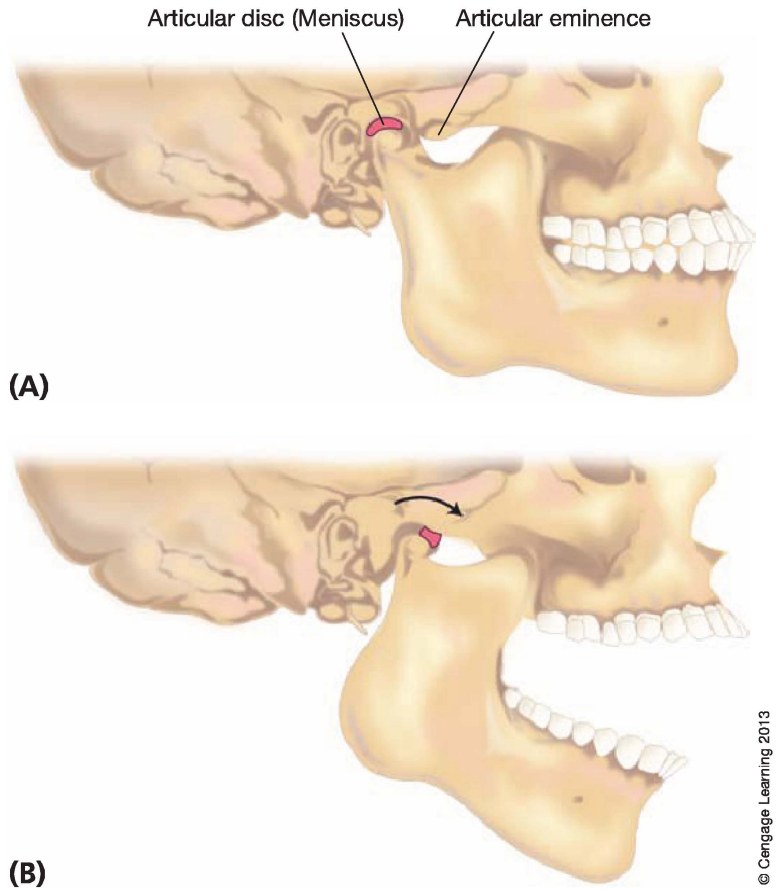

Figure 22–2. Movement of the TMJ (A) Hinge joint (B) Gliding joint movement.

them. This disc is a pad of dense fibrous connective tissue that is thickest at the posterior ends, thinnest in the middle, and thicker again at the anterior ends. The articular disc, in effect, separates the temporomandibular joint into upper and lower joint compartments. Laterally and medially, the disc is attached to the condyle itself, so that whenever the condyle glides forward and backward, the disc moves with it.

The condyle and articular eminence are covered by dense collagenous connective tissue, which contains no blood vessels or nerves. **Synovial fluid** bathes these structures, providing nourishment and lubrication that enables the bones to glide over each other without friction.

A thick fibrous **capsule** surrounds and encloses the entire joint. The disc and capsule are fused anteriorly, and some fibers of the lateral pterygoid muscle insert into the disc. Posteriorly, the disc and capsule are not directly attached but are connected by means of a **retrodiscal pad**, a pad of loose connective tissue that allows for anterior movement of the joint.

NERVE AND BLOOD SUPPLY

Innervation is supplied by two nerves, the auriculotemporal and masseteric nerves, which are branches of the mandibular nerve (V_3). Blood supply is provided by branches of the superficial temporal and maxillary arteries.

MOVEMENT

Movement within the temporomandibular joint is essentially of two types: *hinge* (swinging) motion and *gliding* movement.

The hinge motion occurs in the lower joint compartment between the disc and condyle as the mouth opens. As the condyles begin this motion, the disc moves anteriorly with the condyles, because they are attached. As the mouth continues to open, the hinge motion also continues; but now there is an anterior gliding movement as well that takes place in the upper joint compartment between the disc and the temporal bone. The lateral pterygoid muscle (which inserts into the disc) causes the forward movement, and the condyle and disc move anteriorly until they reach the articular tubercle (**Figure 22–3**).

Closing of the mouth is accomplished by the lateral pterygoid muscle, which controls the posterior movement of the disc as well as its own contraction.

Clinical Considerations

An *internal derangement* occurs when the disc becomes stuck or displaced. As the condyle rotates and translates forward down the slope of the articular eminence, the disc should stay interposed between these bones. If it becomes displaced or stuck, sounds of clicking, popping, or **crepitus** (crunching) may result.

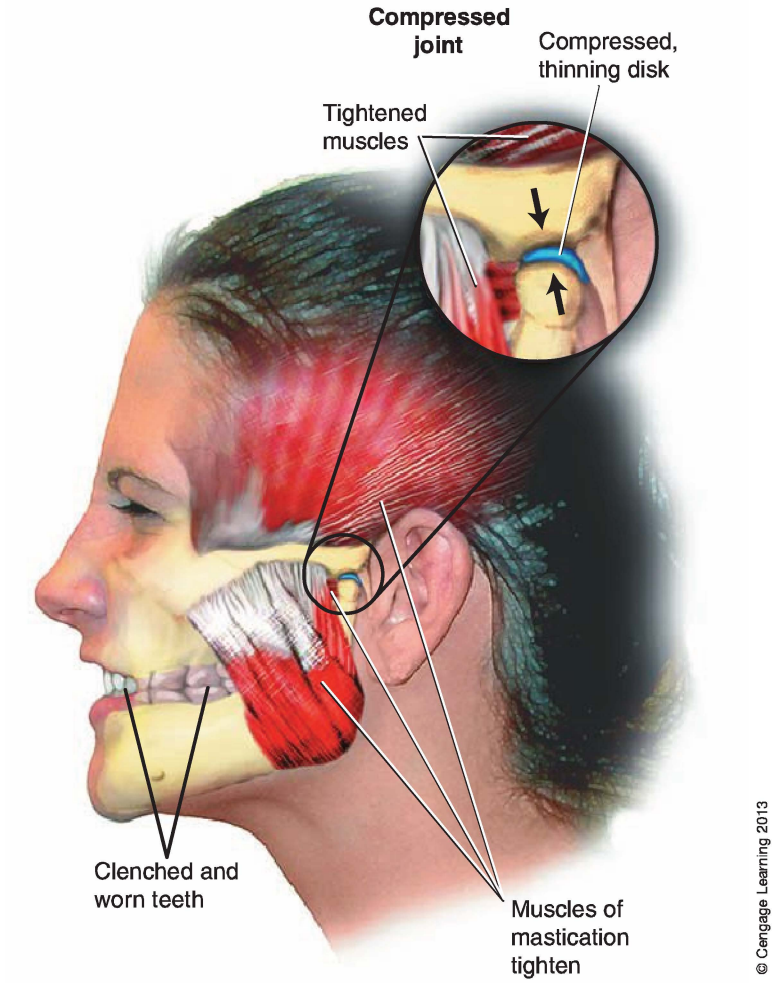

Figure 22–3. TMJ disc compresses due to clenched teeth and tightened muscles.

As the condition advances, catching or locking may occur. **Subluxation** takes place when the condyle is displaced anteriorly over the articular eminence and cannot be returned voluntarily to its normal position. As a result, the mouth cannot be closed, and prolonged spasmodic contraction of the muscles of mastication occurs. Subluxation can be corrected by wrapping the fingers in gauze and placing the thumbs on the occlusal surfaces of the mandibular posterior teeth. Then, by simultaneously pushing downward and guiding the mandible backward, the condyle can be returned to its normal position.

TMJ disorder (TMD), characterized by muscle soreness, may occur with or without TMJ pathology or dysfunction. **Bruxism**, or grinding of the teeth, may be one cause of TMD, stress or tension may be another.

Inflammation of the joint—**arthritis**—may result from wear or tear within the joint or as a consequence of systemic disease such as rheumatoid arthritis. Cortisone may be used to alleviate the pain of arthritis.

SUMMARY

The temporomandibular joint is a complex, interrelated joint. Anatomic structures of the TMJ influence its function. The mandibular condyle rests in the mandibular fossa. The articular disc separates the TMJ into upper and lower joint compartments, which perform either a hinge motion or a gliding movement. A capsule surrounds and encloses the entire joint. It is fused with the disc anteriorly; posteriorly, the disc and capsule are connected by the retrodiscal pad. Clinical concerns associated with the TMJ include internal derangement, subluxation, temporomandibular joint disorder (TMD), and arthritis.

WORKSHEET

Answer the following questions and fill in the blanks

1. What structure rests between the condyle and the articular eminence? _____
2. Describe the attachment between the condyle and the disc. _____
3. State the functions of synovial fluid. _____
4. Describe the anterior and posterior attachments of the capsule. _____
5. Briefly describe the two TMJ movements. When do they occur? _____
6. Describe the anatomic features associated with internal derangement, subluxation, and temporomandibular joint disorder (TMD). _____
7. Identify the nerve and blood supply to the TMJ. _____

Answer the following multiple-choice questions

1. What structure lies between the mandibular fossa and the condyle?
   - **a.** articular disc or meniscus
   - **b.** capsule
   - **c.** retrodiscal pad
   - **d.** lateral pterygoid muscle
   - **e.** masseter muscle
2. The bones of the TMJ can slide over each other without friction due to:
   - **a.** crepitus
   - **b.** subluxation
   - **c.** synovial fluid
   - **d.** bruxism
   - **e.** cortisone
3. What structure surrounds the entire TMJ?
   - **a.** meniscus
   - **b.** articular tubercle
   - **c.** mandibular fossa
   - **d.** capsule
   - **e.** synovial cavity
4. A cracking sound associated with opening of the TMJ is known as:
   - **a.** subluxation
   - **b.** crepitus
   - **c.** arthritis

5. What structure separates the TMJ into the upper and lower compartments?

a. capsule

b. mandibular fossa

c. articular tubercle

d. articular disc or meniscus

e. retrodiscal pad

APPENDIX A

Sequence of Tooth Development

TABLE A–1 Primary Dentition
TABLE A–2 Permanent Dentition
TABLE A–3 Chronology of the Human Dentition

TABLE A–1. Primary Dentition

DECIDUOUS DENTITION	FORMATION OF THE ENAMEL ORGAN (WEEKS IN UTERO)	BEGINNING OF CALCIFICATION	CROWN COMPLETION	AVERAGE ERUPTION (MONTHS, APPROX.)	ROOT COMPLETION
MAXILLARY					
Central incisor	10	3–4 mo in utero	4 mo	7½ mo	1½–2 yr
Lateral incisor	12	4½ mo in utero	5 mo	8 mo	1½–2 yr
Canine	14	5¼ mo in utero	9 mo	18 mo	2½–3 yr
First molar	13–14	5 mo in utero	6 mo	14 mo	2–2½ yr
Second molar	15–16	6 mo in utero	10–12 mo	24 mo	3 yr
MANDIBULAR					
Central incisor	11	4½ mo in utero	4 mo	6 mo	1½–2 yr
Lateral incisor	12	4½ mo in utero	4¼ mo	7 mo	1½–2 yr
Canine	14	5 mo in utero	9 mo	16 mo	2½–3 yr
First molar	13–14	5 mo in utero	6 mo	12–16 mo	2–2½ yr
Second molar	15–16	6 mo in utero	10–12 mo	20–30 mo	3 yr

This table was published in *Wheeler's Dental Anatomy, Physiology, and Occlusion,* eighth edition, Major Ash and Stanley Nelson, Copyright Saunders (2002).

TABLE A–2. Permanent Dentition

DECIDUOUS DENTITION	FORMATION OF THE ENAMEL ORGAN (WEEKS IN UTERO)	BEGINNING OF CALCIFICATION	CROWN COMPLETION (YEARS)	AVERAGE ERUPTION (PLUS OR MINUS)	ROOT COMPLETION
MAXILLARY					
Central incisor	7	3–4 mo	4–5 yr	7–8 yr	10 yr
Lateral incisor	7	10 mo	4–5 yr	8–9 yr	11 yr
Canine	7	4–5 mo	6–7 yr	11–12 yr	13–15 yr
First premolar	7	1¼–1½ yr	5–6 yr	10–11 yr	12–13 yr
Second premolar	7	2–2¼ yr	5–6 yr	11–12 yr	12–14 yr
First molar	5½	At birth	2½–3 yr	6–7 yr	9–10 yr
Second molar	6 mo after birth	2½–3 yr	7–8 yr	12–13 yr	14–16 yr
Third molar	6 yr after birth	7–9 yr	12–16 yr	17–21 yr	18–25 yr
MANDIBULAR					
Central incisor	7	3–4 mo	4–5 yr	6–7 yr	9 yr
Lateral incisor	7	3–4 mo	4–5 yr	7–8 yr	10 yr
Canine	7	4–5 mo	6–7 yr	9–10 yr	12–14 yr
First premolar	7	1¼–2 yr	5–6 yr	10–12 yr	12–13 yr
Second premolar	7	2¼–2½ yr	6–7 yr	11–12 yr	13–14 yr
First molar	5½	At birth	2½–3 yr	6–7 yr	9–10 yr
Second molar	6 mo after birth	2½–3 yr	7–8 yr	11–13 yr	14–15 yr
Third molar	6 yr after birth	8–10 yr	12–16 yr	17–21 yr	18–25 yr

This table was published in *Wheeler's Dental Anatomy, Physiology, and Occlusion,* eighth edition, Major Ash and Stanley Nelson, Copyright Saunders (2002).

TABLE A–3. Chronology of the Human Dentition

PRIMARY DENTITION

	BEGINNING CALCIFICATION	CROWN COMPLETION	ERUPTION	ROOT COMPLETION
UPPER JAW				
Central incisor	3–4 mo in utero	4 mo	7½ mo	1½–2 yr
Lateral incisor	4½ mo in utero	5 mo	8 mo	1½–2 yr
Canine	5¼ mo in utero	9 mo	16–20 mo	2½–3 yr
First molar	5 mo in utero	6 mo	12–16 mo	2–2½ yr
Second molar	6 mo in utero	10–12 mo	20–30 mo	3 yr
LOWER JAW				
Central incisor	4½ mo in utero	4 mo	6½ mo	1½–2 yr
Lateral incisor	4½ mo in utero	4¼ mo	7 mo	1½–2 yr
Canine	5 mo in utero	9 mo	16–20 mo	2½–3 yr
First molar	5 mo in utero	6 mo	12–16 mo	2–2½ yr
Second molar	6 mo in utero	10–12 mo	20–30 mo	3 yr

PERMANENT DENTITION

	BEGINNING CALCIFICATION	CROWN COMPLETION	ERUPTION	ROOT COMPLETION
UPPER JAW				
Central incisor	3–4 mo	4–5 yr	7–8 yr	10 yr
Lateral incisor	10 mo	4–5 yr	8–9 yr	11 yr
Canine	4–5 mo	6–7 yr	11–12 yr	13–15 yr
First premolar	1¼–1½ yr	5–6 yr	10–11 yr	12–13 yr
Second premolar	2–2¼ yr	6–7 yr	10–12 yr	12–14 yr
First molar	At birth	2½–3 yr	6–7 yr	9–10 yr
Second molar	2½–3 yr	7–8 yr	12–13 yr	14–16 yr
Third molar	7–9 yr	12–16 yr	17–21 yr	18–25 yr
LOWER JAW				
Central incisor	3–4 mo	4–5 yr	6–7 yr	9 yr
Lateral incisor	3–4 mo	4–5 yr	7–8 yr	10 yr
Canine	4–5 mo	6–7 yr	9–10 yr	12–14 yr
First premolar	1¼–2 yr	5–6 yr	10–12 yr	12–13 yr
Second premolar	2¼–2½ yr	6–7 yr	11–12 yr	13–14 yr
First molar	At birth	2½–3 yr	6–7 yr	9–10 yr
Second molar	2½–3 yr	7–8 yr	11–13 yr	14–15 yr
Third molar	8–10 yr	12–16 yr	17–21 yr	18–25 yr

This table was published in *Wheeler's Dental Anatomy, Physiology, and Occlusion,* eighth edition, Major Ash and Stanley Nelson, Copyright Saunders (2002).

APPENDIX B

Measurements of the Permanent Teeth

TABLE B–1.

MAXILLARY TEETH	LENGTH OF CROWN	LENGTH OF ROOT	MESIODISTAL DIAMETER OF CROWN	MESIODISTAL DIAMETER AT CERVIX	LABIO- OR BUCCOLINGUAL DIAMETER	LABIO- OR BUCCOLINGUAL DIAMETER AT CERVIX	CURVATURE OF CERVICAL LINE—MESIAL	CURVATURE OF CERVICAL LINE—DISTAL
Central incisor	10.5	13.0	8.5	7.0	7.0	6.0	3.5	2.5
Lateral incisor	9.0	13.0	6.5	5.0	6.0	5.0	3.0	2.0
Canine	10.0	17.0	7.5	5.5	8.0	7.0	2.5	1.5
First premolar	8.5	14.0	7.0	5.0	9.0	8.0	1.0	0.0
Second premolar	8.5	14.0	7.0	5.0	9.0	8.0	1.0	0.0
First molar	7.5	b1 12 13	10.0	8.0	11.0	10.0	1.0	0.0
Second molar	7.0	b1 11 12	9.0	7.0	11.0	10.0	1.0	0.0
Third molar	6.5	11.0	8.5	6.5	10.0	9.5	1.0	0.0

MAXILLARY TEETH	LENGTH OF CROWN	LENGTH OF ROOT	MESIODISTAL DIAMETER OF CROWN†	MESIODISTAL DIAMETER AT CERVIX	LABIO-OR BUCCOLINGUAL DIAMETER	LABIO- OR BUCCOLINGUAL DIAMETER AT CERVIX	CURVATURE OF CERVICAL LINE—MESIAL	CURVATURE OF CERVICAL LINE—DISTAL
Central incisor	9.0†	12.5	5.0	3.5	6.0	5.3	3.0	2.0
Lateral incisor	9.5†	14.0	5.5	4.0	6.5	5.8	3.0	2.0
Canine	11.0	16.0	7.0	5.5	7.5	7.0	2.5	1.0
First premolar	8.5	14.0	7.0	5.0	7.5	6.5	1.0	0.0
Second premolar	8.0	14.5	7.0	5.0	8.0	7.0	1.0	0.0
First molar	7.5	14.0	11.0	9.0	10.5	9.0	1.0	0.0
Second molar	7.0	13.0	10.5	8.0	10.0	9.0	1.0	0.0
Third molar	7.0	11.0	10.0	7.5	9.5	9.0	1.0	0.0

This table was published in *Wheeler's Dental Anatomy, Physiology, and Occlusion,* eighth edition, Major Ash and Stanley Nelson, Copyright Saunders (2002).

APPENDIX C

Root Depressions and Cervical Lines

The chart shows the variation of the cemento-enamel junction (cervical line), which curves occlusally from 3.5 mm on the maxillary central incisor to almost a straight line on the posterior teeth.

Also shown on this chart are the mesial and distal root flutings, or root depressions.

Familiarity with their location is essential to exploring and scaling the root surfaces.

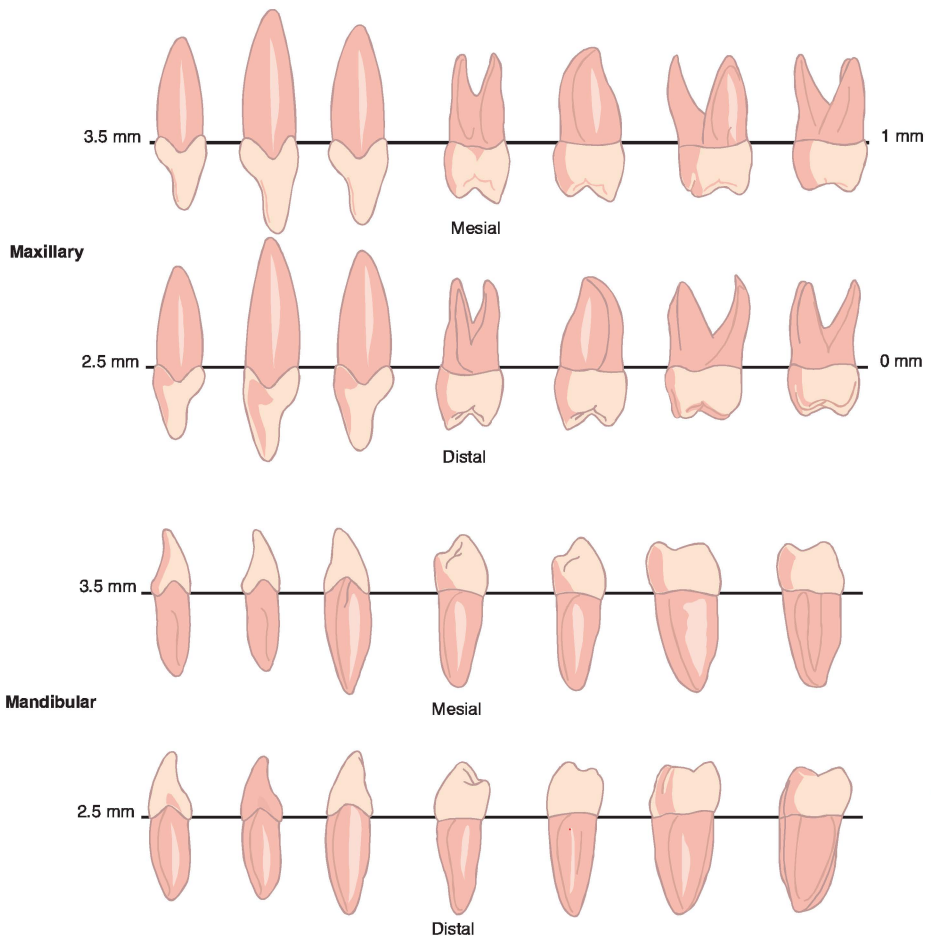

© Cengage Learning 2013

BIBLIOGRAPHY

Nelson, Stanley J. & Ash, Major M., Jr; (2010) Wheeler's Dental Anatomy, Physiology, and Occlusiion, 9th Ed; Saunders Elsevier.

Avery, J. (2005). *Essentials of oral histology and embryology: A clinical approach* (3rd ed.). St. Louis, MO: Mosby.

Bath-Balogh, M., & Fehrenbach, M. J. (2011). *Illustrated dental embryology, histology, and anatomy* (3rd ed.). St. Louis, MO: Elsevier.

Berkovitz, B., Holland, G. R., & Moxham, B. (2009). *Oral anatomy, histology, and embryology* (4th ed.). St. Louis, MO: Mosby.

Bhaskar, S. N. (Ed.). (1990). *Orban's oral histology and embryology* (11th ed.). St Louis, MO: Mosby.

Brand, R., & Isselhard, D. (2003). *Anatomy of orofacial structures* (7th ed.). St. Louis, MO: Mosby.

Carranza, F. (1990). Glickman's clinical periodontology. Philadelphia, PA: Saunders.

Fehrenbach, M. J., & Herring, S. W. (2007). *Anatomy of the head and neck* (3rd ed.). St. Louis, MO: Saunders.

Fuller, J. L., Denehy, G. E., & Schulein, T. M. (2001). *Concise dental anatomy and morphology* (4th ed.). Iowa City, IA: University of Iowa Publications Department.

Gray, H. L. (1987). Anatomy of the human body (29th ed.). Philadelphia, PA: Lea and Febiger.

Ibsen, O., & Phelan, J. (2009). Oral pathology for the dental hygienist (5th ed.). St Louis, MO: Saunders.

Logan, B. M., Hutchings, R. T., & Reynolds, P. (2009). *McMinn's color atlas of head and neck anatomy* (4th ed.). St. Louis, MO: Mosby.

Massler, M., & Schour, I. (1982). *Atlas of the mouth* (2nd ed.). Chicago, IL: American Dental Association.

Melfi, R. C., & Alley, K. E. (2000). *Permar's oral embryology and microscopic anatomy: A textbook for students in dental hygiene* (10th ed.). Philadelphia, PA: Lippincott Williams & Wilkins.

Nield-Gehrig, J. S. (2000). *Fundamentals of periodontal instrumentation* (4th ed.). Philadelphia, PA: Lippincott Williams & Wilkins.

Phinney, D.J., & Halstead, J. H. (2008). *Dental assisting: A comprehensive approach* (3rd ed.). Clifton Park, NY: Delmar Cengage Learning.

Reed, G. M., & Shepard, V. (1976). *Basic structures of the head and neck.* Philadelphia, PA: Saunders.

Scheid, R. C., & Weiss, G. (2011). *Woelful's dental anatomy: Its relevance to dentistry* (8th ed.). Philadelphia, PA: Lippincott Williams and Wilkins.

Shapiro, H. D. (1954). *Maxillofacial anatomy.* Philadelphia, PA: J.B. Lippincott Co.

Wilkins, E. M. (2009). *Clinical practice of the dental hygienist* (10th ed.). Baltimore, MD: Lippincott Williams and Wilkins.

GLOSSARY

A

Abrasion: The result of wearing away.

Active eruption: The emergence of the tooth from its position in the jaw to its position in occlusion.

Aesthetics: Pertaining to appearance.

Afferent: Nerves that carry sensory messages toward the brain.

Alignment: Arranged in a row or a line.

Alveolar crest: The highest portion of alveolar bone.

Alveolar eminence: Outline of the root on the facial portion of the bone.

Alveolar mucosa: Thin, loosely attached mucosa covering the alveolar bone.

Alveolar process: That portion of the maxilla or mandible that surrounds the root of the teeth.

Alveolus: A socket in the bone in which the tooth sits.

Anatomic crown: The portion of the tooth that is covered with enamel.

Anatomic root: The portion of the tooth that is covered with cementum.

Angle's classification of occlusion: The first system developed to classify malocclusion.

Anomaly: A deviation from the normal.

Antagonist: A structure that opposes or counteracts another structure; in the oral cavity, the teeth that meet those in the opposite jaw.

Anterior: Situated in front of.

Anterior superior alveolar (ASA) nerve: Nerve that innervates the maxillary anterior teeth and gingiva.

Anterior tonsillar pillar: Folds of tissue that extend horizontally from the uvula to the base of the tongue.

Apex: A pointed extremity of a structure.

Apical foramen: An aperture in the apex of the root.

Apposition: Laying down of, or addition of.

Arch: A curvature; both the maxillary and mandibular teeth are positioned in an arch formation.

Arch of the aorta: Curved part of the aorta.

Artery: carries oxygenated blood away from the heart.

Arthritis: Inflammation of the joints.

Articular disc: A pad of dense fibrous connective tissue that rests between the condyle and temporal bone.

Articular eminence: Eminence on the temporal bone that articulates with the mandible at the TMJ.

Ascending pharyngeal artery: Branch of the external carotid artery.

Attached gingiva: The portion of the gingiva that can be observed on the external surface.

Attrition: Wearing away by normal use (chewing, biting, etc.).

Autonomic nervous system (ANS): Regulates functions over which we have no conscious control.

Axon: The process that carries impulses away from the cell body.

B

Bartholin's duct: A duct for the sublingual salivary gland, located on the floor of the mouth.

Bifurcated: Divided in two.

Bifurcation: Having two branches; forking into two parts.

Bilateral: Both sides.

Bilaterally symmetric: The same on both sides.

Brachiocephalic artery: Artery that branches off the aorta on the right side.

Bruxism: Grinding of the teeth.

Buccal: Relating to the cheek.

Buccal glands: Minor salivary glands located in the cheek.

Buccal ridge: A prominent feature in premolars that is formed by a well-developed buccal lobe.

Buccoversion: See Labioversion.

C

Calcification: Process of hardening by the deposit of calcium salts.

Canal: A large opening through a bone.

Canine eminence: A prominence on the buccal surface from cervex to tip

Capsule: Surrounds and encloses the entire temporomandibular joint.

Carotid canal: Canal in the temporal bone through which the internal carotid artery travels.

Cementum: Hard tissue that covers the root of the tooth.

Central nervous system (CNS): The brain and spinal cord.

Central pit: A deep depression in the center of the tooth where grooves merge.

Centric occlusion: The relationship of the occlusal surfaces of one arch to those in the opposing arch at physical rest position.

Centric relation: The relationship of the maxillary arch to the mandibular arch when the condyle is in the most retruded position.

Cervical: Relating to the cervix or neck of the tooth.

Cervical line: Where the anatomic crown and root join together.

Cervical ridge: A linear elevation of enamel from the cervix of the tooth.

Cervix: The neck of the tooth; the area where the crown joins the root or enamel joins the cementum.

Cingulum: An eminence or raised area on the lingual surface of the anterior teeth resulting from the lingual lobe formation.

Circumvallate: The largest papillae on the tongue.

Clinical crown: That portion of the tooth visible in the mouth; it extends from the occlusal or incisal edge to the crest of the free gingiva.

Col: A "V"-shaped depression in the facial-lingual interdental papilla located cervically to the contact area of the tooth.

Comminution: Pulverization, crushing, or grinding.

Common carotid artery: Artery that runs up the neck that splits into the external and internal carotid arteries.

Compensating curvatures: Curvatures of the arches that account for strength and efficiency in mastication and assist in the stability of the teeth.

Concave: Curving inward; a depression.

Condyle: Round bony projection of the mandible that forms the TMJ.

Contact area: That portion of the proximal surface of a tooth that touches the adjacent tooth.

Convex: Curving outward.

Cornerstone: Refers to canine teeth, and their location at the corner of each arch.

Coronoid notch: Notch in the anterior border of the ramus.

Coronoid process: Pointed projection of the mandible.

Cranial nerves: Twelve pairs of nerves from the peripheral nervous system.

Crepitus: Crunching of bones in the temporo-mandibular joint.

Crest: A prominence or ridge; the height.

Cribriform plate: A part of the horizontal plate of the ethmoid bone with tiny openings for the olfactory nerves.

Crossbite: A facially positioned mandibular tooth or teeth.

Crown: The portion of the tooth normally visible in the mouth and covered with enamel.

Curve of Spee: See compensating curvatures.

Curve of Wilson: See compensating curvatures.

Cusp: An elevation on the crown of the tooth.

Cusp of Carabelli: The fifth cusp of the maxillary first molar.

Cusp slope: The area extending from the tip of the cusp to both the mesial and distal contact areas.

Cuspids: Refers to the maxillary and mandibular canines, which have sharp, pointed cusps.

D

Deciduous (teeth): Teeth that exfoliate or shed.

Deglutition: Swallowing.

Dendrite: The process that conducts impulses toward the cell body.

Dentin: Comprises the major portion of both the crown and the root of the tooth.

Dentition: Arrangement of the teeth in the dental arch.

Developmental depression: A concavity in a surface that formed while the tooth was developing.

Diphyodont: Having successive sets of teeth.

Distal: The surface of the tooth farthest from the midline.

Distal cusp: An elevation on the crown surface farthest from the midline.

Divergent: Spread.

Ducts of Rivinus: Ducts of the sublingual gland located in the floor of the mouth.

E

Ectoderm: The outermost layer of an embryo that will form the outer covering of the body and the lining of the oral cavity.

Edentulous: Having no teeth.

Edge to edge: A contacting of the incisal edges or cusp tips rather than an interdigitation of cusp and fossae.

Efferent: The nerves that carry motor messages away from the brain.

Embrasure: A curvature on the tooth that allows the food to spill away (spillway).

Eminence: A prominence.

Enamel: Hard tissue that covers the crown of the tooth.

End to end: See Edge to edge.

Endoderm: The innermost embryo layer that develops into the lining of the internal organs.

Eruption: The moving of the tooth occlusally.

Ethmoid bone: A cranial bone in the middle of the skull.

Exfoliate: To shed.

External: On the outer surface.

External auditory meatus: A canal in the ear.

External carotid artery: Artery that originates from the common carotid artery and supplies the face.

External oblique line: Located on the lateral side of the mandible where the ramus joins the body.

Extrinsic tongue muscles: Tongue muscles that originate from structures outside of the tongue.

F

Facial: Toward the face.

Facial artery: A branch of the external carotid artery that supplies the face primarily.

Facial nerve: (VII) Seventh cranial nerve that supplies the muscle of facial expression.

Filiform: Long, thin, more flexible papillae, that are grayish in color.

Fissure: A faulty groove.

Flared (divergent) roots: Roots of posterior teeth that allow for growth of the permanent teeth forming beneath them.

Foliate: Large, raised papillae located on the lateral surfaces of the posterior third of the tongue.

Foramen: An opening in a bone or hard tissue.

Foramen caecum: A "V"-shaped terminal sulcus at the posterior area of the median sulcus.

Foramen lacerum: Opening through which the internal carotid artery travels and covered by cartilage.

Foramen magnum: Large opening through which the spinal cord travels.

Foramen ovale: Opening in the sphenoid bone through which the mandibular nerve travels.

Foramen rotundum: Opening in the sphenoid bone through which the maxillary nerve travels.

Foramen spinosum: Opening in the sphenoid bone through which the middle meningeal artery travels.

Fordyce granules: Small, yellow spots on the buccal mucosa and inner lip.

Fornex: Vault or arch shaped.

Fossa: A shallow depression.

Fovea palatinus: Two small indentations, one on either side of the raphe, located at the junction of the hard and soft palate.

Free (marginal) gingiva: Tissue attached only at the gingival groove that surrounds the teeth.

Free gingival junction: A slight demarcation about 1.2 to 1.8 mm from the gingival crest where the attached gingiva and the free gingiva merge.

Frenum: A fold of mucous membrane that connects two parts.

Fungiform: Broad, round, red toadstool-shaped papillae on the tongue.

Furcation: An area where the root trunk forks or divides.

Furrow: A groove.

G

Genial tubercles: Bone spurs.

Gingiva: The mucosa that covers the alveolar bone and surrounds the teeth.

Gingival crest: The prominent edge of occlusal or incisal gingiva.

Glossopharyngeal nerve: (IX) Ninth cranial nerve supplying the posterior 1/3 of the tongue with taste and contributes to the pharyngeal plexus.

Greater palatine foramen: Opening in the palatine bone through which the greater palatine nerve and artery travel.

Groove: A long, narrow depression.

H

Hard palate: The bony anterior two-thirds of the palate that is covered with mucosa.

Heart shaped: A characteristic of the maxillary third molar.

Heterodont: Different types of teeth with the same dentition (incisors, canines, molars, etc.).

Histodifferentiation: Development into a specialized tissue.

Histology: The study of tissues.

Homodont: Only one type of tooth in the dentition (e.g., all molars).

Hypoglossal nerve: (XII) Twelfth cranial nerve that is motor to the tongue muscles.

I

Ideal occlusion: A complete harmonious relationship of the teeth as well as of other structures of the masticatory system.

Incisal: The biting surface of the anterior teeth.

Incisal edge: Flat edge of the maxillary and mandibular teeth used for biting.

Incisive (nasopalatine) foramen: Opening in the maxilla through which the nasopalatine nerves and arteries travel covered by the parotid papilla.

Incisive papilla: A small, raised, rounded structure of soft tissue at the anterior midline of the hard palate.

Inferior: Lower.

Inferior alveolar nerve: Nerve in the mandible that supplies the mandibular posterior teeth.

Inferior nasal concha: Paired facial bones that form the nasal cavity.

Inferior orbital fissure: Fissure in the orbit through which travels the infraorbital and zygomatic nerves.

Infrahyoid muscles: Hyoid muscles located below the hyoid bone.

Infraorbital foramen: Foramen in the maxilla through which passes the infraorbital nerve and artery.

Infraversion: A tooth positioned above the plane of occlusion.

Initiation: The starting of tooth development.

Insertion: The movable end of a muscle.

Intercuspation (interdigitation): Interlocking; a cusp-to-fossa relationship of the maxillary teeth to the mandibular teeth.

Internal: Within.

Internal carotid artery: A branch of the common carotid artery that supplies the brain.

Internal jugular vein: The primary vein that drains the head and neck.

Internal oblique line: Line on the internal mandible to which the mylohyoid muscle attaches.

Interproximal: The space between two adjoining surfaces.

Interproximal space: Marjory's term not mine.

Intrinsic tongue muscles: Muscles located entirely within the tongue.

Invagination: To enclose within.

J

Joint: The juncture point of two bones.

Jugular foramen: Large foramen hrough which passes the internal jugular vein and cranial nerves IX, X and XI.

K

Keystone: The mandibular first molar: its positioning in the arch is important for the appropriate alignment of the other permanent teeth.

L

Labial: Relating to the lip.

Labial commissure: The closure line of the lips.

Labial glands: Minor salivary glands located in the lips.

Labial ridge: A centrally located, well-developed middle lobe that extends from the cervix to the tip of the cusp of the maxillary canine.

Labial tubercle: A small projection in the middle of the upper lip.

Labiomental groove: A shallow linear depression between the center of the lower lip and the chin.

Labioversion: A tooth positioned more facially than normal.

Lacrimal bones: Paired facial bones that forms the orbit on the medial side.

Lamina dura: Membrane covering or lining of tooth area.

Lateral: To the side.

Lateral plate: Part of the pterygoid process.

Lateral pterygoid: A muscle of mastication.

Lesser palatine foramen: Opening in the palatine bone through which the lesser palatine nerve and artery pass.

Line angle: An angle formed by the joining of two surfaces.

Linea alba: A raised, white horizontal extension of soft tissue along the buccal mucosa at the occlusal line.

Lingual: Relating to the tongue.

Lingual artery: Branch of the external carotid artery that supplies the tongue.

Lingual fossae: Shallow depressions in the lingual surface of the tooth.

Lingual frenum: An elevated fold of soft tissue located on the floor of the mouth at the midline.

Lingual glands: Minor salivary glands located around the tongue.

Lingual nerve: Nerve that supplies the tongue, floor of the mouth and lingual gingiva of the mandibular teeth—a part of the mandibular nerve.

Lingual ridge: Divides the lingual fossae into two segments.

Lingula: A tongue shaped process

Linguoversion: A tooth positioned more lingually than normal.

Lobe: A major center of tooth formation.

M

Major groove pattern: The deep grooves located on the occlusal surface of posterior teeth.

Major salivary glands: Important salivary glands

Malalignment: See Malocclusion.

Malocclusion: Any deviation from the ideal positioning of the teeth.

Mamelon: A rounded prominence on the incisal edge of newly erupted incisors that are remnants of lobe formation.

Mandibular: Relating to the lower jaw or mandible.

Mandibular (glenoid) fossa: A depression on the temporal bone into which the condyle of the mandible fits for the TMJ.

Mandibular foramen: Located on the internal surface of the mandible through which the inferior alveolar nerve and artery travels.

Mandibular nerve: A mixed nerve that is the third division of the trigeminal nerve-motor to the muscle of mastication-supplies the mandibular teeth.

Mandibular notch: A notch located between the condyle and coronoid process on the mandible.

Mandibular torus: An overgrowth of bone occurring bilaterally on the internal borders of the mandible.

Marginal ridge: A linear elevation located around the perimeter of a surface.

Masseter: A strong muscle of mastication.

Mastication: Chewing.

Masticatory system: Teeth and surrounding structures: jaws, temporomandibular joint, muscles, lips, tongue, and related nerves and blood vessels.

Mastoid process: Area of the temporal bone located posterior to the ear.

Matrix: A basic substance from which something forms.

Maxilla: The upper jaw.

Maxillary: Relating to the upper jaw or maxilla.

Maxillary artery: A branch of the external carotid artery.

Maxillary nerve: Sensory nerve that is the second division of the trigeminal nerve-supplies the maxillary teeth.

Maxillary sinus: Paranasal sinus located on the maxilla.

Maxillary tuberosity: A small, rounded extension of bone, covered with soft tissue, posterior to the last maxillary tooth.

Medial: Near the middle or medial plane.

Media plate: A portion of the pterygoid process.

Medial pterygoid: A muscle of mastication.

Median palatine suture: The median palatine suture is the area on the maxilla formed when the two halves of the bone join together during formation.

Median sulcus: A shallow groove extending along the midline of the tongue, ending in a slight depression.

Melanin: A dark pigment.

Mental: Relating to the chin.

Mental foramen: Opening on the external mandible between the roots of the mandibular premolar teeth.

Mental protuberance: A prominence toward the chin.

Mesial: Toward the middle.

Mesial concavity: A depression located on both the enamel and cementum.

Mesial interradicular groove: A deep groove located on the root of the maxillary first premolar.

Mesiolingual groove: In the mandibular first premolar, the groove that delineates the lingual cusp.

Mesoderm: The middle layer of an embryo that will form the skeletal and muscular systems, as well as the cementum, dentin, and pulp of the tooth.

Mesognathic: Describes the normal profile.

Middle superior alveolar (MSA) nerve: Nerve that supplies the maxillary premolar teeth and gingiva as well as the mesiobuccal root of the maxillary first molar.

Minor salivary glands: Small salivary glands.

Mixed dentition: Presence of deciduous and permanent teeth in the mouth at the same time.

Modiolus: An area of intertwining muscles.

Morphodifferentiation: Development into a specific form or structure.

Morphology: The study of form or structure.

Motor-afferent: Nerve that supplies a skeletal muscle.

Mucogingival junction: The line of demarcation between the attached gingiva and the alveolar mucosa.

Mucosa: Mucous membrane.

Mucous: Describing a thick, viscous saliva.

Muscles of facial expression: Muscles located on and around the face that display facial expressions.

Muscles of mastication: Muscles that attach to and move the mandible.

Muscles of the ears: Muscles located around the ear.

Muscles of the mouth: Muscles located around the mouth.

Muscles of the neck: Muscles that move the neck.

Muscles of the nose: Muscles located around the nose.

Muscles of the pharynx: Muscles that supply the pharynx.

Muscles of the scalp: Muscles located on the scalp.

Muscles of the soft palate: Muscles that supply the soft palate.

Muscles of the tongue: Muscle that move the tongue.

Mylohyoid groove: Groove on the internal mandible.

N

Nasal: Relating to the nose.

Nasal bones: Bones relating to the nose

Nasolabial groove: A shallow depression extending from the corner of the nose to the corner of the lips.

Neurocranium: The portion of the cranium that houses and protects the brain.

Neuron: A nerve cell.

Nonfunctioning cusp: A cusp that plays no part in occlusion.

Normal occlusion: Conforms closely to an ideal occlusal relationship but involves some variations from it.

O

Oblique ridge: A linear elevation that transverses a surface.

Occipital artery: A branch of the external carotid artery.

Occipital bone: A single bone in the posterior skull.

Occlude: To close the teeth together.

Occlusal: Relating to the biting surface.

Occlusion: The relationship of the maxillary and mandibular arches in a closed position.

Openbite: Open bite is an existing space between the mandibular and maxillary teeth when the teeth are occluded.

Ophthalmic nerve: First division of the trigeminal nerve.

Optic foramen: Opening within the orbit.

Oral cavity: The mouth.

Oral mucosa: The mucous membrane that lines the oral cavity.

Oral vestibule: The area between the inner lips and cheeks and the front surfaces of the teeth.

Origin: The fixed end of a muscle.

Overbite: A deep or vertical overlap of the maxillary teeth onto the mandibular teeth that exceeds the normal, or one-third the depth of the mandibular incisors.

Overjet: A horizontal overlap creating a protrusion or space between the labial surface of the mandibular incisors and the lingual surface of the maxillary incisors.

P

Palatine bone: Paired bones that form the palate.

Palatine glands: Salivary glands located in the palate.

Palatine raphe: A junction of soft tissue extending vertically along the entire midline of the hard palate.

Palatine rugae: Paired transverse, palatine folds of soft tissue on the anterior portion of the hard palate.

Palatine torus: A bony prominence of varied size located at the midline of the hard palate.

Parasympathetic: The system that slows heart rate and respiration.

Parietal bones: Paired cranial bones that form the skull cap.

Parotid gland: One of the major salivary glands that secretes a serous saliva.

Parotid papilla: Tissue covering the nasopalatine foramen.

Passive eruption: The increased exposure of the tooth. As a person ages, the gingiva recedes so that the clinical crown is greater.

Periodontal ligament: Surrounds the root of the tooth, supporting and suspending the tooth in the alveolus.

Periodontium: The structures that surround and support the teeth.

Peripheral nervous system (PNS): Composed of the nerves that travel away from the central nervous system.

Permanent teeth: The teeth that replace the deciduous or primary teeth.

Philtrum: A shallow depression extending from the area below the middle of the nose to the center of the upper lip.

Pit: A pinpoint of depression.

Plica: A fold of tissue.

Point angle: The area on the tooth where three surfaces meet.

Polyphyodont: Having several sets of teeth during a life span.

Posterior: Toward the back.

Posterior auricular artery: A branch of the external carotid artery.

Posterior superior alveolar (PSA) nerve: Nerve that supplies the maxillary molar teeth and gingiva.

Posterior tonsillar pillar: A set of arches of tissue set farther back in the throat than the anterior tonsillar pillar.

Prefunction eruption: See Active eruption.

Primary (deciduous) teeth: Sometimes referred to as "baby teeth"

Primate spacing: The normal spacing between primary anterior teeth.

Prognathic: When the mandible protrudes.

Proliferation: Rapid reproduction.

Proximal: Nearest the point of attachment; the mesial or distal surface of the tooth.

Proximal surface: The surface of the tooth adjacent to the next tooth; refers to the mesial and distal surfaces.

Pterygoid fossa: Depression located between the medial and lateral pterygoid plates.

Pterygoid fovea: Depression located on the condyle.

Pterygoid hamulus: Pointed process located on the medial pterygoid plate.

Pterygoid plexus of veins: Collection of veins around the pterygoid muscles and maxillary arteries.

Pterygoid process: potion of the sphenoid bone.

Pulp: The only soft tissue of the tooth.

Pulp canal: The portion of the pulp in the root of the tooth.

Pulp cavity: The entire space within the tooth that contains pulp tissue.

Pulp chamber: The portion of the pulp in the crown of the tooth.

Pulp horn: The portion of the pulp chamber that extends toward a cusp.

Q

Quadrant: A fourth (of the dentition).

R

Ramus: The superior projection of the mandible.

Raphe: A union of soft tissue.

Resorb: To dissolve into the tissue.

Retrognathic: When the mandible retrudes.

Retromolar area: A triangular area of bone, covered with soft tissue, posterior to the last mandibular tooth.

Retromolar fossa: Depression on the mandible located posterior to the mandibular third molar.

Ridge: A linear elevation.

Root: Portion of the tooth that is located in the bone and not normally visible.

Root depression: A shallow, linear concavity located on the root.

Root trunk: That portion of the root that is not bifurcated or trifurcated.

S

Sella turcica: A concavity located on the sphenoid bone which houses the pituitary gland.

Sensory-afferent: A nerve that conveys messages from the sense organs.

Serous: Thin, watery saliva.

Socket: A cavity in the bone; see also Alveolus.

Soft palate: The posterior third of the palate, comprised of muscular fibers covered with mucosa.

Somatic: Nerves that supply muscles.

Sphenoid bone: A single bone that resembles a bat and articulates with all cranial and facial bones.

Spillway: see Embrasure.

Stensen's duct: The duct of the parotid gland.

Stensen's papilla: A small, raised flap of soft tissue on the buccal mucosa opposite the maxillary molar.

Stomodeum: Primitive mouth.

Stylomastoid foramen: Foramen in the temporal bone through which the facial nerve travels.

Sublingual caruncles: Round, elevated sections of soft tissue on either side of the lingual frenum, directly behind the central incisors on the floor of the mouth.

Sublingual fold: An elevated fold of soft tissue extending, medially, along the floor of the mouth toward the tongue.

Sublingual gland: Smallest of the major salivary glands secreting a mucous saliva located in the mandible.

Subluxation: Occurs when the condyle is displaced anteriorly over the articular eminence.

Submandibular fossa: Depression on the mandible which houses that submandibular gland.

Submandibular gland: One of the major salivary glands that secretes a mixed saliva- located on the mandible.

Submucosa: The layer of tissue under the mucous membrane.

Succedaneous: A tooth that replaces or succeeds another tooth.

Sulcus: A shallow depression.

Superciliary ridge: Ridge of bone located above each eyebrow.

Superficial temporal artery: A branch of the external carotid artery.

Superior: Higher or above.

Superior orbital fissure: A fissure located in the orbit.

Superior thyroid artery: A branch of the external carotid artery.

Supernumerary: Exceeding a fixed number.

Supplemental grooves: Additional grooves present in maxillary and mandibular third molars.

Suprahyoid muscles: Muscles located above the hyoid bone.

Supraorbital foramen: Foramen located on the top of the orbit.

Supraversion: A tooth positioned above the plane of occlusion.

Suture: A joining of two bones.

Symmetric: Exact form of both sides of a dividing line.

Sympathetic: The system that functions in response to emergencies.

Synovial fluid: The lubricating fluid of the joints (TMJ).

T

Taste buds: These are located in the papillae of the tongue and are stimulated when food is dissolved.

Temporalis: One of the muscles of mastication.

Temporomandibular joint (TMJ): The articulation between the temporal bone and the mandible.

Terminal mesial step: The position of a vertical plane along the distal surfaces when the deciduous second molars are in Class I position.

Terminal plane: The distal surfaces of the maxillary and mandibular deciduous second molars that are on the same line or plane.

TMJ disorder: Problems with one or both of the Temporomandibular joints.

Tonsils: Lymphatic tissue masses found in the fauces.

Torsoversion: A rotated tooth.

Transverse palatine suture: Suture that joins the maxillae and palatine bones.

Transverse ridge: A linear elevation that crosses a surface (usually the occlusal surface).

Triangular fossae: Structures of premolars that assist with the grinding of food.

Triangular ridge: A linear elevation that forms a triangle.

Trifurcated: Forked or divided into three (roots).

Trigeminal nerve: The fifth cranial nerve that is both sensory and motor and supplies the muscles of mastication, teeth, tongue and mouth.

Tubercle: A small, rounded projection.

Tuberosity: A large, rounded projection.

U

Underjet: When the mandibular tooth is facial rather than lingual to the maxillary anterior teeth.

Universal: Common to all purposes.

Uvula: A downward projection of the soft palate comprised of connective tissue, muscles, and glands.

V

Vein: Returns blood to the heart.

Vermilion: Red.

Vermilion zone: The pink border of the lips.

Visceral: Nerves that supply internal organs (viscera).

Viscerocranium: The part of the facial skeleton that gives us our appearance.

Vomer: Single facial bone that forms part of the nasal septum.

W

Wharton's duct: Duct of the submandibular salivary gland located at the sublingual caruncles.

Y

Y-shaped groove pattern: A feature of the occlusal surface of the mandibular second premolar.

Z

Zygomatic process: Area around the cheeks.

INDEX

Information in figures and tables is indicated by *f* and *t*.

A

Abducent nerve, 252*t*
Abrasion, 8
Accessory meningeal artery, 273*f*, 274
Accessory nerve, 252*t*
Acoustic nerve, 252*t*
Active eruption, 8, 176–177
Aesthetics, canines and, 80
Afferent nerves, 251
Alar muscle, 235*f*
Alba, 13*t*
Alignment, 139
Alveolar bone, 34*f*
Alveolar mucosa, 36*f*, 37
Alveolar process, 34*f*, 35, 207*f*, 214
Alveolus, 35
Anatomic crown, 27, 28*f*
Anatomic root, 27, 28*f*
Angle's classification, 187–189
Angular artery, 271*f*, 272
Anomaly, 57, 153, 177
Antagonist, 68
Anterior auricular, 234*f*
Anterior deep temporal artery, 274
Anterior retromandibular vein, 277*f*
Anterior superior alveolar artery, 270*f*, 275*f*
Anterior superior alveolar (ASA) nerve, 254, 260*t*
Anterior tonsillar pillar, 17, 19*f*
Anterior tympanic artery, 272, 273*f*
Aorta, 268*f*
Aortic arch, 268, 268*f*
Apex, 30, 30*f*
Apical foramen, 32*f*, 33
Apposition, 175–176, 175*f*
Arteries, 268
Arthritis, 292
Articular disc, 289, 289*f*
Articular eminence, 210, 289
Articular tubercle, 210, 211*f*, 289*f*
ASA. *See* Anterior superior alveolar (ASA) nerve
Ascending palatine artery, 270
Ascending pharyngeal artery, 269, 270*f*
Attached gingiva, 37
Attrition, 8, 175*f*
Auriculotemporal nerve, 258
Autonomic nervous system (ANS), 251
Axon, 250, 250*f*

B

Baby teeth. *See* Primary dentition
Bartholin's duct, 283
Bell stage, 174–175, 175*f*
Bicuspids. *See* First mandibular premolars
Bifurcation, 98, 139
Brachiocephalic artery, 268
Brachiocephalic trunk, 268*f*, 270*f*
Bruxism, 292
Bucca, 13*t*
Buccal, 13*t*
Buccal artery, 274
Buccal frenum, 16, 17*f*, 36*f*
Buccal glands, 284
Buccal mucosa, 36*f*
Buccal nerve, 257, 261*t*
Buccal ridge, 99, 112
Buccal surface
  defined, 29, 29*f*
  of first mandibular molars, 140, 141*f*, 142, 144
  of first mandibular premolars, 111*f*, 112, 112*f*, 113–114
  of first maxillary molars, 124, 125*f*, 126, 128–129
  of first maxillary premolars, 99, 100*f*, 102–103
  of second mandibular molars, 147*f*, 148*f*
  of second mandibular premolars, 116*f*, 117, 117*f*, 118
  of second maxillary molars, 132*f*
  of second maxillary premolars, 105*f*
Buccinator, 236*f*, 237
Buccoversion, 186, 186*f*
Bud stage, 174, 175*f*

C

Calcification, 175, 175*f*, 297*t*, 298*t*, 299*t*
Canal, 206
Canine eminence, 214
Canines
  aesthetics and, 80
  defined, 5
  in eruption sequence, 7*t*
  mandibular
    characteristics of, 85
    clinical considerations, 87
    labial surface if, 86*f*, 87, 87*f*
    lingual surface of, 86*f*, 87, 87*f*, 88
    in primary dentition, 167, 168*f*
    proximal surfaces of, 86*f*, 87, 87*f*, 88
  maxillary
    characteristics of, 81
    distal surface of, 82*f*, 83*f*
    labial surface of, 82*f*, 83, 83*f*, 84
    lingual surface of, 82*f*, 83, 83*f*, 84
    mesial surface of, 82*f*, 83*f*
    in primary dentition, 166, 166*f*
    proximal surface of, 83, 83*f*, 84
  overview of, 80
  in primary dentition, 163*f*
Caninus, 236*f*, 237
Cap stage, 174, 175*f*
Capsule, 290
Carotid canal, 208*f*, 211
Carotid sinus nerve, 263
Cementum, 31, 32*f*, 33, 34*f*, 35
Central mandibular incisors
  characteristics of, 68–69
  clinical considerations, 71
  description of, 68–72
  incisal view of, 70*f*, 71, 72
  labial surface of, 69, 70*f*, 72
  lingual surface of, 69, 70*f*, 72
  overview of, 68
  proximal surfaces of, 70*f*, 71, 72
Central maxillary incisors, 57–61, 59*f*
  clinical considerations, 60
  labial surface of, 58, 59*f*, 60
  lingual surface of, 58, 59*f*, 60
  proximal surfaces of, 60, 60*f*, 61
Central nervous system (CNS), 249
Centric occlusion, 189

Centric relation, 189
Cervical lines, 301*t*, 302
Cervical ridge, in primary teeth, 164
Cervix, 27, 28*f*
Chorda tympani, 258–259, 259*f*, 261
Chronology of human dentition, 299*t*
Cingulum, 58, 59*f*
Circumvallate papilla, 20, 21*f*, 22*t*
Clinical crown, 28, 28*f*
CNS. *See* Central nervous system (CNS)
Collateral axon, 250*f*
Common carotid arteries, 268, 268*f*, 270*f*, 271*f*
Common facial vein, 277*f*
Compensating curvatures, 197*f*, 198
Compressor nares, 235, 235*f*
Condyle, 216, 216*f*, 217*f*
Contact area, 30, 30*f*, 195–196, 196*f*
Cornerstone teeth, 80. *See also* Canines
Coronal suture, 207*f*, 208*f*
Coronoid notch, 216, 216*f*, 217*f*
Coronoid process, 216, 216*f*, 217*f*
Corrugator, 234, 235*f*
Cranial nerves, 251
Crepitus, 291
Cribriform plate, 209*f*, 211
Crista galli, 213*f*
Crossbite, 185
  anterior, 184*t*
  posterior, 184*t*
Crown, 27, 28*f*
Curve of Spree, 197*f*, 198
Curve of Wilson, 197*f*, 198
Cusp of Carabelli, 123
Cusp slope, 83
Cuspids, 80. *See also* Canines

D

Deciduous dentition, 3, 4*f*, 163–169
Deep auricular artery, 272, 273*f*
Deep facial vein, 277*f*
Deep lingual artery, 269, 271*f*
Deep temporal nerves, 257
Deglutition, 240, 243
Dendrite, 250, 250*f*
Dentin, 32*f*, 33, 297*t*, 298*t*, 299*t*
Dentition, 3–4, 4*f*. *See also* Teeth
Depressor anguli oris, 237*f*, 238
Depressor labii inferioris, 237*f*, 238
Descending palatine artery, 270*f*, 275*f*, 276*f*
Development, tooth, 297*t*, 298*t*, 299*t*
  anomalies in, 177
  growth and, 173–176
  overview of, 173
Developmental depressions, 58
Diameters, 301*t*
Digastric, 228, 229*f*, 231*f*
Digastric nerve, 261
Dilator nares, 235, 235*f*
Diphyodonts, 4
Distal cusp, 142
Distal surface
  defined, 28, 29*f*
  of first mandibular molars, 141*f*, 142, 142*f*, 145
  of first mandibular premolars, 111*f*, 112, 112*f*, 114
  of first maxillary molars, 125*f*, 126–127, 126*f*, 130
  of first maxillary premolars, 100*f*, 101, 101*f*
  of lateral maxillary incisors, 62*f*
  of maxillary canines, 82*f*, 83*f*
  of second mandibular molars, 147*f*, 148*f*
  of second mandibular premolars, 116*f*, 117, 117*f*, 119
  of second maxillary molars, 132*f*
  of second maxillary premolars, 105*f*
Distocclusion, 187*t*, 188
Divergent, 164
Dorsal lingual artery, 269, 271*f*
Ducts of Rivinus, 283

E

Ear muscles, 234
Ectoderm, 173
Edge-to-edge bite, 184*t*, 186
Efferent nerves, 251
Embrasures, 197–198, 197*f*
Enamel, 31, 32*f*, 34*f*, 297*t*, 298*t*
Endoderm, 173
End-to-end bite, 184*t*, 186
Epithelial attachment, 34*f*
Eruption, 175*f*, 176–177
  active, 8, 176–177
  passive, 8, 177
  of primary dentition, 164
Eruption sequence, 6–8, 7*t*
Ethmoid bone, 207*f*, 210*f*, 211, 213*f*
Exfoliation, 3, 7*t*, 164
External auditory meatus, 207*f*, 210
External carotid arteries, 268, 268*f*, 269–275, 270*f*, 271*f*, 273*f*, 275*f*
External jugular vein, 277*f*
External nasal nerve, 255
External oblique line, 216
Extrinsic tongue muscles, 232–233

F

Facial artery, 269–270, 270*f*, 271*f*
Facial expression muscles, 233–238
Facial nerve, 261–262, 262*f*
Facial surface, 28, 29*f*
Facial vein, 276, 277*f*
Fauces, 18, 19*f*, 20
FDI. *See* Federation Dentaire Internationale (FDI)
Federation Dentaire Internationale (FDI), 46, 46*t*, 47*f*
Filiform papilla, 20, 21*f*, 22*t*
First mandibular molars
  buccal surface of, 140, 141*f*, 142, 144
  characteristics of, 139–140
  clinical considerations, 143
  distal surface of, 141*f*, 142, 142*f*, 145
  lingual surface of, 141*f*, 142, 142*f*, 144
  mesial surface of, 141*f*, 142, 142*f*, 144–145
  occlusal surface of, 141*f*, 142, 143*f*, 145
  in primary dentition, 167, 168*f*
  second *vs.*, 146
First mandibular premolars
  buccal surface of, 111*f*, 112, 112*f*, 113–114
  characteristics of, 110–111
  clinical considerations, 113
  distal surface of, 111*f*, 112, 112*f*, 114
  lingual surface of, 111*f*, 112, 112*f*, 114
  mesial surface of, 111*f*, 112, 112*f*, 114
  occlusal view of, 111*f*, 112, 113*f*, 114
First maxillary molars
  buccal surface of, 124, 125*f*, 126, 128–129
  characteristics of, 123–124
  clinical considerations, 128
  distal surface of, 125*f*, 126–127, 126*f*, 130
  lingual surface of, 125*f*, 126, 126*f*, 129
  mesial surface of, 125*f*, 126, 126*f*, 129
  occlusal surface of, 125*f*, 127, 127*f*, 130
  overview of, 123
  second *vs.*, 131
First maxillary premolars
  buccal surface of, 99, 100*f*, 102–103
  characteristics of, 98–99
  clinical considerations, 102
  distal surface of, 100*f*, 101, 101*f*
  lingual surface of, 100*f*, 101, 101*f*, 103
  mesial surface of, 100*f*, 101, 101*f*
  occlusal surface of, 100*f*, 102, 102*f*, 103
Flared, 164
Foliate papilla, 20, 21*f*, 22*t*
Foramen, 206
Foramen caecum, 20, 21*f*
Foramen lacerum, 208*f*, 211*f*, 212
Foramen magnum, 206, 208*f*
Foramen ovale, 208*f*, 209*f*, 211*f*, 212
Foramen rotundum, 209*f*, 212, 212*f*
Foramen spinosum, 208*f*, 211*f*, 212
Foramina of scarpa, 215*f*
Fordyce granules, 17, 19*f*
Fornix, 14*t*
Fovea palatinus, 18, 19*f*
Free gingiva, 36–37, 36*f*, 37*f*
Free gingival junction, 37
Frenum, 14*t*
Frontal bone, 206, 207*f*, 210*f*
Frontal eminence, 207
Frontal nerve, 253
Frontal sinus, 213*f*
Frontalis, 233, 234*f*

Functional malocclusion, 189
Fungiform papilla, 20, 21*f*, 22*t*

G

Genial tubercles, 217, 217*f*
Genioglossus, 232–233, 233*f*
Geniohyoid, 229*f*, 230
Gingiva, 16, 17*f*, 34*f*, 35–38, 36*f*, 37*f*
Gingival crest, 34*f*
Gingival groove, 34*f*
Gingival junction, 36*f*
Gingival sulcus, 34*f*, 36, 37*f*
Glabella, 207
Glenoid fossa, 210, 289*f*
Glossopharyngeal muscle, 20
Glossopharyngeal nerve, 263
Greater palatine artery, 275, 276*f*
Greater palatine foramen, 214, 215*f*
Greater palatine nerve, 256*f*, 257, 260*t*
Greater petrosal nerve, 261

H

Hard palate, 18, 19*f*
Heart, 268*f*
Heart shaped, 158
Heterodonts, 5
Histodifferentiation, 174–175, 175*f*
Hyoglossus, 231*f*, 233, 233*f*
Hyoid bone, 217, 218*f*
Hypoglossal canals, 206, 209*f*
Hypoglossal nerve, 263

I

Ideal occlusion, 182, 182*f*
Identification systems, tooth, 43–47
Incisal edge, 29, 29*f*
Incisal view
  of central mandibular incisors, 70*f*, 71, 72
  of lateral mandibular incisors, 71*f*, 75
Incisive foramen, 215, 215*f*
Incisive nerve, 258*f*, 260, 260*t*
Incisive papilla, 18, 19*f*
Incisors
  central mandibular
    characteristics of, 68–69
    clinical considerations, 71
    description of, 68–72
    incisal view of, 70*f*, 71, 72
    labial surface of, 69, 70*f*, 72
    lingual surface of, 69, 70*f*, 72
    overview of, 68
    proximal surfaces of, 70*f*, 71, 72
  central maxillary, 57–61, 59*f*
    clinical considerations, 60
    labial surface of, 58, 59*f*, 60
    lingual surface of, 58, 59*f*, 60
    proximal surfaces of, 60, 60*f*, 61
  defined, 5
  in eruption sequence, 7*t*
  lateral mandibular
    characteristics of, 72–73
    incisal view of, 71*f*, 75
    labial surface of, 73, 74*f*, 75
    lingual surface of, 73, 74*f*, 75
    overview of, 68
    proximal surface of, 73, 74*f*, 76
  lateral maxillary, 61–64
    characteristics of, 61
    distal surface of, 62*f*
    labial surface of, 62*f*, 63, 64
    lingual surface of, 62*f*, 63, 64
    mesial surface of, 62*f*
  in primary dentition, 163*f*, 165, 165*f*, 166, 167*f*
Inferior acoustic meatus, 209*f*
Inferior alveolar artery, 270*f*, 272
Inferior alveolar nerve, 258*f*, 259–260, 260*t*
Inferior labial artery, 270, 271*f*
Inferior nasal concha, 207*f*, 213*f*, 214
Inferior orbital fissure, 209, 210*f*
Infrahyoids, 230–232, 231*f*
Infraorbital artery, 270*f*, 274, 275*f*
Infraorbital foramen, 210*f*, 214
Infraorbital nerve, 254–255, 255*f*, 256*f*
Infratrochlear nerve, 254*f*
Infraversion, 186, 186*f*
Initiation, 174, 175*f*
Insertion, 224
Internal carotid arteries, 268, 268*f*, 269, 270*f*
Internal jugular vein, 277, 277*f*
Internal oblique line, 216, 216*f*, 217*f*
International Standards Organization (ISO), 46, 46*t*, 47*f*
Interproximal, 30, 30*f*
Interproximal spaces, 196–197, 196*f*, 197*f*
Intrinsic tongue muscles, 232
ISO. *See* International Standards Organization (ISO)

J

Jugular foramen, 208*f*, 209*f*, 211

K

Keystone, 139

L

Labia, 14*t*
Labial, 14*t*
Labial commissure, 15, 16*f*
Labial frenum, 16, 17*f*, 36*f*
Labial glands, 284
Labial ridge, 83
Labial surface
  of central mandibular incisors, 69, 70*f*, 72
  of central maxillary incisors, 58, 59*f*, 60
  defined, 28, 29*f*
  of lateral mandibular incisors, 73, 74*f*, 75
  of lateral maxillary incisors, 62*f*, 63, 64
  of mandibular canines, 86*f*, 87, 87*f*
  of maxillary canines, 82*f*, 83, 83*f*, 84
Labial tubercle, 15, 16*f*
Labiomental groove, 15, 16*f*
Labioversion, 186
Lacrimal bone, 207*f*, 210*f*, 214
Lambdoidal suture, 207*f*, 208*f*
Lamina dura, 34*f*, 35, 37*f*
Lateral mandibular incisors
  characteristics of, 72–73
  incisal view of, 71*f*, 75
  labial surface of, 73, 74*f*, 75
  lingual surface of, 73, 74*f*, 75
  overview of, 68
  proximal surface of, 73, 74*f*, 76
Lateral maxillary incisors, 61–64
  characteristics of, 61
  distal surface of, 62*f*
  labial surface of, 62*f*, 63, 64
  lingual surface of, 62*f*, 63, 64
  mesial surface of, 62*f*
Lateral nasal artery, 271*f*, 272
Lateral plate, 212, 212*f*
Lateral pterygoid, 225*f*, 227, 227*f*, 228*f*
Lateral pterygoid artery, 274
Lateral pterygoid nerve, 257
Lesser palatine artery, 276*f*
Lesser palatine foramen, 214, 215*f*
Lesser palatine nerve, 256*f*, 257
Levator anguli oris, 236*f*, 237
Levator labii superioris, 236, 236*f*
Levator labii superioris alaeque nasi, 235, 235*f*, 236*f*
Levator veli palatini, 239*f*, 240, 241*f*
Line angle, 30, 30*f*
Linea, 14*t*
Linea alba, 16, 17*f*
Lingual, 14*t*
Lingual artery, 269, 270*f*, 271*f*
Lingual foramen, 217*f*
Lingual fossa, 58, 83
Lingual frenum, 21*f*, 22
Lingual glands, 285
Lingual nerve, 258, 258*f*, 259*f*, 261*t*
Lingual ridge, 83
Lingual surface
  of central mandibular incisors, 69, 70*f*, 72
  of central maxillary incisors, 58, 59*f*, 60

Lingual surface (*continued*)
defined, 29, 29*f*
of first mandibular molars, 141*f*, 142, 142*f*, 144
of first mandibular premolars, 111*f*, 112, 112*f*, 114
of first maxillary molars, 125*f*, 126, 126*f*, 129
of first maxillary premolars, 100*f*, 101, 101*f*, 103
of lateral mandibular incisors, 73, 74*f*, 75
of lateral maxillary incisors, 62*f*, 63, 64
of mandibular canines, 86*f*, 87, 87*f*, 88
of maxillary canines, 82*f*, 83, 83*f*, 84
of second mandibular molars, 147*f*, 148*f*
of second mandibular premolars, 116*f*, 117, 117*f*, 118
of second maxillary molars, 132*f*
of second maxillary premolars, 105*f*
Lingula, 217
Linguoversion, 186, 186*f*

M

Major groove pattern, 102
Malalignment, 184–186
Malar bone, 210*f*
Malocclusion, 183
Mamelons, 58
Mandible, 207*f*, 216–217, 216*f*, 217*f*
Mandibular angle, 216*f*
Mandibular canines
characteristics of, 85
clinical considerations, 87
labial surface if, 86*f*, 87, 87*f*
lingual surface of, 86*f*, 87, 87*f*, 88
in primary dentition, 167, 168*f*
proximal surfaces of, 86*f*, 87, 87*f*, 88
Mandibular cervical lines, 302
Mandibular foramen, 217, 217*f*
Mandibular fossa, 210, 289
Mandibular incisors
central
characteristics of, 68–69
clinical considerations, 71
description of, 68–72
incisal view of, 70*f*, 71, 72
labial surface of, 69, 70*f*, 72
lingual surface of, 69, 70*f*, 72
overview of, 68
proximal surfaces of, 70*f*, 71, 72
lateral
characteristics of, 72–73
incisal view of, 71*f*, 75
labial surface of, 73, 74*f*, 75
lingual surface of, 73, 74*f*, 75
overview of, 68
proximal surface of, 73, 74*f*, 76
in primary dentition, 166, 167*f*
Mandibular molars
buccal surface of, 147*f*, 148*f*
characteristics of, 145–146
distal surface of, 147*f*, 148*f*
first
buccal surface of, 140, 141*f*, 142, 144
characteristics of, 139–140
clinical considerations, 143
distal surface of, 141*f*, 142, 142*f*, 145
lingual surface of, 141*f*, 142, 142*f*, 144
mesial surface of, 141*f*, 142, 142*f*, 144–145
occlusal surface of, 141*f*, 142, 143*f*, 145
in primary dentition, 167, 168*f*
second *vs.*, 146
first *vs.*, 146
lingual surface of, 147*f*, 148*f*
mesial surface of, 147*f*, 148*f*
occlusal surface of, 147*f*, 148*f*
second
buccal surface of, 147*f*, 148*f*
characteristics of, 145–146
distal surface of, 147*f*, 148*f*
lingual surface of, 147*f*, 148*f*
mesial surface of, 147*f*, 148*f*
occlusal surface of, 147*f*, 148*f*
in primary dentition, 167, 168*f*
Mandibular nerve, 252, 257–261, 258*f*, 259*f*
Mandibular notch, 216, 216*f*
Mandibular premolars
first
buccal surface of, 111*f*, 112, 112*f*, 113–114
characteristics of, 110–111
clinical considerations, 113
distal surface of, 111*f*, 112, 112*f*, 114
lingual surface of, 111*f*, 112, 112*f*, 114
mesial surface of, 111*f*, 112, 112*f*, 114
occlusal view of, 111*f*, 112, 113*f*, 114
overview of, 110
Mandibular surface, 29*f*
Mandibular third molars, 154–155, 157*f*
Mandibular tori, 22
Marginal gingiva, 34*f*
Marginal ridges, 58
Masseter, 226–227, 226*f*
Masseteric artery, 274
Masseteric nerve, 257
Mastication, 6, 15, 189, 225–228
Masticatory system, 181
Mastoid process, 207*f*, 210
Maturation stage, 175–176, 175*f*
Maxilla, 207*f*, 210*f*, 214–215, 215*f*
Maxillary artery, 270*f*, 272, 273*f*, 275*f*, 276*f*
Maxillary canines
characteristics of, 81
distal surface of, 82*f*, 83*f*
labial surface of, 82*f*, 83, 83*f*, 84
lingual surface of, 82*f*, 83, 83*f*, 84
mesial surface of, 82*f*, 83*f*
in primary dentition, 166, 166*f*
proximal surface of, 83, 83*f*, 84
Maxillary cervical lines, 302
Maxillary incisors
central, 57–61, 59*f*
clinical considerations, 60
labial surface of, 58, 59*f*, 60
lingual surface of, 58, 59*f*, 60
proximal surfaces of, 60, 60*f*, 61
lateral, 61–64
characteristics of, 61
distal surface of, 62*f*
labial surface of, 62*f*, 63, 64
lingual surface of, 62*f*, 63, 64
mesial surface of, 62*f*
overview of, 57
in primary dentition, 165, 165*f*
Maxillary molars
first
buccal surface of, 124, 125*f*, 126, 128–129
characteristics of, 123–124
clinical considerations, 128
distal surface of, 125*f*, 126–127, 126*f*, 130
lingual surface of, 125*f*, 126, 126*f*, 129
mesial surface of, 125*f*, 126, 126*f*, 129
occlusal surface of, 125*f*, 127, 127*f*, 130
overview of, 123
second *vs.*, 131
in primary dentition, 166, 166*f*
second
buccal surface of, 132*f*
characteristics of, 130–131
distal surface of, 132*f*
first *vs.*, 131
lingual surface of, 132*f*
mesial surface of, 132*f*
occlusal surface of, 132*f*, 133, 133*f*
overview of, 123
in primary dentition, 166, 167*f*
Maxillary nerve, 252, 253–257, 256*f*, 259*f*
Maxillary premolars
first
buccal surface of, 99, 100*f*, 102–103
characteristics of, 98–99
clinical considerations, 102
distal surface of, 100*f*, 101, 101*f*
lingual surface of, 100*f*, 101, 101*f*, 103
mesial surface of, 100*f*, 101, 101*f*
occlusal surface of, 100*f*, 102, 102*f*, 103
overview of, 98
second
buccal surface of, 105*f*
characteristics of, 104

clinical considerations, 106
distal surface of, 105*f*
lingual surface of, 105*f*
mesial surface of, 105*f*
occlusal surface of, 105*f*, 106*f*
Maxillary sinus, 215
Maxillary surface, 29*f*
Maxillary third molars, 153–154, 156*f*
Maxillary tuberosity, 16, 17*f*, 215, 215*f*
Maxillary vein, 277*f*
Measurements, 301*t*
Medial plate, 212, 212*f*, 213*f*
Medial pterygoid, 225*f*, 227, 227*f*, 228*f*
Medial pterygoid artery, 274
Median palatine suture, 215, 215*f*
Median sulcus, 20, 21*f*
Melanin, 38
Mental, 14*t*
Mental artery, 274
Mental foramen, 207*f*, 216, 216*f*
Mental nerve, 258*f*, 260, 260*t*
Mental protuberance, 216, 216*f*
Mentalis, 236*f*, 238
Mesial concavity, 101
Mesial interradicular groove, 101
Mesial surface
defined, 28, 29*f*
of first mandibular molars, 141*f*, 142, 142*f*, 144–145
of first mandibular premolars, 111*f*, 112, 112*f*, 114
of first maxillary molars, 125*f*, 126, 126*f*, 129
of first maxillary premolars, 100*f*, 101, 101*f*
of lateral maxillary incisors, 62*f*
of maxillary canines, 82*f*, 83*f*
of second mandibular molars, 147*f*, 148*f*
of second mandibular premolars, 116*f*, 117, 117*f*, 119
of second maxillary molars, 132*f*
of second maxillary premolars, 105*f*
Mesiocclusion, 188–189, 188*t*
Mesiolingual groove, 112
Mesoderm, 173
Mesognathic, 189
Middle meningeal artery, 273*f*, 274, 276*f*
Middle nasal concha, 213*f*
Middle superior alveolar artery, 270*f*, 275*f*
Middle superior alveolar (MSA) nerve, 254, 256*f*, 260*t*
Missing teeth, 189
Mixed dentition, 4, 164
Modiolus, 237*f*
Molars
defined, 6
in eruption sequence, 7*t*
first mandibular
buccal surface of, 140, 141*f*, 142, 144
characteristics of, 139–140
clinical considerations, 143
distal surface of, 141*f*, 142, 142*f*, 145
lingual surface of, 141*f*, 142, 142*f*, 144
mesial surface of, 141*f*, 142, 142*f*, 144–145
occlusal surface of, 141*f*, 142, 143*f*, 145
in primary dentition, 167, 168*f*
second *vs.*, 146
first maxillary
buccal surface of, 124, 125*f*, 126, 128–129
characteristics of, 123–124
clinical considerations, 128
distal surface of, 125*f*, 126–127, 126*f*, 130
lingual surface of, 125*f*, 126, 126*f*, 129
mesial surface of, 125*f*, 126, 126*f*, 129
occlusal surface of, 125*f*, 127, 127*f*, 130
overview of, 123
second *vs.*, 131
in primary dentition, 163*f*, 166, 166*f*, 167*f*
second mandibular
buccal surface of, 147*f*, 148*f*
characteristics of, 145–146
distal surface of, 147*f*, 148*f*
first *vs.*, 146
lingual surface of, 147*f*, 148*f*
mesial surface of, 147*f*, 148*f*
occlusal surface of, 147*f*, 148*f*
in primary dentition, 167, 168*f*
second maxillary
buccal surface of, 132*f*
characteristics of, 130–131
distal surface of, 132*f*
first *vs.*, 131
lingual surface of, 132*f*
mesial surface of, 132*f*
occlusal surface of, 132*f*, 133, 133*f*
overview of, 123
third
mandibular, 154–155, 157*f*
maxillary, 153–154, 156*f*
Morphodifferentiation, 174–175, 175*f*
Motor nerves, 251
MSA. *See* Middle superior alveolar (MSA) nerve
Mucogingival junction, 34*f*, 36*f*, 37
Mucosa
alveolar, 36*f*, 37
buccal, 15
labial, 15
lining, 15
masticatory, 14
oral, 14
specialized, 14
Mucous, 283
Muscles
of facial expression, 233–238
of mastication, 225–228
of neck, 238–240
of pharynx, 242–243
of soft palate, 240–241
of tongue, 232–233, 233*f*
Myelin sheath, 250*f*
Mylohyoid, 228, 229*f*, 230*f*, 231*f*
Mylohyoid groove, 217, 217*f*
Mylohyoid nerve, 258*f*

N

Nasal, 14*t*
Nasal bone, 207*f*, 214
Nasal conchae, 207*f*, 213*f*
Nasal nerve, 256*f*
Naso, 14*t*
Nasociliary nerve, 253
Nasolabial groove, 15, 16*f*
Nasopalatine artery, 275
Nasopalatine foramen, 215, 215*f*
Nasopalatine nerve, 256*f*, 257, 260*t*
Nasopharynx, 239*f*
Neck muscles, 238–240
Nervous system
autonomic, 251
central, 249
parasympathetic, 251
peripheral, 249
sympathetic, 251
Neurocranium, 206–212
Neuron, 250, 250*f*
Neutrocclusion, 187, 187*t*
Node of Ranvier, 250*f*
Nonfunctioning cusp, 112
Normal occlusion, 183
Nose muscles, 235

O

Oblique ridge, 127
Occipital artery, 272
Occipital bone, 206, 207*f*
Occipitalis, 233, 234*f*
Occipitofrontalis, 233, 234*f*
Occlusal deviations, 184–186
Occlusal surface
defined, 29, 29*f*
of first mandibular molars, 141*f*, 142, 143*f*, 145
of first mandibular premolars, 111*f*, 112, 113*f*, 114
of first maxillary molars, 125*f*, 127, 127*f*, 130
of first maxillary premolars, 100*f*, 102, 102*f*, 103
of second mandibular molars, 147*f*, 148*f*
of second mandibular premolars, 116*f*, 117, 118*f*, 119
of second maxillary molars, 132*f*, 133, 133*f*
of second maxillary premolars, 105*f*, 106*f*

Occlusion
defined, 181
ideal, 182, 182*f*
mastication and, 181
normal, 183
of primary teeth, 190–191
Oculomotor nerve, 252*t*
Olfactory nerve, 252*t*, 256*f*
Omohyoid, 230*f*, 231, 231*f*
Openbite, 184, 185*t*
Ophthalmic nerve, 252, 253
Optic canal, 209*f*
Optic foramen, 209, 210*f*
Optic nerve, 252*t*
Oral, 14*t*
Oral cavity
defined, 14
divisions, 15
functions of, 15
structures external to, 15, 16*f*
structures of, 18–20, 19*f*
terminology, 13, 13*t*, 14*t*
Oral mucosa, 14
Oral vestibule, 36*f*
defined, 15
structures of, 16–17, 17*f*
Orbicularis oculi, 234
Orbicularis oris, 235, 236*f*
Orbit bones, 209, 210*f*
Orbital, 235*f*
Origin, 224
Oropharynx, 20
Overbite, 185, 185*t*
Overjet, 185, 185*t*

P

Palate, 18, 19*f*
Palatine bones, 214, 215*f*
Palatine foramen, 214
Palatine glands, 284
Palatine process, 215*f*
Palatine raphe, 18, 19*f*
Palatine rugae, 18, 19*f*
Palatine tonsils, 19*f*, 20
Palatine torus, 18
Palatoglossus, 233*f*, 239*f*, 240
Palatopharyngeal muscle, 20, 239*f*, 240, 241*f*
Palmer's Notation, 44–45, 45*f*
Palpebral muscle, 235*f*
Palpebral nerve, 255
Parasympathetic nervous system, 251
Parietal bone, 207*f*, 210
Parietal eminence, 208*f*
Parotid gland, 282, 284*f*
Parotid papilla, 16, 17*f*, 282, 284*f*
Passive eruption, 8, 177
Periodontal ligament, 34*f*, 35
Periodontium, 34–38
Peripheral nervous system (PNS), 249
Permanent dentition, 3–4, 4*f*, 298*t*, 299*t*
Pharyngeal artery, 275*f*
Pharyngeal nerve, 257
Pharyngeal plexus, 263
Pharynx, 242–243
Philtrum, 15, 16*f*
Platysma, 236*f*, 238, 239*f*
Plica, 14*t*
PNS. *See* Peripheral nervous system (PNS)
Point angle, 30, 30*f*
Polyphyodonts, 4
Posterior auricular artery, 272
Posterior auricular muscle, 234
Posterior auricular nerve, 261
Posterior auricular vein, 277*f*
Posterior deep temporal artery, 274
Posterior retromandibular vein, 277*f*
Posterior superior alveolar artery, 270*f*, 274, 275*f*
Posterior superior alveolar (PSA) nerve, 255, 256*f*, 260*t*
Posterior superior lateral nasal nerve, 257
Posterior tonsillar pillar, 17, 19*f*
Premolars
defined, 5
in eruption sequence, 7*t*
first mandibular
buccal surface of, 111*f*, 112, 112*f*, 113–114
characteristics of, 110–111
clinical considerations, 113
distal surface of, 111*f*, 112, 112*f*, 114
lingual surface of, 111*f*, 112, 112*f*, 114
mesial surface of, 111*f*, 112, 112*f*, 114
occlusal view of, 111*f*, 112, 113*f*, 114
first maxillary
buccal surface of, 99, 100*f*, 102–103
characteristics of, 98–99
clinical considerations, 102
distal surface of, 100*f*, 101, 101*f*
lingual surface of, 100*f*, 101, 101*f*, 103
mesial surface of, 100*f*, 101, 101*f*
occlusal surface of, 100*f*, 102, 102*f*, 103
second maxillary
buccal surface of, 105*f*
characteristics of, 104
clinical considerations, 106
distal surface of, 105*f*
lingual surface of, 105*f*
mesial surface of, 105*f*
occlusal surface of, 105*f*, 106*f*
Primary dentition, 3, 4*f*, 163–169, 190–191, 297*t*, 299*t*
Primate spacing, 164
Procerus, 234, 235*f*
Prognathic, 189
Proliferation, 174
Proximal contact areas, 195–196, 196*f*
Proximal surface
of central mandibular incisors, 70*f*, 71, 72
of central maxillary incisors, 60, 60*f*, 61
defined, 29, 29*f*
of lateral mandibular incisors, 73, 74*f*, 76
of mandibular canines, 86*f*, 87, 87*f*, 88
of maxillary canines, 83, 83*f*, 84
PSA. *See* Posterior superior alveolar (PSA) nerve
Pterygoid canal artery, 275*f*
Pterygoid fossa, 211*f*, 212, 212*f*
Pterygoid fovea, 216
Pterygoid hamulus, 212, 212*f*, 215*f*
Pterygoid plexus of veins, 277, 277*f*
Pterygoid process, 212
Pterygopalatine ganglion, 256*f*, 259*f*
Pterygopalatine nerves, 255, 256*f*
Pulp, 32*f*, 33
Pulp canal, 32*f*, 33, 123
Pulp cavity, 32*f*, 33
Pulp chamber, 32*f*, 33
Pulp horns, 32*f*, 33

Q

Quadrator labii inferioris, 236, 236*f*, 238

R

Ramus, 216*f*
Raphe, 14*t*
Retrodiscal pad, 290
Retrognathic, 189
Retromolar area, 16, 17*f*, 216*f*
Retromolar fossa, 217
Risorius, 236*f*, 238
Roof of the mouth, 18, 19*f*
Root, 27, 28*f*
in primary teeth, 164
Root trunk, 98

S

Sagittal suture, 208*f*
Salivary glands, 282–285
Salpingopharyngeal muscle, 242
Scalp muscles, 233, 234*f*
Second mandibular molars
buccal surface of, 147*f*, 148*f*
characteristics of, 145–146
distal surface of, 147*f*, 148*f*
first *vs.*, 146
lingual surface of, 147*f*, 148*f*
mesial surface of, 147*f*, 148*f*
occlusal surface of, 147*f*, 148*f*
in primary dentition, 167, 168*f*

Second mandibular premolars
buccal surface of, 116*f*, 117, 117*f*, 118
characteristics of, 115
clinical considerations, 118
distal surface of, 116*f*, 117, 117*f*, 119
lingual surface of, 116*f*, 117, 117*f*, 118
mesial surface of, 116*f*, 117, 117*f*, 119
occlusal surface of, 116*f*, 117, 118*f*, 119
Second maxillary molars
buccal surface of, 132*f*
characteristics of, 130–131
distal surface of, 132*f*
first *vs.*, 131
lingual surface of, 132*f*
mesial surface of, 132*f*
occlusal surface of, 132*f*, 133, 133*f*
overview of, 123
in primary dentition, 166, 167*f*
Second maxillary premolars
buccal surface of, 105*f*
characteristics of, 104
clinical considerations, 106
distal surface of, 105*f*
lingual surface of, 105*f*
mesial surface of, 105*f*
occlusal surface of, 105*f*, 106*f*
Sella turcica, 212, 212*f*, 213*f*
Sensory nerves, 251
Serous, 282
Skull, 207*f*
Soft palate, 18, 19*f*, 240–241
Somatic nerves, 251
Sphenoid bone, 207*f*, 210*f*, 212
Sphenoid sinus, 213*f*
Sphenopalatine artery, 275, 275*f*, 276*f*
Spinal accessory nerve, 252*t*
Stapedius muscle nerve, 261
Stensen's duct, 282
Stensen's papilla, 16, 17*f*
Sternocleidomastoid, 231*f*, 239*f*, 240
Sternohyoid, 230*f*, 231, 231*f*
Sternothyroid, 230*f*, 231, 231*f*
Stomodeum, 173
Styloglossus, 233, 233*f*
Stylohyoid, 230, 230*f*, 231*f*
Stylohyoid nerve, 261
Styloid, 229*f*
Styloid process, 207*f*, 208*f*
Stylomastoid foramen, 208*f*, 211
Stylopharyngeal muscle, 241*f*, 242
Stylopharyngeal nerve, 263
Sub, 14*t*
Subclavian artery, 268*f*, 270*f*
Sublingual artery, 269, 271*f*
Sublingual caruncles, 21*f*, 22
Sublingual folds, 21*f*, 22
Sublingual fossa, 217*f*
Sublingual gland, 283, 283*f*, 284*f*
Subluxation, 292
Submandibular caruncles, 284*f*
Submandibular duct, 284*f*
Submandibular fossa, 216*f*, 217, 217*f*
Submandibular ganglion, 259*f*
Submandibular gland, 282, 283*f*, 284*f*
Submental artery, 270, 271*f*
Succedaneous teeth, 4, 139
Superciliary ridge, 207
Superficial temporal artery, 270*f*, 272
Superficial temporal vein, 276, 277*f*
Superior auricular, 234*f*
Superior labial artery, 270, 271*f*
Superior labial nerve, 255
Superior nasal concha, 213*f*
Superior orbital fissure, 209, 209*f*, 210*f*
Superior thyroid artery, 269, 270*f*
Supernumerary teeth, 177
Supplemental grooves, 158
Suprahyoids, 228–230, 229*f*, 230*f*
Supraorbital foramen, 207
Supratrochlear nerve, 254*f*
Supratrochlear notch, 254*f*
Supraversion, 186, 186*f*
Suture, 206
Swallowing. *See* Deglutition
Sympathetic nervous system, 251
Symphysis, 207*f*
Synovial fluid, 290

T

Taste buds, 20, 21*f*, 22*t*
Teeth
anterior, 6
arrangement of, 6
descriptions of, 6
divisions of, 27–28, 28*f*
eruption sequence of, 6–8, 7*t*
identification systems for, 43–47
measurements of, 301*t*
permanent, 4*f*, 5–6
posterior, 6
primary, 4*f*, 5, 163–169
surfaces of, 28–31, 29*f*–31*f*
tissues of, 31–33, 32*f*
types of, 5
Temporal artery, 270*f*
Temporal bone, 207*f*, 210–211
Temporalis, 225–226, 225*f*
Temporomandibular joint (TMJ)
anatomy, 289–290, 289*f*, 290*f*
blood supply, 291
clinical considerations, 291
defined, 289
disorder, 292
internal derangement of, 291
movement of, 290*f*, 291–292, 292*f*
nerve supply, 291
Tensor veli palatini, 239*f*, 241, 241*f*
Terminal plane, 190*f*, 191
Terminology, oral cavity, 13, 13*t*, 14*t*
Third molars
as anomalies, 153
mandibular, 154–155, 157*f*
maxillary, 153–154, 156*f*
overview of, 153
Thyrohyoid, 230*f*, 231*f*, 232
Tongue, 20–22, 21*f*, 232–233, 233*f*
Tonsillar pillars, 17, 19*f*
Torsoversion, 186, 186*f*
Transverse palatine suture, 215, 215*f*
Transverse ridge, 112
Trapezius, 231*f*, 238, 239*f*
Triangular fossa, 102
Triangular ridge, 102
Triangularis, 236*f*, 238
Trifurcation, 123
Trigeminal ganglion, 256*f*
Trigeminal nerve, 251–261, 253*f*, 256*f*
Trochlear nerve, 252*t*
Tubercle, 123
Tympanic nerve, 263

U

Underjet, 185*t*, 186
Universal Tooth Identification System, 43–44, 43*f*, 44*f*
Uvula, 18, 19*f*, 239*f*, 240

V

Vagus nerve, 252*t*
Veins, 275–276
Vermilion zone, 15, 16*f*
Vertebral artery, 268*f*, 270*f*
Vestibule, 36*f*
Vestibule fornix, 36*f*
Visceral nerves, 251
Viscerocranium, 213–214
Vomer bone, 207*f*, 213, 213*f*

W

Wharton's duct, 282, 283*f*

Z

Zygomatic arch, 207*f*
Zygomatic bone, 207*f*, 210*f*
Zygomatic muscle, 236*f*, 237
Zygomatic nerve, 254, 256*f*
Zygomatic process, 210
Zygomaticofacial nerve, 254, 255*f*, 256*f*
Zygomaticotemporal nerve, 254, 255*f*
Zygomaticus major, 236*f*
Zygomaticus minor, 236*f*